

University of Groningen

Hypoxia inducible factor-1-alpha (HIF-1 alpha) is related to both angiogenesis and inflammation in rheumatoid arthritis

Brouwer, E.; Gouw, A. S. H.; Posthumus, M. D.; van Leeuwen, M. A.; Boerboom, Alexander L.; Bijzet, Johannes; Limburg, P. C.; Kallenberg, C. G. M.; Westra, J.; Bos, R

Published in:
Clinical and Experimental Rheumatology

IMPORTANT NOTE: You are advised to consult the publisher's version (publisher's PDF) if you wish to cite from it. Please check the document version below.

Document Version
Publisher's PDF, also known as Version of record

Publication date:
2009

[Link to publication in University of Groningen/UMCG research database](#)

Citation for published version (APA):

Brouwer, E., Gouw, A. S. H., Posthumus, M. D., van Leeuwen, M. A., Boerboom, A. L., Bijzet, J., ... Bos, R. (2009). Hypoxia inducible factor-1-alpha (HIF-1 alpha) is related to both angiogenesis and inflammation in rheumatoid arthritis. *Clinical and Experimental Rheumatology*, 27(6), 945-951.

Copyright

Other than for strictly personal use, it is not permitted to download or to forward/distribute the text or part of it without the consent of the author(s) and/or copyright holder(s), unless the work is under an open content license (like Creative Commons).

Take-down policy

If you believe that this document breaches copyright please contact us providing details, and we will remove access to the work immediately and investigate your claim.

Downloaded from the University of Groningen/UMCG research database (Pure): <http://www.rug.nl/research/portal>. For technical reasons the number of authors shown on this cover page is limited to 10 maximum.

Hypoxia inducible factor-1-alpha (HIF-1 α) is related to both angiogenesis and inflammation in rheumatoid arthritis

E. Brouwer¹, A.S.H. Gouw², M.D. Posthumus¹, M.A. van Leeuwen¹, A.L. Boerboom³, J. Bijzet¹, R. Bos¹, P.C. Limburg⁴, C.G.M. Kallenberg¹, J. Westra¹

¹Department of Rheumatology and Clinical Immunology; ²Pathology and Medical Biology; ³Department of Orthopaedics; ⁴Department of Laboratory Medicine, University Medical Centre Groningen, The Netherlands.

Abstract Objectives

Despite the important role of the transcription factor HIF-1 α in angiogenesis and inflammation, only a few studies on HIF-1 α expression have been performed in RA patients. The aim of the present study was to identify the layer in synovial tissue of RA patients where HIF1 α is expressed and to find out whether HIF-1 α expression is related to both angiogenesis and inflammation in synovium from RA patients.

Methods

A reproducible staining method for HIF-1 α was developed. HIF-1 α -positive cells were quantified in synovial tissue from patients with RA. As control we used synovial tissue from patients with osteoarthritis (OA). The number of HIF-1 α -positive cells was compared with the number of blood vessels present and was correlated with the amount of inflammation. The amount of inflammation was determined by counting inflammatory cells, by estimating the proliferation marker Ki67 in inflamed tissue, and by using a recently published synovitis score which gives an accurate estimate of the amount of inflammation present.

Results

HIF-1 α was expressed weakly in the lining layer and strongly in the sublining layer in RA synovial tissue. In contrast, HIF-1 α was only weakly expressed in OA synovial tissue. The number of HIF-1 α -positive cells correlated strongly with the number of blood vessels in RA synovial tissue and with inflammatory endothelial cell infiltration (blood vessels), cell proliferation (Ki67) and the synovitis score.

Conclusions

HIF-1 α expression is strongest in the sub-lining layer of RA synovium and is related to both angiogenesis and inflammation in synovium from RA patients. These results thus suggest that HIF-1 α could serve as an important new therapeutic target in RA, targeting both angiogenesis and inflammation.

Key words

HIF-1 α , vessels, inflammation, rheumatoid arthritis, osteoarthritis.

Elisabeth Brouwer, MD, PhD
Annette S.H. Gouw, MD, PhD
Marcel D. Posthumus, MD, PhD
Miek A. van Leeuwen, MD, PhD
Alexander L. Boerboom, MD
Johan Bijzet, BsC
Reinhard Bos, MD, PhD
Piet C. Limburg, MD, PhD
Cees G.M. Kallenberg, MD, PhD
Johanna Westra, PhD

Please address correspondence to:

Dr E. Brouwer,

Department of Rheumatology and
Clinical Immunology,

University Medical Center Groningen,
Hanzeplein 1, 9713 GZ Groningen,
The Netherlands

E-mail: e.brouwer@int.umcg.nl

Received on December 23, 2008; accepted
in revised form on June 26, 2009.

© Copyright CLINICAL AND

EXPERIMENTAL RHEUMATOLOGY 2009.

Introduction

Angiogenesis, defined as the development of new capillaries from existing blood vessels, plays a role in the development of synovial inflammation in rheumatoid arthritis (RA) (1-3). Evidence for this role is that levels of one of the most important angiogenic factors, vascular endothelial growth factor A (VEGF-A), along with levels of soluble VEGF-A receptor -1; sFlt-1 (Fms-like tyrosine kinase-1), and angiopoietin-1, correlate with the amount of inflammation and bone destruction in early arthritis (3). The close relation between angiogenesis and inflammation also has been established in animal models of RA. Moreover, in these models, treatment with angiogenesis inhibitors decreases disease activity (4, 5).

A key regulator of angiogenesis is the transcription factor HIF-1, which consists of an inducible part (HIF-1 α) and a constitutive part (HIF-1 β). Under normoxic conditions HIF-1 α is continuously degraded (6, 7). However, hypoxia, oxygen radicals, and various hormones, growth factors and pro-inflammatory cytokines induce stable expression of HIF-1 α , upon which it is dimerised with HIF-1 β and translocates to the nucleus for transcriptional activity (8). Both hypoxia and pro-inflammatory cytokines (like TNF- α and IL1- β) are present in rheumatoid joints (8-13). A recent paper in a collagen induced arthritis animal model very elegantly showed that hypoxia is present in the synovium at the pre-arthritis stage of disease and has a close spatial relationship and a positive severity correlation with synovitis (14). Since both hypoxia and pro-inflammatory cytokines are found in RA stable HIF-1 α expression is expected to be present in RA synovium.

Not only is HIF-1 a key regulator of angiogenesis, it is also a key regulator of inflammation. Fibroblasts from RA synovial tissue, which express HIF-1 α under hypoxic conditions, are capable of secreting large amounts of SDF-1 (15), a chemokine of the CXC family involved in inflammation. In a mouse model of RA conditional knock out of HIF-1 α resulted in almost complete inhibition of the inflammatory response (16, 17). Moreover, myeloid cells lack-

ing HIF-1 α did not induce arthritis in a mouse model for RA (16).

Despite the important role of HIF-1 α in angiogenesis and inflammation, only a few studies on HIF-1 α expression in synovial tissue have been performed *in vivo* in RA patients. The results of these studies are inconclusive. Giatromanolaki *et al.* reported extensive nuclear and cytoplasmic expression of HIF-1 α in both the lining and the sublining layers of synovial tissue (18, 19), whereas Hitchon *et al.* reported that HIF-1 α was present mostly in the lining layer (15). In addition, no studies have explored the relation of HIF-1 α expression to angiogenesis and inflammation in RA patients.

The aims of the present study were to identify the location in synovial tissue of RA patients where HIF-1 α is expressed and to find out whether HIF-1 α expression is related to both angiogenesis and inflammation in synovium from RA patients. First, we developed a reliable staining method for HIF-1 α using carcinoma tissue as a reference tissue. Next, we determined whether the expression of HIF-1 α in RA synovial tissue correlated to both angiogenesis and inflammation. We found that nuclear HIF-1 α is expressed mostly in the sublining layer and that HIF-1 α expression is related to both angiogenesis and inflammation in RA patients.

Materials and methods

Tissue

Synovial tissue was obtained from 8 patients with longstanding RA and 7 patients with OA who underwent synovectomy or joint replacement surgery (Table I). Most RA patients used methotrexate as a disease-modifying anti-rheumatic drug.

Synovial tissue was fixed in formalin and embedded in paraffin. Breast carcinoma and renal carcinoma tissue samples were used as positive controls. Tissue samples were used according to institutional and national ethical guidelines.

HIF-1 α staining on paraffin-embedded tissue

Four different mouse monoclonal antibodies were tested: clone 54 (BD, Becton and Dickinson Company, Bio-

Competing interests: none declared.

Table I. Patient characteristics.

	Age	M/F	Disease duration yrs	DMARD	Synovitis score	RF	ESR	CRP
RA1	62	m	3	MTX/SASP	6	52	8	14
RA2	61	m	16	MTX	7	340	27	24
RA3	58	m	6	MTX	5	495	29	22
RA4	36	m	17	Prednisone	5	1150	24	4
RA5	80	f	3	none	7	48	68	47
RA6	55	f	1	none	2	nd	45	55
RA7	69	f	18	MTX	6	25	8	<3
RA8	43	f	9	MTX,AZA Prednisone, infliximab	6	83	2	10
OA1	25	m	1	none	1	nd	nd	nd
OA2	51	m	10	none	1	nd	nd	18
OA3	61	f	1	prednisone	nd	10	19	35
OA4	58	m	1	none	1	7	22	26
OA5	16	m	2	none	0	nd	7	5
OA6	46	m	2	none	1	nd	nd	<3
OA7	61	m	8	none	2	nd	16	7

RA: rheumatoid arthritis; OA: osteoarthritis; DMARD: disease modifying anti-rheumatic drug; Synovitis score: 0–1, no synovitis, 2–4 low-grade synovitis, 5–9 high-grade synovitis; RF: rheumatoid factor (cut-off value 15); ESR: erythrocyte sedimentation rate; CRP: C-reactive protein.

sciences, Breda, The Netherlands), clone ESEE122 (nr 8366 Abcam, Cambridge, UK), clone HIF-1 α 67 (nr 1 Abcam, Cambridge, UK), and clone HIF-1 α 67 sup (nr 463, Abcam, Cambridge, UK). After synovial tissue was deparaffinised and rehydrated, different antigen retrieval methods were used: different buffers (1 mM EDTA, pH 9; 10 mM citrate, pH 6; and 10 mM Tris + 1 mM EDTA, pH 6) and/or microwave at 700 W for 10 and 20 minutes or water bath at 90°C for 10, 20, 40, 60 and 80 minutes and/or trypsin digestion at 37°C for 30 minutes. Next, endogenous peroxidase activity was blocked in PBS containing 0.3% hydrogen peroxide for 30 minutes. After incubation with the primary antibody for 1 h at room temperature, peroxidase-labelled anti-mouse polymer (EnVision kit, DAKO, Glostrup, Denmark) was used as a second step (1 hour incubation at room temperature). The staining was developed with diaminobenzidine (DAB) chromate substrate for 10 minutes and counterstained with haematoxylin for 30 seconds. Slides were covered with Kaiser's gelatine. A quantitative scoring system of four fields as described by Hashimoto *et al.* (20) was used to quantify HIF-1 α positive cells. Briefly, 4 photographs were taken at random at 200 X magnification and HIF-1 α posi-

tive cells were counted in these fields by 2 independent observers.

HIF-1 α staining on synovial fibroblasts

Fibroblast-like synoviocytes (FLS), isolated from RA synovial tissue, were cultured and stimulated for 4 hours with IL-1 β (10 ng/ml), TNF- α (10 ng/ml) and cobalt chloride (CoCl₂ 0.15 mM) which mimics hypoxia. (13). After stimulation the cells were fixed with ethanol followed by immunohistochemical staining for HIF-1 α with clone HIF-1 α 67 sup (nr 463, Abcam, Cambridge, UK) at a dilution of 1:100.

Vascular markers

As vascular markers we used anti-CD31 antibody (clone JC70A, mouse monoclonal, Dako Cytomation Glostrup, Denmark) diluted 1:20 and anti-CD34 antibody (clone Qbend10 mouse monoclonal, Immunotech France) diluted 1:25 (21, 22). After deparaffinisation and rehydration, we incubated the sections with Tris-EDTA buffer for antigen retrieval. The slides were incubated with the primary antibody for 1 hour at room temperature. Peroxidase-labelled anti-mouse polymer (EnVision kit, DAKO, Glostrup, Denmark) was used as a second step. The staining was developed as described for HIF-1 α . To assess the

number of positive vessels the quantitative scoring system of four fields was used (20) as described for HIF-1 α .

Cellular markers

Synovial tissue was also stained for three cellular markers: T-cells, CD3 (clone PS1, mouse monoclonal, Monosan, Uden, The Netherlands) diluted 1:25; B-cells, CD20 (clone L26, mouse monoclonal, DakoCytomation, Glostrup, Denmark) diluted 1:200; and macrophages, CD68 (clone PGM-1, mouse monoclonal, DakoCytomation, Glostrup, Denmark) diluted 1:50. The staining method was the same as described for the vascular marker CD31. A semi-quantitative scoring system of 0-3 was used for CD3, CD20 and CD68: 0 = no positive cells present, 1 = a small number of positive cells, 2 = a moderate number of positive cells, 3 = a large number of positive cells.

Proliferation marker

As a proliferation marker we used Ki67 (clone MIB-1, DakoCytomation, Glostrup, Denmark) diluted 1:400. After deparaffinisation, sections were heated at 100°C for 10 minutes. Sections were then incubated with Ki67 for 30 minutes at room temperature, followed by peroxidase-conjugated rabbit-anti-mouse antibody (1/100) and goat-anti-rabbit antibody (1/100) for 30 minutes. The peroxidase staining reaction was developed using DAB. To quantitate Ki67-positive endothelial cells, we used the quantitative scoring system of four fields. The presence of Ki67-positive cells in the subintimal infiltrates was scored by 2 independent observers using the semiquantitative scoring system.

Synovitis score

The synovitis score developed by Krenn *et al.* (25) was used on routine haematoxylin and eosin (H&E)-stained slides to differentiate between RA and OA and to estimate the degree of inflammation. Three synovial membrane features (synovial lining layer, stroma cell density and infiltrate) were ranked. Each feature was defined and ranked on a 4-point scale: none (0), slight (1), moderate (2), strong (3). The values for

the three features were then added and interpreted as follows: 0-1, no synovitis, 2-4 low-grade synovitis, 5-9 high-grade synovitis (23).

Statistical analysis

Data were analysed using Graph Pad Prism Software (San Diego, USA). Student's *t*-test, the Mann-Whitney U-test and Pearson's or Spearman rank test was used as appropriate. *P*-values less than 0.05 were considered significant.

Results

HIF-1 α staining

To detect the specific nuclear staining of HIF-1 α four different antibodies were tested and also different antigen retrieval methods. Carcinoma tissue was used as reference tissue. As can be seen from Figure 1A there was a nuclear staining with antibody clone 54, but only in endothelial cells. Antibodies clone 67 and clone ESEE 122 gave a cytoplasmic staining as shown in Figure 1B and 1C respectively. Only antibody clone 67-sup showed the characteristic nuclear staining pattern of HIF-1 α as previously described (24). Antigen retrieval with Tris-EDTA buffer for 60 min in a water bath gave the best result. In Figure 1D the specific nuclear staining for HIF-1 α is shown in necrotic areas in breast carcinoma tissue.

HIF-1 α staining on synovial fibroblast like synoviocytes (FLS)

The specificity of HIF-1 α 67 supernatant for HIF-1 α was further confirmed by staining on cultured FLS incubated with IL1- β , TNF- α and CoCl₂ (which mimics hypoxia) for 4 hours.

After stimulation with IL1- β and TNF- α FLS showed bright nuclear staining with HIF-1 α 67 supernatant in a 1:100 dilution (figure 2 A and B). Especially incubation with CoCl₂, which gives a chemical stabilization of HIF-1 α , gave a strong positive signal (Fig. 2C). Non-stimulated FLS were negative for HIF-1 α (Fig. 2D).

HIF-1 α staining on RA and OA synovial tissue

RA and OA synovial tissue were stained for HIF-1 α with clone-67 sup in a 1:100 dilution under the condi-

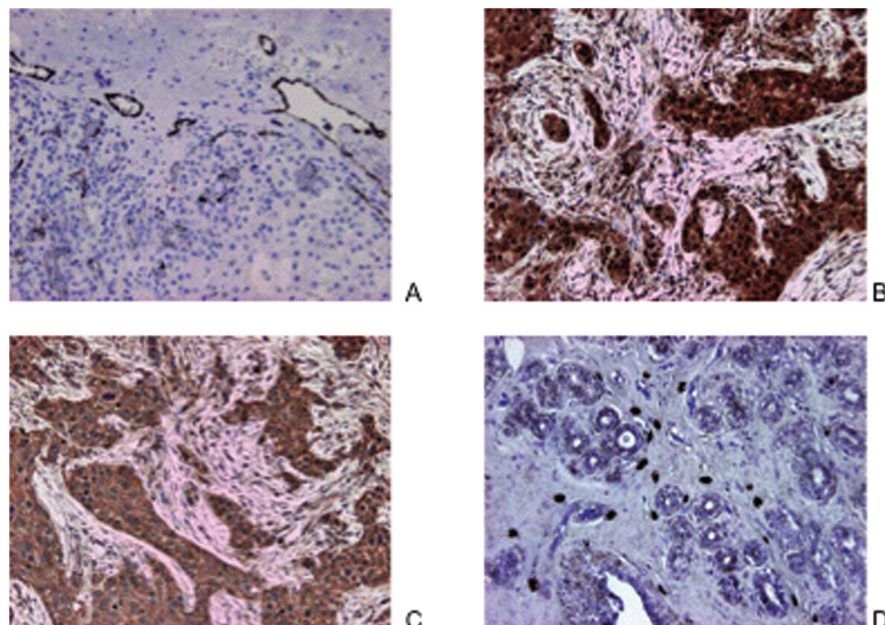


Fig. 1. Expression of hypoxia-inducible factor in carcinoma tissue using different monoclonal antibodies.

To optimise HIF-1 α staining four different monoclonal antibodies directed to HIF-1 α were tested on carcinoma tissue, embedded in paraffin. **Fig. A:** clone 54 showed a predominantly endothelial staining in renal carcinoma tissue; **B:** clone HIF-1 α 67, and **C:** clone ESEE122 gave a cytoplasmic staining in renal carcinoma tissue and **D:** clone HIF-1 α 67-sup gave a nuclear staining in necrotic areas from breast carcinoma. (original magnification 200x)

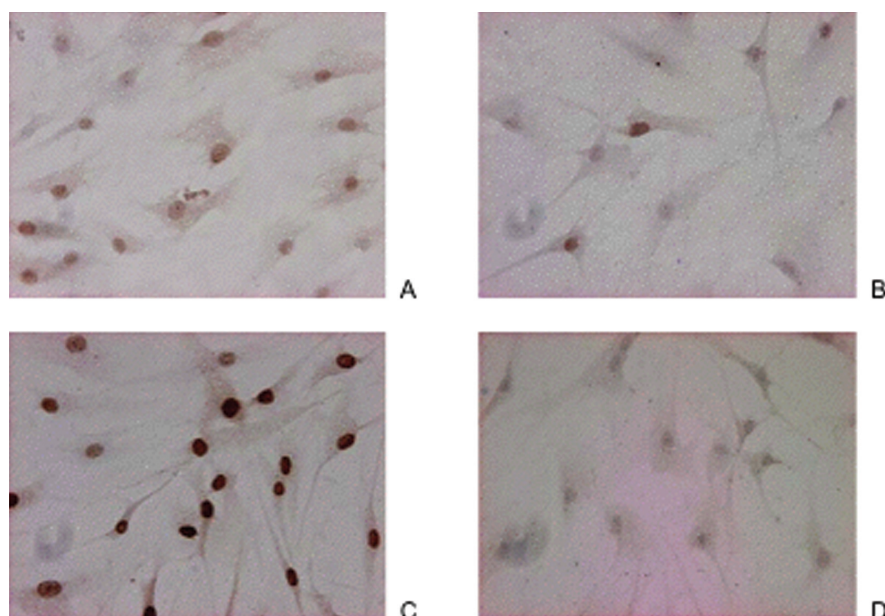


Fig. 2. HIF-1 α staining in cultured rheumatoid synovial fibroblast after stimulation.

Synovial fibroblasts were grown on Labtek slides were stimulated with IL-1 β (A), TNF- α (B), CoCl₂ (C) to induce HIF-1 α expression or left unstimulated (D). Slides were fixed with ethanol and stained with monoclonal antibody HIF-1 α 67-sup.

tions described above. Some HIF-1 α -positive cells were found in the lining layer but most were found in the sub lining layer in RA synovial tissue (Fig. 3A, C and D). Most HIF-1 α -positive cells showed nuclear staining.

A small percentage also showed weak cytoplasmic staining. HIF-1 α -positive cells were present surrounding lymphoid aggregates and vessels and also in less cellular stromal areas (Fig. 3C and D).

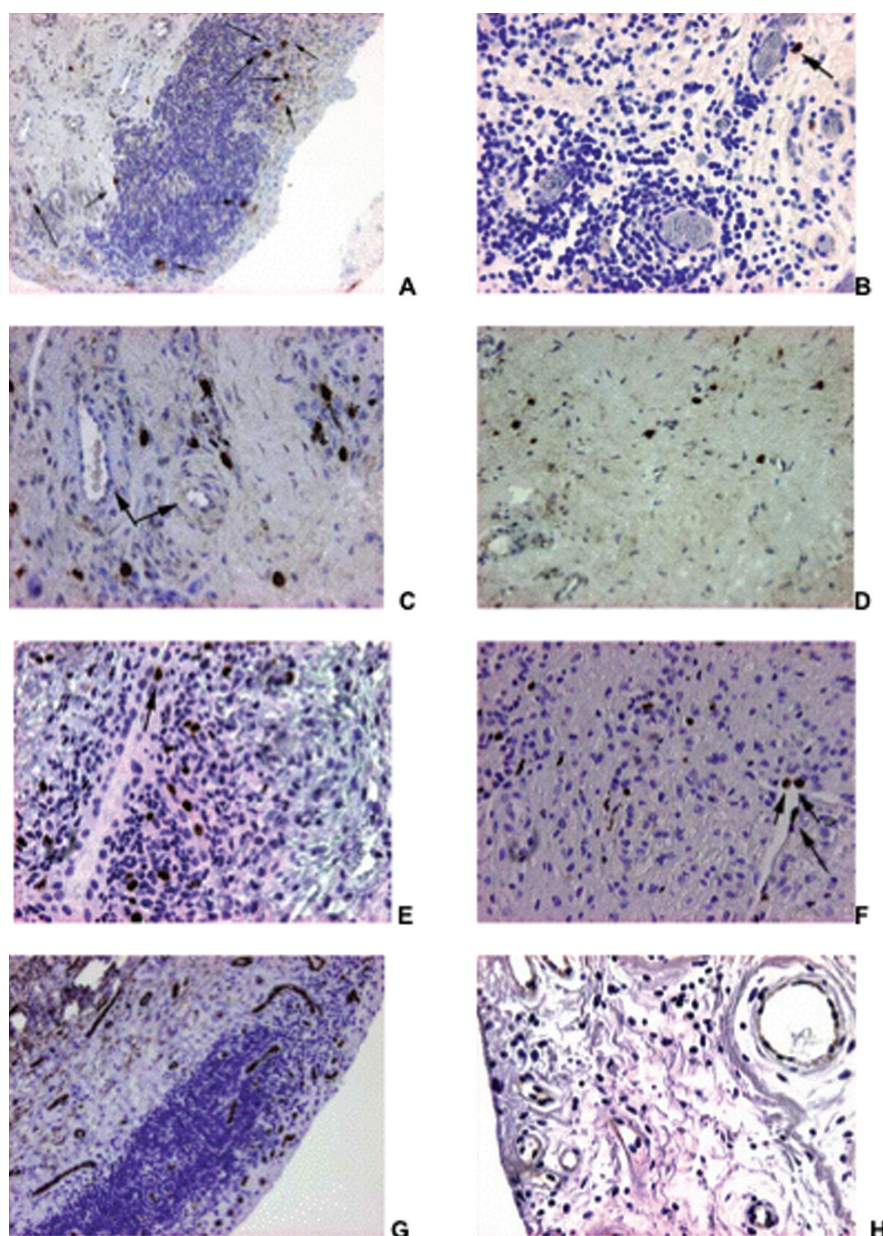


Fig. 3. Expression of HIF-1 α , Ki67 and CD31-positive vessels in RA and OA synovial tissue. Synovial tissue from RA patients (A, C and D) and OA patients (B) were stained for HIF-1 α expression. Arrows indicate HIF-1 α positive cells in a lymphoid aggregate (A), surrounding blood vessels (C) and in a stromal area (D). Positive Ki67 staining in RA (E) and OA (F) synovial tissue, where arrows indicate positive endothelial cells. CD31 positive vessels in RA (G) and OA (H) synovial tissue. (original magnification 200x in A, G and H, 400x in B, C, D, E, and F).

Vascular markers

A strong correlation was found between the number of HIF-1 α -positive cells and the number of CD31-positive vessels (Fig. 3, G and H). In addition, significantly more HIF-1 α -positive cells and CD31-positive vessels were found in RA synovial tissue than in OA synovial tissue (Fig. 4).

Cellular markers

CD3 (T-cells), CD20 (B-cells) and CD68

(macrophages) were used as cellular markers. Abundant infiltration of CD3-, CD20- and CD68-positive cells was found in RA but not in OA synovial tissue. Since CD68-positive macrophages have been used as biomarkers in several RA studies (25-27), we assessed the correlation between CD68-positive macrophages and HIF-1 α -positive cells. We found an association between CD68-positive macrophages and HIF-1 α -positive cells (Spearman $r=0.51$)

and between the number of HIF-1 α - and Ki67-positive endothelial cells (Spearman $r=0.51$).

Synovitis score

In order to investigate the severity of the synovitis we used the recently developed synovitis score by Krenn *et al.* (23) (Table I). The synovitis score was significantly higher in RA patients than in OA patients. Moreover, the synovitis score strongly correlated with the number of HIF-1 α -positive ($r=0.5980$, $p<0.05$) and Ki67-positive cells ($r=0.8430$, $p<0.05$) (Fig. 5A and B).

Proliferation of endothelial cells

To investigate whether vessels proliferated, Ki67-positive endothelial cells were counted in four random fields. No significant difference was found between the numbers of Ki67-positive endothelial cells. Also, within RA patients no correlation was found between the number of CD31-positive vessels and the number of Ki67-positive endothelial cells.

Discussion

In the present study we found that in synovial tissue from RA patients HIF-1 α -positive cells are present mostly in the sub-lining layer and that the expression is restricted mainly to the nucleus. In addition, we found that HIF-1 α expression in synovial tissue from RA patients is related to both angiogenesis and inflammation. Our results for HIF-1 α are in agreement with the results obtained from oncology studies showing that the staining in breast, renal, and colon carcinomas is predominantly nuclear (24, 28). These results would be expected, since HIF-1 α is a transcription factor. Our results are also in line with those by Hitchon *et al.* (15), who detected HIF-1 α primarily in the nuclei of lining cells in areas of synovial tissue where the lining cell layer was hyperplastic. Contradictory studies, in RA and OA showed an abundant presence of HIF-1 α -positive cells both in the lining and in the sub-lining layer (18, 29). Moreover, in those studies the staining was both nuclear and cytoplasmic. The differences with our study probably can be explained by the use of different staining methods and

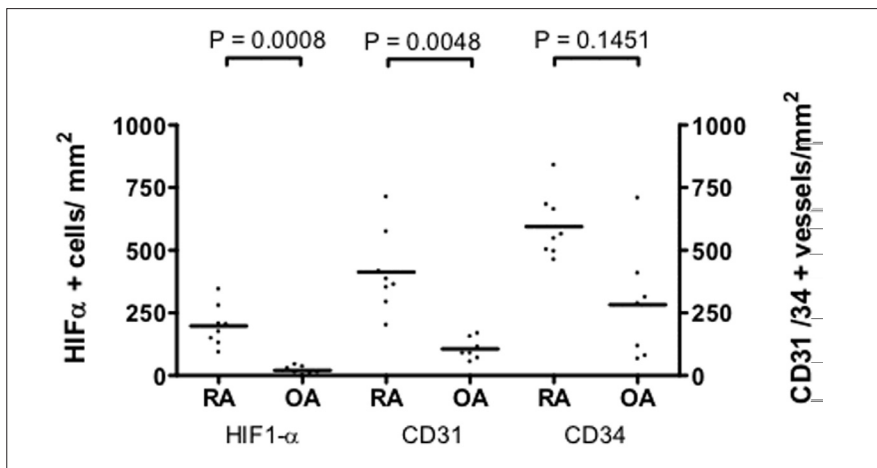


Fig. 4. Scores of HIF-1 α positive cells and CD31 and CD34 positive vessels in 8 RA and 7 OA patients. HIF-1 α positive cells, and CD31 and CD34 positive vessels were scored as described in materials and methods and expressed as number of positive cells or vessels per mm². Significant differences were found between RA and OA for all markers.

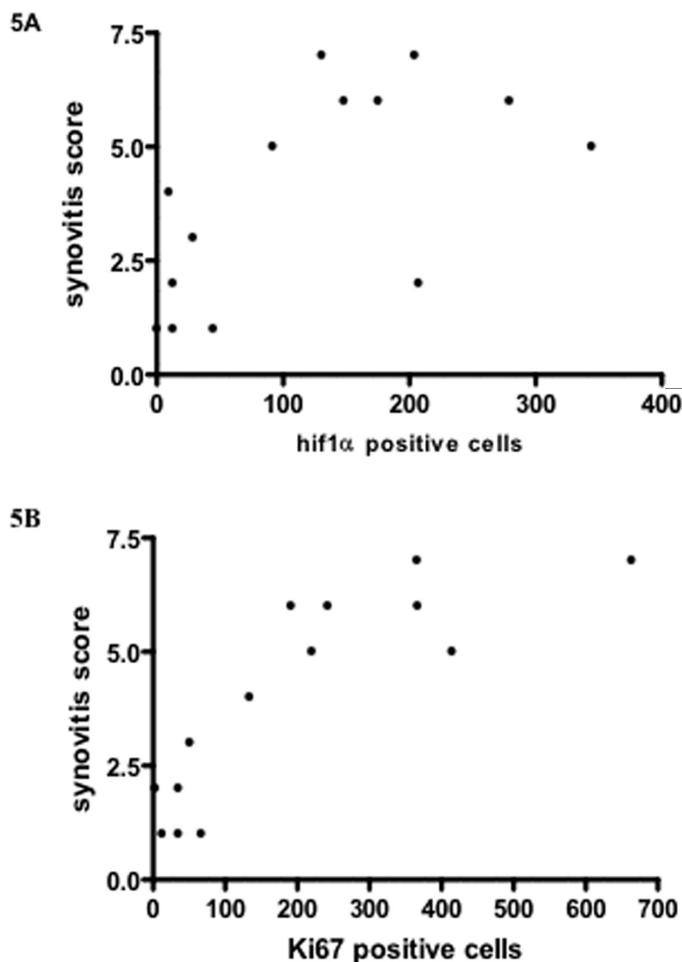


Fig. 5. Correlation of synovitis score with HIF-1 α and Ki67 positive cells in RA and OA. To investigate whether there was a correlation between inflammation and HIF-1 α positivity, and between inflammation and proliferation, the data of RA and OA patients were joined. In Figure (A) a significant correlation is shown between HIF-1 α positive cells and synovitis score ($r=0.5980$, $p<0.05$). In Figure (B) a significant correlation is shown between Ki67 positive cells and synovitis score ($r=0.8439$, $p<0.05$).

different monoclonal antibodies. Giatromanolaki *et al.* (29) used ESEE122 which in our hands gave an aspecific cytoplasmic staining in carcinoma tissue used as reference tissue.

An explanation for the lower expression of HIF-1 α as we found in the lining layer could be that under normoxic conditions HIF-1 α becomes rapidly degraded. In the study by Hitchon *et*

al. the synovial tissue was immediately processed (15). Since the lining layer is the superficial layer, greater exposure to oxygen concentration is expected to affect the lining layer the most. Increases in oxygen concentration are also expected when synovial tissue is removed from the hypoxic joint to normoxic environmental conditions. Conversely, synovial explants and fibroblast-like synoviocytes (present in the lining layer) cultured under hypoxic conditions show an increase in HIF-1 α expression (15). Hypoxia is abundantly present in joints (10) especially in early RA there is a relative shortage of capillaries in relation to the number of infiltrating cells in synovial tissue (30), so oxygen would not be well supplied.

The association we found between HIF-1 α and the number of vessels present suggests that HIF-1 α could be an important inducer of angiogenesis in RA. Since several other studies have shown the importance of angiogenesis for the development of synovial inflammation in RA (2, 31-34), HIF-1 α , as a mediator of angiogenesis, could be an interesting new target for therapy in RA.

Although we found a difference in the number of vessels between RA and OA, we did not find a difference in the number of proliferating Ki67-positive endothelial cells between RA and OA. In a study performed by Walsh *et al.* they also investigated the number of Ki67- positive endothelial cells together with PCNA (proliferating cell nuclear antigen) positive endothelial cells in RA and OA (35). For PCNA they found a significant difference between RA and OA. Unfortunately their results for Ki67 were not mentioned.

The second association we found was between HIF-1 α expression and the number of infiltrating macrophages (CD68 positive) in the sublining layer. This result is in agreement with Hollander *et al.* (18) who found that HIF-1 α expression was most abundant in areas of high macrophage infiltration. In our study HIF-1 α expression not only correlated with the number of macrophages but also with the number of proliferating (as detected with Ki67)

cells. This implicates that, in addition to subintimal macrophages and subintimal Ki-67 expression, which both are synovial tissue biomarkers (25-27, 36), subintimal HIF-1 α expression could also serve as a biomarker for RA. From the present study it can not be concluded whether cytokines produced by myeloid cells induce HIF-1 α or whether HIF-1 α induces myeloid differentiation and activation in response to inflammatory stimuli (16, 17). The recently described adjuvant arthritis model (14) could be useful in investigating whether HIF-1 α expression precedes synovitis and cellular infiltration. Since hypoxia is already present at an early stage of subclinical synovitis, we expect that the same holds true for HIF-1 α expression. Our results suggest that HIF-1 α could be an important mediator of inflammation in RA. This possibility would further support HIF-1 α as a new therapeutic target for RA.

In oncology, an ideal treatment strategy targets both cellular proliferation and angiogenesis (37, 38). We believe that the same holds true for RA: an ideal treatment strategy should target both inflammatory cells and vessel formation. Since HIF-1 α , as shown by our study, is linked to both the number of proliferating cells and the number of vessels present and in RA, HIF-1 α could be an important new therapeutic target in RA.

References

- FEARON U, GRIOSIOS K, FRASER A *et al.*: Angiopoietins, growth factors, and vascular morphology in early arthritis. *J Rheumatol* 2003; 30: 260-8.
- CLAVEL G, VALVASON C, YAMAOKA K *et al.*: Relationship between angiogenesis and inflammation in experimental arthritis. *Eur Cytokine Netw* 2006; 17: 202-10.
- CLAVEL G, BESSIS N, LEMEITER D *et al.*: Angiogenesis markers (VEGF, soluble receptor of VEGF and angiopoietin-1) in very early arthritis and their association with inflammation and joint destruction. *Clin Immunol* 2007; 124: 158-64.
- STORGARD CM, STUPACK DG, JONCZYK A, GOODMAN SL, FOX RI, CHERESH DA: Decreased angiogenesis and arthritic disease in rabbits treated with an alphavbeta3 antagonist. *J Clin Invest* 1999; 103: 47-54.
- HAAS CS, AMIN MA, RUTH JH *et al.*: *In vivo* inhibition of angiogenesis by interleukin-13 gene therapy in a rat model of rheumatoid arthritis. *Arthritis Rheum* 2007; 56: 2535-48.
- SEMENZA G: Signal transduction to hypoxia-inducible factor 1. *Biochem Pharmacol* 2002; 64: 993-8.
- SEMENZA GL: Hypoxia-inducible factor 1 (HIF-1) pathway. *Sci STKE* 2007; 2007: cm8.
- HADDAD JJ, HARB HL: Cytokines and the regulation of hypoxia-inducible factor (HIF)-1 α . *Int Immunopharmacol* 2005; 5: 461-83.
- TAYLOR PC: VEGF and imaging of vessels in rheumatoid arthritis. *Arthritis Res* 2002; 4 (Suppl. 3): S99-107.
- TAYLOR PC, SIVAKUMAR B: Hypoxia and angiogenesis in rheumatoid arthritis. *Curr Opin Rheumatol* 2005; 17: 293-8.
- DISTLER JH, WENGER RH, GASSMANN M *et al.*: Physiologic responses to hypoxia and implications for hypoxia-inducible factors in the pathogenesis of rheumatoid arthritis. *Arthritis Rheum* 2004; 50: 10-23.
- GABER T, DZIURLA R, TRIPMACHER R, BURMESTER GR, BUTTGEREIT F: Hypoxia inducible factor (HIF) in rheumatology: low O2! See what HIF can do! *Ann Rheum Dis* 2005; 64: 971-80.
- WESTRA J, BROUWER E, BOS R *et al.*: Regulation of cytokine-induced HIF-1 α expression in rheumatoid synovial fibroblasts. *Ann N Y Acad Sci* 2007; 1108: 340-8.
- JEON CH, AHN JK, CHAI JY *et al.*: Hypoxia appears at pre-arthritic stage and shows colocalization with early synovial inflammation in collagen induced arthritis. *Clin Exp Rheumatol* 2008; 26: 646-8.
- HITCHON C, WONG K, MA G, REED J, LYTLE D, EL GABALAWY H: Hypoxia-induced production of stromal cell-derived factor 1 (CXCL12) and vascular endothelial growth factor by synovial fibroblasts. *Arthritis Rheum* 2002; 46: 2587-97.
- CRAMER T, YAMANISHI Y, CLAUSEN BE *et al.*: HIF-1 α is essential for myeloid cell-mediated inflammation. *Cell* 2003; 112: 645-57.
- ODA T, HIROTA K, NISHI K *et al.*: Activation of hypoxia-inducible factor 1 during macrophage differentiation. *Am J Physiol Cell Physiol* 2006; 291: C104-C113.
- HOLLANDER AP, CORKE KP, FREEMONT AJ, LEWIS CE: Expression of hypoxia-inducible factor 1 α by macrophages in the rheumatoid synovium: implications for targeting of therapeutic genes to the inflamed joint. *Arthritis Rheum* 2001; 44: 1540-4.
- GIATROMANOLAKI A, ARVANITIDOU V, HATZIMICHAELA, SIMOPOULOS C, SIVRIDIS E: The HIF-2 α /VEGF pathway activation in cutaneous capillary haemangiomas. *Pathology* 2005; 37: 149-51.
- HASHIMOTO A, TARNER IH, BOHLE RM *et al.*: Analysis of vascular gene expression in arthritic synovium by laser-mediated microdissection. *Arthritis Rheum* 2007; 56: 1094-105.
- LE BA, LIONNETON F, MATTOT V *et al.*: HIF-2 α specifically activates the VE-cadherin promoter independently of hypoxia and in synergy with Ets-1 through two essential ETS-binding sites. *Oncogene* 2007.
- KATO K, TAKADA T, FUKUSATO T: Expression of vascular endothelial-cadherin in human hepatocellular carcinoma tissues. *Hepatology Res* 2007; 37: 444-53.
- KRENN V, MORAWIETZ L, BURMESTER GR *et al.*: Synovitis score: discrimination between chronic low-grade and high-grade synovitis. *Histopathology* 2006; 49: 358-64.
- ZHONG H, DE MARZO AM, LAUGHNER E *et al.*: Overexpression of hypoxia-inducible factor 1 α in common human cancers and their metastases. *Cancer Res* 1999; 59: 5830-5.
- BRESNIHAN B, GERLAG DM, ROONEY T *et al.*: Synovial macrophages as a biomarker of response to therapeutic intervention in rheumatoid arthritis: standardization and consistency across centers. *J Rheumatol* 2007; 34: 620-2.
- GERLAG DM, HARINGMAN JJ, SMEETS TJ *et al.*: Effects of oral prednisolone on biomarkers in synovial tissue and clinical improvement in rheumatoid arthritis. *Arthritis Rheum* 2004; 50: 3783-91.
- HARINGMAN JJ, GERLAG DM, ZWINDERMAN AH *et al.*: Synovial tissue macrophages: a sensitive biomarker for response to treatment in patients with rheumatoid arthritis. *Ann Rheum Dis* 2005; 64: 834-8.
- ZHONG H, AGANI F, BACCALA AA *et al.*: Increased expression of hypoxia inducible factor-1 α and -2 α pathway in rheumatoid arthritis and osteoarthritis. *Arthritis Res Ther* 2003; 5: R193-R201.
- GIATROMANOLAKI A, SIVRIDIS E, MALT-EZOS E *et al.*: Upregulated hypoxia inducible factor-1 α and -2 α pathway in rheumatoid arthritis and osteoarthritis. *Arthritis Res Ther* 2003; 5: R193-R201.
- STEVENS CR, BLAKE DR, MERRY P, REVELL PA, LEVICK JR: A comparative study by morphometry of the microvasculature in normal and rheumatoid synovium. *Arthritis Rheum* 1991; 34: 1508-13.
- FRASER A, FEARON U, REECE R, EMERY P, VEALE DJ: Matrix metalloproteinase 9, apoptosis, and vascular morphology in early arthritis. *Arthritis Rheum* 2001; 44: 2024-8.
- KOCH AE: Angiogenesis as a target in rheumatoid arthritis. *Ann Rheum Dis* 2003; 62 (Suppl. 2): ii60-ii67.
- CLAVEL G, BESSIS N, BOISSIER MC: Recent data on the role for angiogenesis in rheumatoid arthritis. *Joint Bone Spine* 2003; 70: 321-6.
- MARUOTTI N, CANTATORE FP, CRIVELLATO E, VACCA A, RIBATTI D: Angiogenesis in rheumatoid arthritis. *Histol Histopathol* 2006; 21: 557-66.
- WALSH DA, WADE M, MAPP PI, BLAKE DR: Focally regulated endothelial proliferation and cell death in human synovium. *Am J Pathol* 1998; 152: 691-702.
- PESSLER F, OGDIE A, AZ-TORNE C *et al.*: Subintimal Ki-67 as a synovial tissue biomarker for inflammatory arthropathies. *Ann Rheum Dis* 2008; 67: 162-7.
- BROWN JM, GIACCIA AJ: Tumour hypoxia: the picture has changed in the 1990s. *Int J Radiat Biol* 1994; 65:95-102.
- CHI JT, WANG Z, NUYTEN DS *et al.*: Gene expression programs in response to hypoxia: cell type specificity and prognostic significance in human cancers. *PLoS Med* 2006; 3:e47.