

Stephen F. Austin State University

SFA ScholarWorks

Faculty Publications

Kinesiology and Health Science

2016


A Technique of Improved Medial Meniscus Visualization by Anterior Cruciate Ligament Graft Placement in Chronic Anterior Cruciate Deficient Knees

Christopher J. Vertullo
Griffith University - Australia

Lahann Wijenayake
Bond University

Jane E. Grayson
Stephen F Austin State University

Follow this and additional works at: <https://scholarworks.sfasu.edu/kinesiology>

 Part of the [Kinesiology Commons](#), [Orthopedics Commons](#), [Rehabilitation and Therapy Commons](#), and the [Surgery Commons](#)

[Tell us](#) how this article helped you.

Repository Citation

Vertullo, Christopher J.; Wijenayake, Lahann; and Grayson, Jane E., "A Technique of Improved Medial Meniscus Visualization by Anterior Cruciate Ligament Graft Placement in Chronic Anterior Cruciate Deficient Knees" (2016). *Faculty Publications*. 20.
<https://scholarworks.sfasu.edu/kinesiology/20>

This Article is brought to you for free and open access by the Kinesiology and Health Science at SFA ScholarWorks. It has been accepted for inclusion in Faculty Publications by an authorized administrator of SFA ScholarWorks. For more information, please contact cdsscholarworks@sfasu.edu.



A Technique of Improved Medial Meniscus Visualization by Anterior Cruciate Ligament Graft Placement in Chronic Anterior Cruciate Deficient Knees

Christopher J. Vertullo, M.B.B.S., F.R.A.C.S., F.A.OrthoA., Lahann Wijenayake, M.B.B.S., and Jane E. Grayson, Ph.D.

Abstract: It is customary to perform medial meniscus repair before anterior cruciate ligament (ACL) graft placement when undertaken as a combined procedure. However, in chronic ACL-deficient knees, intraoperative anterior tibiofemoral translation can cause the medial meniscus repair to be more technically challenging. Intraoperative anterior tibiofemoral translation can both reduce the visualization of the medial meniscus and make its reduction unstable. An operative sequence alteration of ACL graft placement and tensioning before medial meniscal repair improves medial meniscus visualization in chronically ACL-deficient knees by using the ACL graft's ability to prevent anterior tibiofemoral translation. The technique sequence is as follows: (a) the medial meniscus is reduced, (b) ACL reconstruction is undertaken using a hamstring graft without final tibia fixation, (c) distal graft tension is manually applied to distal graft sutures by the surgeon to prevent tibiofemoral subluxation, (d) the medial meniscus is repaired while graft tension is applied, and (e) the graft is then fixed to the tibia using an interference screw or another device.

Rupture of the anterior cruciate ligament (ACL) increases the risk of medial meniscal tears, particularly in the posterior horn¹ with documented rates up to 75%.² Preservation of the medial meniscus decreases osteoarthritis risk, decreases joint contact pressures,³ and reduces anteroposterior tibial translation.² As the ACL is the predominant restraint to anterior tibial translation in the knee, ACL deficiency increases anterior tibial displacement, increasing load on the posterior medial meniscus via medial femoral

condyle impingement⁴ causing increased medial meniscal tear gapping,⁵ and most importantly decreasing medial meniscus visualization.⁶

In patients with chronic ACL-deficient knees, anterior tibial translation is more severe.⁷ As a result, visualization is worsened, and this coupled with meniscal tear gapping and increased load can make repair of the medial meniscus posterior horn tears technically challenging.⁸

Customarily, if the medial meniscus is torn in an ACL-deficient knee, it is repaired first before the ACL is reconstructed, either as a separate procedure⁹ or before simultaneous ACL reconstruction (ACLR).¹⁰⁻¹² This compartmentalized approach separates the key operative components into finite unrelated sequential tasks and does not take advantage of the ACL graft's ability to decrease anterior tibial translation.

We describe an alternative operative technique that takes advantage of the ACL graft's ability to decrease anterior tibial subluxation, aiding in meniscal visualization during subsequent repair of medial meniscal tears in chronically torn ACLs.

Surgical Technique

Positioning and Portals

The patient is positioned supine on the operating table under either a general or spinal anesthetic, with

From Knee Research Australia, Gold Coast, Australia, and the Centre for Musculoskeletal Research, Menzies Health Institute, Griffith University, Gold Coast, Australia; (C.J.V.); the Department of Medicine, Bond University (L.W.), Gold Coast, Australia; and the Department of Kinesiology and Health Science, Stephen F. Austin State University (J.E.G), Nacogdoches, Texas, U.S.A.

The authors report the following potential conflict of interest or source of funding: C.J.V. and J.E.G. receive support from Australian Federal Health Department, Knee Research Australia, Zimmer, and Smith & Nephew.

Received August 12, 2015; accepted January 4, 2016.

Address correspondence to Christopher J. Vertullo, M.B.B.S., F.R.A.C.S., F.A.OrthoA., Orthopaedic Surgery Sports Medicine Center, 8-10 Carrara Street, Benowa, Gold Coast, Queensland 4217, Australia. E-mail: chris.vertullo@icloud.com

© 2016 by the Arthroscopy Association of North America. Open access under CC BY-NC-ND license.

2212-6287/15769

<http://dx.doi.org/10.1016/j.eats.2016.01.001>

tourniquet inflated to 300 mmHg, a curved lateral thigh support (Hipac, NSW, Australia), and 2 popliteal bolsters (Hipac). The two 5-cm-diameter round rubber popliteal bolsters are placed to allow the knee to be in either maximum flexion for femoral tunnel creation or at 90° for tibia tunnel creation. One bolster is placed transversely across the table, under the operative limb, at the level of the opposite knee and attached to the table. The second bolster is placed midway between the knee and the ankle. The operative limb's heel is placed against the distal bolster to flex the knee to 90° (Fig 1) and the proximal bolster to keep the knee flexed at 140° (Fig 2) for later transportal femoral tunnel drilling. The lateral thigh support stops the operative hip falling into abduction during the procedure. After sterile skin preparation and sterile draping with an arthroscopic pouch drape, 2 routine anterior portals are used, with a high anterolateral portal close to the patella tendon for improved lateral femoral wall visualization, and a low anteromedial portal for easier transportal femoral tunnel drilling.

Medial Meniscus Reduction

The knee joint is arthroscopically inspected using a 4-mm 30° Storz arthroscope (Tuttlingen, Germany) in the anterolateral portal. The ACL is confirmed to be incompetent and the joint is inspected using a systematic approach starting with the patellofemoral compartment, and ending in the lateral compartment. If the medial meniscus is confirmed to be torn and displaced, it is reduced using a 3-mm hook probe or similar from the anteromedial portal (Fig 3, Video 1). If the lateral meniscus is torn, it is then repaired or resected as appropriate with the knee in a figure-4 position (Fig 4).

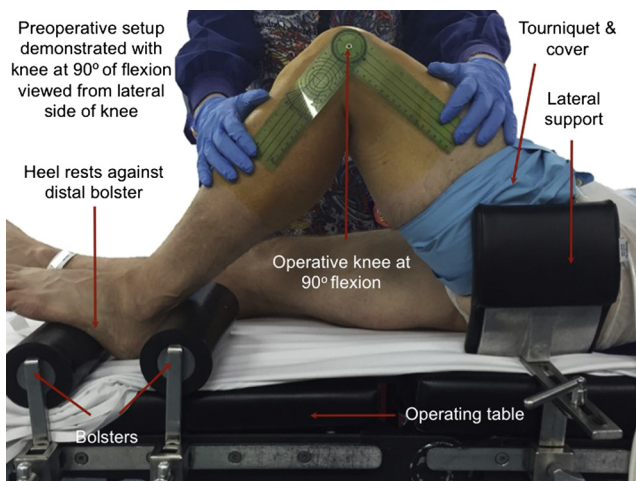


Fig 1. Setup 1: Two foot bolsters and lateral thigh support are shown supporting the knee at 90°. This is the optimum position for tibial tunnel drilling.

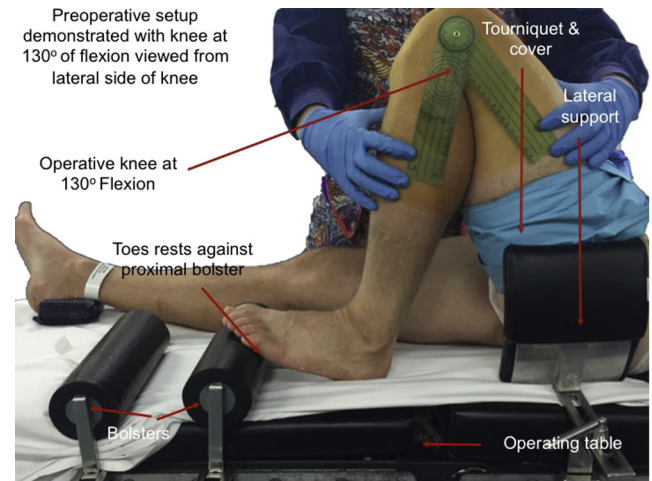

Fig 2. Setup 2: Foot bolsters and lateral thigh support are shown supporting the knee at 135°. This is the optimal position for transportal femoral tunnel drilling.

ACL Graft Insertion Without Distal Fixation

The femoral ACL tunnel site is then selected using the surgeon's (C.J.V.) preference for either anatomic landmarks or a measuring guide or a combination. Next, an initial 4.5-mm-diameter tunnel is fashioned with an Endobutton reamer (Smith & Nephew, Memphis, TN) by drilling over a placed guidewire at the selected tunnel site (Fig 5). The tunnel is measured for length, and an appropriately sized closed loop Endobutton is selected. The gracilis (GC) and semitendinosus (ST) tendons are then harvested using a Linvatec closed tendon harvester (Conmed, Largo, FL) via an anteromedial tibial vertical incision. Two 50 Ethibond

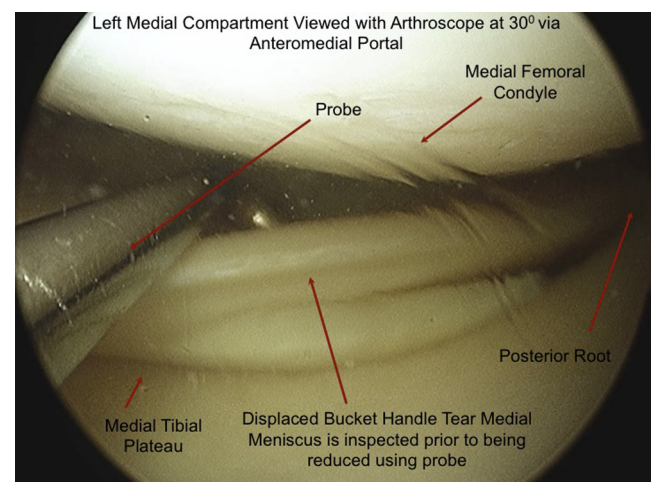


Fig 3. Step 1: The bucket handle medial meniscal tear is reduced but not repaired. If not a locked bucket handle tear, the medial meniscus is inspected but not repaired. This is a left displaced medial meniscal tear viewed from the anterolateral portal with the arthroscope at 3 o'clock. The probe is inserted via the anteromedial portal.

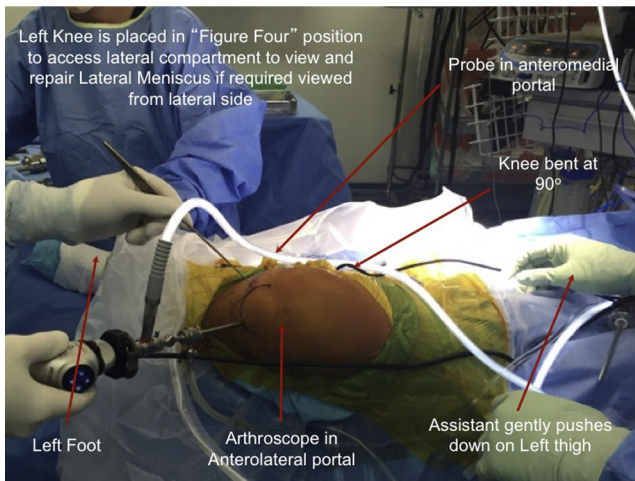


Fig 4. Step 2: A systematic joint inspection is undertaken and lateral meniscal repair is performed in the “figure 4” position as required.

sutures (Ethicon, Johnson & Johnson, Somerville, NJ) are attached using a “baseball stitch” to the divided proximal and distal GC and ST tendon ends to allow later tensioning (Fig 6). The GC and ST are then doubled over into a 4-strand hamstring autograft (HS) using an appropriate length Endobutton CL (Smith & Nephew) (Fig 7). The prepared graft diameter is then measured and recorded. After this, the appropriately sized femoral and tibial tunnels are fashioned. The HS graft is then fully drawn into the femoral tunnel via the tibial tunnel by tension on the Endobutton sutures, and the Endobutton CL is flipped, securing it to the femur (Fig 8). Once the Endobutton CL is flipped on the femoral tunnel exterior cortex, tension is applied manually to the nonattached distal ends of the HS graft by the surgeon using an artery forcep (Crile GS3106, Kaiser, Germany) that grasps the Ethibond 50 sutures (Fig 9). The required tension is dependent on the force

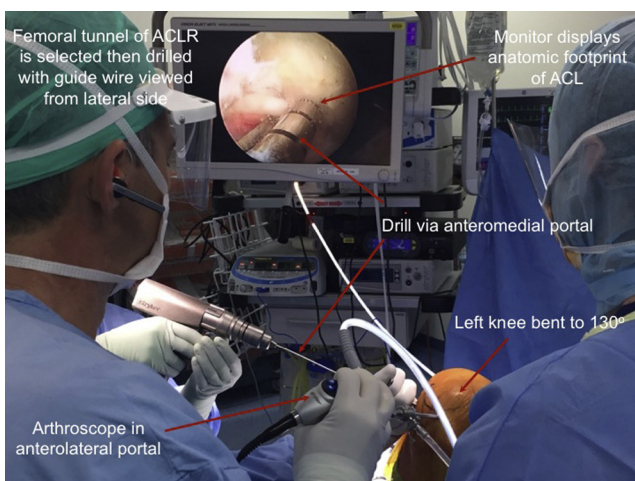


Fig 5. Step 3: The femoral tunnel position is selected and drilled. (ACL, anterior cruciate ligament; ACLR, anterior cruciate ligament reconstruction.)

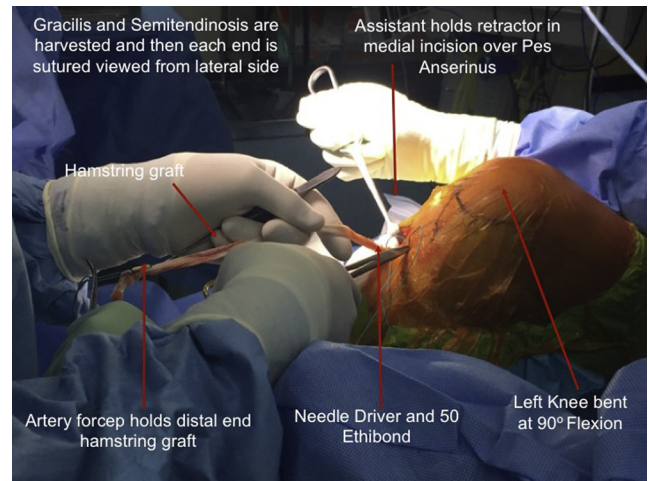


Fig 6. Step 4: The gracilis and semitendinosus tendons are harvested, and each tendon end is sutured together using a “baseball stitch.”

required to prevent anterior tibiofemoral subluxation, similar to that undertaken for final graft fixation or less. Commonly, after initial HS graft tensioning is undertaken, no further HS graft tension is required.

Medial Meniscus Repair

While anterior tibiofemoral subluxation is prevented by manual graft tension, the medial meniscus is repaired. This can be undertaken using a variety of techniques, including an all-inside, inside-out, or hybrid technique as required (Fig 10). Harvesting the graft before the repair also avoids meniscal repair suture entrapment in the GC and ST tendons.

Tibia Fixation

Finally, the graft is fixed to the tibia with an RCI screw (Smith & Nephew) with the knee in extension (Fig 11). A Lachman’s test performed by the surgeon confirms

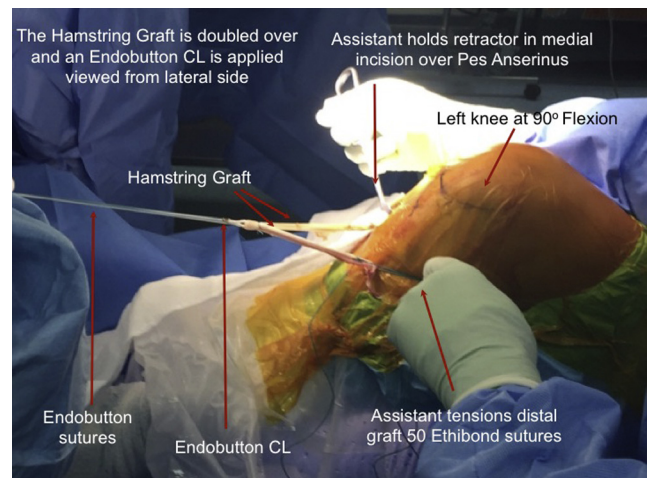


Fig 7. Step 5: The Endobutton CL is slid over the graft and each end doubled.

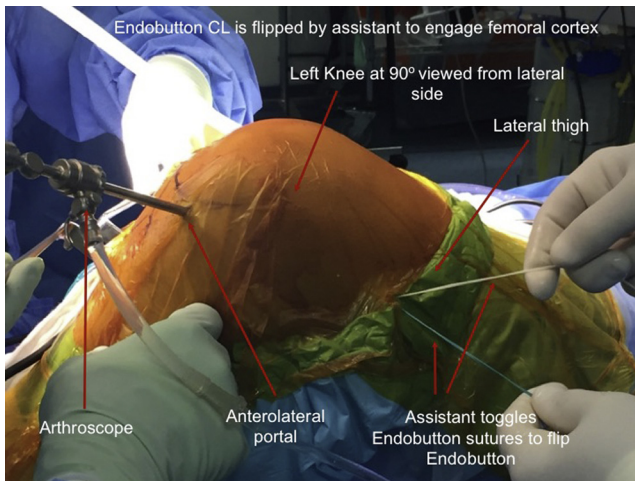


Fig 8. Step 6: The anterior cruciate ligament graft is drawn into the knee and the femoral side is fixed to the femur by flipping the Endobutton sutures.

that the graft continues to prevent anterior tibiofemoral subluxation. The superfluous distal graft ends and distal sutures can be removed using a scalpel. Closure is undertaken in layers with a subcuticular skin closure. A drain is not used. Tips, pearls, key points, indications, contraindications, and risks of the technique are shown in [Table 1](#).

Discussion

The pivot shift test was first described by Galway and MacIntosh¹³ to assess the integrity of the ACL after injury. It is a functional test of the ACL's ability to prevent anterior tibiofemoral subluxation. Previous investigations of the pivot shift phenomenon revealed that it was a very complex motion to analyze and quantify with a variety of different investigational methodologies used.^{6,14} These included most recently,

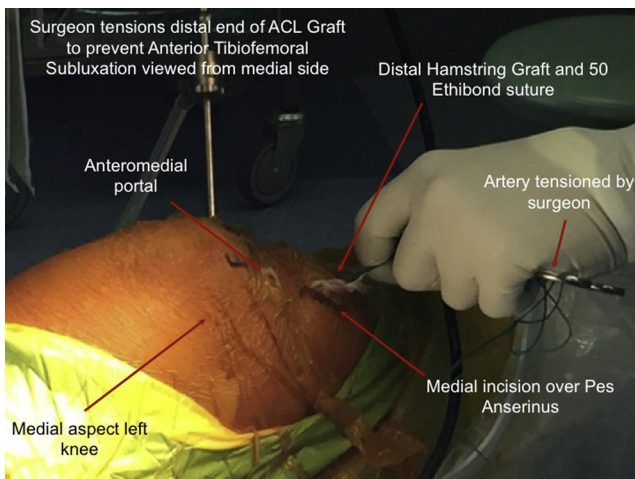


Fig 9. Step 7: The anterior cruciate ligament (ACL) reconstruction graft is then manually tensioned by the surgeon, using enough tension to prevent anterior tibiofemoral subluxation.

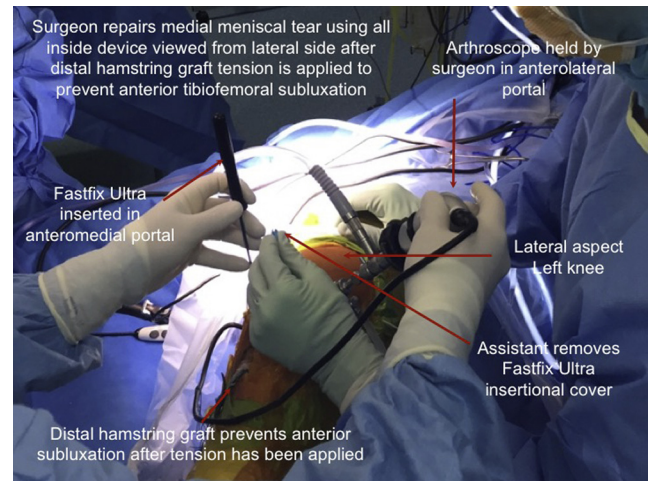


Fig 10. Step 8: The reduced medial meniscus is repaired using Fast Fix Ultra devices. Any other method of meniscal repair can be undertaken instead such as inside-out sutures.

dynamic magnetic resonance imaging¹⁵ and electromagnetic navigation.⁷ Anterior tibial translation combined with internal tibial rotation is the dominant subluxation in early flexion of ACL-deficient knees, with reduction of the translation in greater flexion. Unfortunately, the anterior tibial translation occurs in early flexion, corresponding with the position the knee is typically held in when the medial meniscal repair is undertaken. ACLR has been shown to reduce ACL rupture-induced tibiofemoral translation.^{7,15}

Chronic ACL-deficient knees have a greater degree of translation and subluxation under valgus and axial load, especially in those with medial meniscal tears. Medial compartment visualization is initially worse in these patients, and therefore the modified technique is particularly beneficial, especially in a highly unstable medial meniscus. This is important because of the

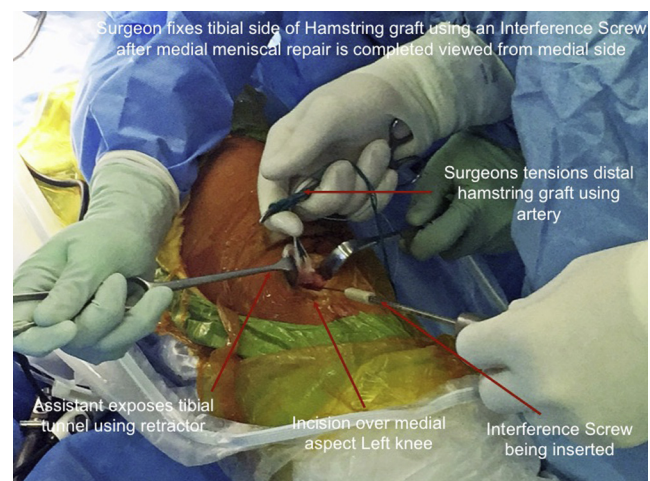


Fig 11. Step 9: The anterior cruciate ligament graft tibial fixation is undertaken using an interference screw inserted with the knee in extension.

Table 1. Tips, Pearls, Key Points, Indications, Contraindications, and Risks

Tips and Pearls:

- The amount of distal graft tension required to prevent anterior tibiofemoral subluxation is easily applied manually by pulling on the distal hamstring graft sutures by the surgeon using 1 hand.
- The technique does not improve lateral meniscal visualization; hence the lateral meniscus is best repaired after ACL stump debridement, but before femoral tunnel selection.
- Proximal graft femoral fixation failure during medial meniscal repair has never occurred while using this technique by the senior author (C.J.V.).
- The technique can be used to aid visualization in medial meniscectomy if repair is not appropriate.
- Any lateral thigh support and foot bolster can be used instead of the described devices.

Key Points:

The technique sequence is as follows:

1. Medial meniscus is reduced.
2. ACL reconstruction is undertaken using a hamstring graft without final tibia fixation.
3. Distal graft tension is manually applied to distal graft sutures by the surgeon to prevent tibiofemoral subluxation.
4. The medial meniscus is repaired while graft tension is applied.
5. The graft is then fixed to the tibia using an interference screw or another device.

Indications:

- A patient with a repairable medial meniscal tear in an ACL-deficient knee in which concurrent ACL reconstruction is being undertaken.

Contraindications:

- No specific contraindications exist if the indications are followed.

Risks:

- The tip of the meniscal repair device hitting against the graft during passage.
- Excessive graft traction could damage the graft if distal sutures are pulled out.

ACL, anterior cruciate ligament.

correlation between medial meniscal injuries in chronic ACL-deficient knees, estimated at up to 75%.²

Repair of the chronically torn medial meniscus has a relatively low failure rate; however, simultaneous ACLR improves healing rates.^{16,17} All-inside repair devices can have reported similar healing rates to inside-out sutures devices; however, sutures remain the gold standard.¹⁸ Meniscal repair after ACLR has a significantly higher failure rate.¹⁹

There are strategies currently employed to prevent the intraoperative tibiofemoral translation. First, the assistant can externally rotate the foot, preventing internal tibial rotation; however, this does not prevent anterior tibial translation.²⁰ It is also possible to release the medial collateral ligament, increasing the tibiofemoral compartment space and reducing tibiofemoral translation by defunctioning the medial collateral ligament. However, the methodology of releasing vital ligamentous structures in an already unstable knee joint when alternative visualization methods exist should be

questioned. A third option is to manually perform an anterior tibial drawer to decrease the subluxation.

Improving arthroscopic visualization decreases the risk of instrument-related chondral damage and excessive loading on meniscal sutures or repair devices.²¹ Furthermore, because the meniscus tear is deformed by the compression and shear produced by tibiofemoral translation, there is increased suture breakage risk and repair device failure during the repair process^{4,11} with the customary technique. Our technique makes the meniscal repair easier and decreases the operative time.

There are 2 possible risks with this procedure. Graft damage could potentially occur during the meniscal repair if the meniscal repair device hits against the graft during its passage. Hence, constant visualization of the tip of the meniscal repair device should occur when in the graft's vicinity. The second potential risk is damage to the graft by excessive tensioning. Hence, avoid placing more tension than can be easily applied using 1 hand while repairing the meniscus. In using the technique for over a decade this has not occurred. Commonly, once initial graft tension is applied, the surgeon does not have to tension the suture tails any further due to graft friction inside the tibia tunnel.

References

1. Smith JP, Barrett GR. Medial and lateral meniscal tear patterns in anterior cruciate ligament-deficient knees. A prospective analysis of 575 tears. *Am J Sports Med* 2001;29:415-419.
2. Ahn JH, Bae TS, Kang K-S, Kang SY, Lee SH. Longitudinal tear of the medial meniscus posterior horn in the anterior cruciate ligament-deficient knee significantly influences anterior stability. *Am J Sports Med* 2011;39:2187-2193.
3. Marzo JM, Gurske-DePerio J. Effects of medial meniscus posterior horn avulsion and repair on tibiofemoral contact area and peak contact pressure with clinical implications. *Am J Sports Med* 2009;37:124-129.
4. Markolf KL, Jackson SR, McAllister DR. Force measurements in the medial meniscus posterior horn attachment: Effects of anterior cruciate ligament removal. *Am J Sports Med* 2012;40:332-338.
5. Dürselen L, Vögele S, Seitz AM, et al. Anterior knee laxity increases gapping of posterior horn medial meniscal tears. *Am J Sports Med* 2011;39:1749-1755.
6. Lane CG, Warren R, Pearle AD. The pivot shift. *J Am Acad Orthop Surg* 2008;16:679-688.
7. Bull AMJ, Earnshaw PH, Smith A, Katchburian MV, Hassan ANA, Amis AA. Intraoperative measurement of knee kinematics in reconstruction of the anterior cruciate ligament. *J Bone Joint Surg Br* 2002;84:1075-1081.
8. Ahn JH, Kim SH, Yoo JC, Wang JH. All-inside suture technique using two posteromedial portals in a medial meniscus posterior horn tear. *Arthroscopy* 2004;20:101-108.

9. Gallacher PD, Gilbert RE, Kanen G, Roberts SNJ, Rees D. Outcome of meniscal repair prior compared with concurrent ACL reconstruction. *Knee* 2012;19:461-463.
10. Feng H, Hong L, Geng XS, Zhang H, Wang XS, Jiang XY. Second-look arthroscopic evaluation of bucket-handle meniscus tear repairs with anterior cruciate ligament reconstruction: 67 consecutive cases. *Arthroscopy* 2008;24:1358-1366.
11. Toman CV, Dunn WR, Spindler KP, et al. Success of meniscal repair at anterior cruciate ligament reconstruction. *Am J Sports Med* 2009;37:1111-1115.
12. Westermann RW, Wright RW, Spindler KP, Huston LJ, Wolf BR. Meniscal repair with concurrent anterior cruciate ligament reconstruction: Operative success and patient outcomes at 6-year follow-up. *Am J Sports Med* 2014;42:2184-2192.
13. Galway HR, MacIntosh DL. The lateral pivot shift: A symptom and sign of anterior cruciate insufficiency. *Clin Orthop Relat Res* 1980;147:45-50.
14. Tamea CD, Henning CE. Pathomechanics of the pivot shift maneuver: An instant center analysis. *Am J Sports Med* 1981;9:31-37.
15. Logan MC. Tibiofemoral kinematics following successful anterior cruciate ligament reconstruction using dynamic multiple resonance imaging. *Am J Sports Med* 2004;32:984-992.
16. Espejo-Reina A, Serrano-Fernández JM, Martín-Castilla B, Estades-Rubio FJ, Briggs KK, Espejo-Baena A. Outcomes after repair of chronic bucket handle tears of the medial meniscus. *Arthroscopy* 2014;30:492-496.
17. Paxton ES, Stock MV, Brophy RH. Meniscal repair versus partial meniscectomy: A systematic review comparing reoperation rates and clinical outcomes. *Arthroscopy* 2011;27:1275-1288.
18. Choi NH, Kim BY, Hwang Bo BH, Victoroff BN. Suture versus FasT-Fix all-inside meniscus repair at time of anterior cruciate ligament reconstruction. *Arthroscopy* 2014;30:1280-1286.
19. Walter RP, Dhadwal AS, Schranz P, Mandalia V. The outcome of all-inside meniscal repair with relation to previous anterior cruciate ligament reconstruction. *Knee* 2014;21:1156-1159.
20. Shaver JC, Johnson DL. Unlocking the "pivot shift" in ACL surgery: Medial meniscus evaluation and treatment. *Orthopedics* 2008;31:1214-1217.
21. Lin DL, Ruh SS, Jones HL, Karim A, Noble PC, McCulloch PC. Does high knee flexion cause separation of meniscal repairs? *Am J Sports Med* 2013;41:2143-2150.