

# Stagnant Loop Syndrome: A Rare Cause of Severe Malabsorption

Kilian Weigand<sup>a</sup> Christian Herfarth<sup>b</sup> Kurt Weigand<sup>c</sup>

<sup>a</sup> Department of Gastroenterology, Endocrinology, Rheumatology and Infectious Diseases, University Hospital Regensburg,

<sup>b</sup> Department of General Surgery, University Hospital Heidelberg,

<sup>c</sup> Department of Medicine and Gastroenterology, Stauferklinik, Teaching Hospital of the University of Ulm, Schwäbisch Gmünd, Germany

## Keywords

Stagnant loop syndrome · Small bowel overgrowth · Malnutrition · Anaemia

## Summary

**Background:** Intestinal bacterial overgrowth as a consequence of postsurgical anatomical abnormalities as well as other small bowel diseases can lead to malabsorption. **Case Report:** A female patient had several abdominal operations due to recurrent intestinal obstructions. Initially, she presented with severe megaloblastic anaemia. Subsequently, she suffered from weight loss, diarrhoea, oedema, recurrent anaemia (despite vitamin B12 substitution), and severe malabsorption of proteins, lipids, iron, and vitamins. Vague information about the performed surgeries, an anatomy of the bowel that was difficult to interpret, and an unusual cholestasis made it difficult to reach the diagnosis of bacterial overgrowth due to a stagnant loop syndrome. Treatment with antibiotics only temporarily improved the condition of the patient. After restoring bowel continuity and after the resection of an enteroenteric fistula as well as of a bowel conglomerate, the patient did not show any further symptoms. **Conclusion:** The history of this patient indicates that the diagnosis of a stagnant loop syndrome may be difficult. The primary goal regarding surgically created small intestinal bacterial overgrowth should be the correction of the underlying small intestinal abnormality, whenever possible.

## Schlüsselwörter

Syndrom der blinden Schlinge · Bakterielle Überbesiedlung des Dünndarms · Mangelernährung · Anämie

## Zusammenfassung

**Hintergrund:** Erkrankungen des Dünndarms, einschließlich dessen bakterielle Fehlbesiedlung, die infolge von postoperativen anatomischen Veränderungen vorkommen kann, können zur Malabsorption führen. **Fallbericht:** Eine Patientin war wegen rezidivierender Ileussympomatik mehrfach operiert worden. Zunächst wurde sie mit einer schweren megaloblastären Anämie vorgestellt. In der Folge litt sie unter Gewichtsverlust, Diarrhö, Ödemen, rezidivierenden Anämien (trotz Vitamin-B12-Substitution) und schwerer Malabsorption von Proteinen, Lipiden, Eisen und Vitaminen. Unklare Informationen über die durchgeführten Operationen, eine schwer zu interpretierende Anatomie des Darms und eine ungewöhnliche Cholestase erschwerten die Diagnosestellung der bakteriellen Überwucherung im Rahmen eines «stagnant loop syndroms» (Syndrom der blinden Schlinge). Behandlungen mit Antibiotika verbesserten die Beschwerden der Patientin nur vorübergehend. Nach Wiederherstellung der Dünndarmkontinuität, der Entfernung einer enteroenterischen Fistel und der Resektion eines Darmkonvoluts wurde die Patientin dauerhaft beschwerdefrei. **Schlussfolgerung:** Der Verlauf der Erkrankung dieser Patientin zeigt, dass die Diagnose eines «stagnant loop syndroms» schwierig sein kann und dass die beste Therapie einer chirurgisch hervorgerufenen bakteriellen Fehlbesiedlung des Dünndarms in einer chirurgischen Korrektur der anatomischen Abnormalität besteht, wann immer dies möglich ist.

## Introduction

Several diseases of the small bowel can lead to malabsorption, such as coeliac disease, inflammatory bowel diseases, and small intestinal bacterial overgrowth (SIBO). SIBO can be a consequence of reduced intestinal clearance due to impaired peristalsis and/or anatomical abnormalities altering the luminal flow [1–7]. The main reasons for anatomical abnormalities are postoperative syndromes such as short bowel syndrome, blind loop syndrome, or stagnant loop syndrome. SIBO is characterised by one or more of the following symptoms: chronic diarrhoea, diffuse abdominal pain, flatulence, meteorism, malabsorption, and weight loss. In the following case, the clinical symptoms of the patient were unusual. Therefore, it took several years until the diagnosis was finally established and the patient could be cured by surgical correction of the stasis caused by a stagnant loop syndrome.

## Case Report

The patient, a woman born in 1950, had an appendectomy in 1958. Between 1959 and 1988 she suffered from recurrent obstructions of the bowels and therefore underwent three stricturoplastic surgeries and, as reported by the patient, resection of the terminal ileum. Details of the operations were not known as the surgery protocols were not available. In 1992 she developed anaemia, with a haemoglobin of 10.3 g/dl and a MCH (mean corpuscular haemoglobin) of 39.6 pg. Vitamin B12 serum level was low with <35 pmol/l (normal level 120–700 pmol/l), and vitamin B12 excretion into urine amounted to only 1.4% of the administered dose. Autoantibodies directed against intrinsic factor could not be detected. Serum folate concentration was within the normal range, and the bone marrow showed a normal iron content. Therefore, the diagnosis of megaloblastic anaemia due to vitamin B12 deficiency, presumably as a result of a short bowel syndrome, was made. A resection of the terminal ileum was described by an X-ray of the small bowel. In contrast, only a mild gastritis and duodenitis were found by gastroscopy and colonoscopy. The ileocaecal valve and the terminal ileum were considered to be normal. D-xylose absorption was reduced. Subsequently, vitamin B12 was substituted intramuscularly. A myelodysplastic syndrome was suspected but could not be proven.

In May 1995, the patient was admitted for the first time to our gastrointestinal unit because of an elevated alkaline phosphatase (11/1993: 389 U/l; 1/1995: 235 U/l) and an elevated serum copper level (table 1). Body weight

was 55 kg, and height was 163 cm. She felt good and had no diarrhoea. Despite continuing vitamin B12 substitution, anaemia persisted. The serum levels of iron, zinc (49 µg/dl), and ferritin were low and total serum proteins were slightly reduced (table 1). Coeruloplasmin was normal with 55 mg/dl, and CRP (C-reactive protein) was elevated. Serum calcium was normal, but vitamin D3 (25-OH) was very low. In addition to vitamin B12, she received folic acid, vitamin B6, iron, and hormonal contraception.

An elevated copper level can be observed with hormonal contraception, in cholestasis, e.g. primary biliary cholestasis (PBC) or primary sclerosing cholangitis (PSC), and occasionally in late-onset Wilson's disease. PBC, PSC, and Wilson's disease could be excluded by means of endoscopic retrograde cholangiopancreatography, sonography, laboratory tests, and liver biopsy. The copper content of the liver was low with 10.6 µg/g<sub>dr</sub> (normal 15–45). Therefore, the most likely explanation for the elevated serum copper level was the hormonal contraception, which was therefore discontinued. Vitamin B12, vitamin D3, and zinc gluconate were prescribed. 6 months later, alkaline phosphatase and serum copper levels were normal but the patient was still anaemic with a normal MCV (mean corpuscular volume) (table 1). Serum levels of vitamin B12 and folic acid were slightly elevated, while zinc and vitamin D3 were within the normal range. Since serum ferritin was low, the anaemia was probably due to iron deficiency.

In October 1996, she developed oedema of the legs and diarrhoea. Stool sample tests for occult blood were positive on eight occasions. After gastroscopy, a mild *Helicobacter*-positive gastritis was found. No bleeding source could be detected either by gastroscopy or by colonoscopy. Another X-ray series of the bowel (Sellink) demonstrated extended changes of the small bowel with a thickening of the wall, fixations, and segmental elevations. Since no bleeding source could be detected by endoscopy, the occult blood in the stool was thought to be a result of an inflammation of the small bowel. Eradication therapy of the *Helicobacter* with omeprazole, metronidazole, and amoxicillin was carried out for 10 days. After the eradication therapy the diarrhoea ceased. At that time, suspicion of a blind loop syndrome was articulated for the first time and the patient received 3 × 400 mg metronidazole for another 10 days. 6 months after the therapy the patient felt good, had no diarrhoea, and tests for occult blood were negative; haemoglobin, total protein, and albumin had increased. Zinc and copper in the serum were normal (table 1). The success of the treatment supported the diagnosis of blind loop syndrome. Substitution therapy with vitamin D3, zinc, iron, and folic acid was continued. In December 1997, she developed diarrhoea and was treated again with metronidazole for 10 days. After therapy, diarrhoea ceased, she felt good, and the blood chemistry was normal.

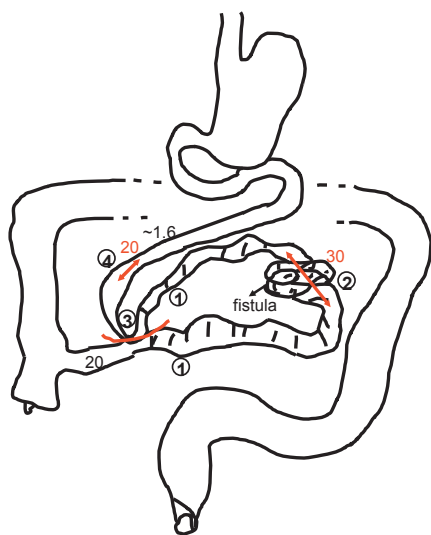
In August 2000, she presented again with diarrhoea, bloating, abdominal cramping, oedema of the lower legs, and tachycardia. Her weight was 50 kg. Blood chemistry showed anaemia and malnutrition with low serum proteins, low serum iron, a cholesterol level of 100 mg/dl, triglycerides of

**Table 1.** Selected laboratory values of the reported case at different time points

Laboratory values (normal range)	May 1995	November 1995	May 1997	August 2000	January 2005
Erythrocytes (3.8–5.2 million/µl)	3.69	3.4	3.95	2.70	4.27
Haemoglobin (11.8–15.5 g/dl)	10.9	9.8	12.1	8.3	12.7
Thrombocytes (140–440/nl)	575	669	531	719	349
Alkaline phosphatase (40–190 U/l)	192	173	146	139	74
CRP (<5 mg/l)	39	18	21	110	22
Total serum protein (6.7–8.7 g/dl)	6.5	5.3	6.4	5.2	6.2
Albumin (3–5 g/dl)	3.8	3.1	4.2	2.7	3.6
Serum iron (49–151 µg/dl)	52	nd	58	28	nd
Serum copper (65–165 µg/dl)	250	146	123	147	nd
Ferritin (30–150 ng/ml)	27	27	54	444	73.8
Vitamin D3 (25-OH) (18.5–94 nmol/l)	<12.5	50.1	nd	56.5	nd

nd = Not determined.

**Fig. 1.** Since it had not been possible to demonstrate the intraoperative situation by a photograph, the surgeon made a drawing which shows the anatomical changes of the gut impressively. These changes led to the interenteric circulation of the chyme, and as a consequence SIBO developed. 1) Stagnant loop due to a side-to-side anastomosis between jejunum and terminal ileum. 2) A bowel conglomerate including a fistula, which was resected. 3) The anastomosis between the jejunum and ileum was removed. 4) 20 cm of the jejunum were resected.



40 mg/dl, and low serum vitamin B12. CRP was markedly elevated while serum copper was normal (table 1). Pancreolauryl test was normal at 43% (normal >30%). By means of a physical examination, a fluctuating mass sized 2 × 3 cm was seen in the lower abdomen. An abscess of the abdominal wall was diagnosed by sonography and CT scan. The abscess was split and a foreign body granuloma was found. In October 2000, the operation wound had not yet healed. After the injection of a contrast agent a fistula was found. Colonoscopy showed a normal colon and a normal terminal ileum without any signs of chronic inflammatory bowel disease, especially not Crohn's disease, neither macroscopically nor histologically. No fistula could be detected by colon contrast enema. Therefore, the enterocutaneous fistula most likely originated in the small bowel. Broadened villi of the duodenum were seen by loupe gastroscopy and confirmed by histology. The patient was then transferred to the surgical department of the university hospital in Heidelberg for revision of the blind loop syndrome.

Intraoperatively, the following situation was found (fig. 1): Beginning at the flexura duodenojejunalis, the jejunum was normal for 170 cm. Within the adjacent 10 cm an enteroenteric fistula was seen. At 200 cm, a wide side-to-side anastomosis between the jejunum and the terminal ileum, 20 cm proximal of Bauhin's valve, was found. Bauhin's valve was narrow, strongly suggesting a relevant interenteric circulation with reflux from the lower to the upper jejunum. From 200 to 300 cm, the small bowel was significantly dilated and scarred, showing the typical picture of a stagnant loop syndrome. At 300–330 cm, a small bowel conglomerate was found showing extensive inflamed and clotted changes. Within the next 30 cm, another stagnant loop syndrome with dilated intestinal loops was found. The last 20 cm of the ileum and Bauhin's valve showed no pathological findings.

The following operations were performed:

- Resection of the convolute, including the enteroenteric and enterocutaneous fistulas, restoring the continuity between the proximal and distal loop.
- Resection of the jejunum at 170–180 cm, skeletonising the mesentery and performing a typical end-to-end anastomosis using a single-suture technique (Vicryl 4 × 0, backstitch).
- Removal of the side-to-side anastomosis between the jejunum and the terminal ileum. The side-to-side anastomosis was opened exactly at the site of the old anastomosis. The oval openings in the jejunum and in the ileum were closed by plastic occlusions using a single-suture technique.

Without any stenosis, complete continuity of the small bowel was restored by surgery. The histological workup of the resected bowel showed no signs of Crohn's disease but inflammatory and ischaemic changes. 4 weeks after the operation the patient developed fever, abdominal pain, leukocytosis, and swelling of the abdominal wall. An interenteric abscess was found by means of a CT scan. By minilaparotomy, the abscess was located in the region of the median laparotomy scar, reaching deep into and between the small bowel loops. The abscess, with a volume of about 100 ml, was rinsed. Subsequently, each of the three cavities was drained by a separate Robinson drainage system. Microbiological examination verified *Escherichia coli*, haemolytic *streptococci*, and anaerobic organisms. The antibiotics ceftriaxone and metronidazole were given for 12 days.

After drainage of the abscess and antibiotic treatment, the patient recovered completely and felt good for the following years. She was seen annually in the hospital, the last time in January 2005. At that time her weight was constant at 53.5 kg, while she had formed stools, had no diarrhoea, and showed almost normal laboratory values (table 1). On the occasion of an interview in 2010, she was still in good health and felt fine.

## Discussion

Our patient had two reasons for SIBO: failure of the gastric barrier due to *Helicobacter*-positive gastritis and reduced intestinal clearance. The main line of defence against bacterial colonisation of the small bowel is intestinal peristalsis [4]. Anatomical abnormalities can lead to reduced intestinal peristalsis and impaired intestinal clearance, which may result in bacterial overgrowth in the small intestine with colon-like bacteria, particularly with anaerobic gram-negative bacilli [2]. The surgically created anastomosis between jejunum and terminal ileum and the conglomerate of 30 cm of small bowel led to a stasis due to interenteric circulation of the bowel content. In addition, the enteroenteric fistula contributed to SIBO [5]. Furthermore, exocrine pancreatic insufficiency can also contribute to SIBO [3, 8]. However, the pancreatic function of the patient was normal.

The diagnosis of stagnant loop syndrome as the underlying cause for SIBO could have been made earlier if the patient and/or the local physician had had the correct information regarding the performed operations. Unfortunately, the protocols of the previous operations, some of which had been performed long ago, were not available. In contrast to the information given by the patient, the terminal ileum had not been resected, as was shown by colonoscopy. Nevertheless, a short bowel syndrome could have been possible. The anatomy of the small bowel as seen by X-ray was confusing, probably due to the unusual operations performed in the past. Two different radiologists did not detect a side-to-side anastomosis. The final diagnosis could only be made by an operation. It remains unclear why a side-to-side anastomosis was chosen as surgical treatment for an adhesive ileus in the patient. This unusual operation and the lack of correct information, combined with a rare presentation of severe malabsorption and cholestasis, led to a delayed diagnosis and therefore to a late effective treatment.

The gold standard for detecting SIBO is a culture of intestinal content. This diagnostic tool is costly and difficult for clinical

cal use [2]. In addition, more than 50% of the bacterial species in the gut are not culturable [5]. The 13C-d-xylose or the lactulose hydrogen breath tests are alternatives. Breath tests, however, are not without pitfalls. Glucose and lactulose hydrogen breath tests show a low sensitivity and have been disappointing in predicting the results of small bowel culture [9]. Furthermore, non-invasive breath tests for bacterial overgrowth are not reliable in subjects with hypochlorhydria [10]. Rapid intestinal transit may result in a false-positive breath test since the test cannot distinguish whether the substrate is metabolised in the small intestine or in the caecum. As our patient had massive diarrhoea the breath test was less useful. Furthermore, an excess number of bacteria in the small bowel does not determine a relationship to symptoms of SIBO [5]. Because the diagnosis of bacterial overgrowth may be difficult when using the laboratory tests, a therapeutic trial of antibiotic therapy is a reasonable alternative approach to the diagnosis of SIBO [8].

This patient's earliest symptom in 1992 was a megaloblastic anaemia, which was attributed to a low serum vitamin B12 level, initially thought to be a consequence of the missing terminal ileum. Since the ileocaecal valve could be seen in all colonoscopies, it was assumed that the ileum proximal to the valve had been resected. In contrast to the information given by the patient, the final operation showed that neither the ileocaecal valve nor the ileum had been resected, excluding this reason for vitamin B12 deficiency. In addition, the small bowel had a length of 330 cm. As small bowel syndrome is defined in adults as <200 cm of small intestine [6], the patient had no short bowel syndrome in contrast to the primary assumption. Vitamin B12 deficiency commonly occurs in SIBO as a result of consumption of the vitamin by anaerobic bacteria [5, 8]. Despite substitution with vitamin B12, anaemia persisted, probably due to iron deficiency. The low serum iron was most likely a consequence of blood loss due to gastrointestinal bleeding. A bone marrow disease had been excluded as a reason for the anaemia.

The reason for transferring the patient to the gastrointestinal unit was elevated alkaline phosphatase and elevated serum copper. These symptoms, which are usually not related to bacterial overgrowth, made the diagnosis even more difficult. In more than 90% of the patients with unclear cholestasis the diagnosis can be obtained by liver biopsy [11]. Liver biopsy showed normal portal tracts and bile ducts. Except for peliosis hepatis, probably due to the contraceptive agent, no liver disease was found histologically.

The degree to which nutrient absorption is impaired by SIBO is usually not of clinical relevance [5]. The main features of SIBO in this patient, however, were severe malabsorption and weight loss. Malabsorption can be a consequence of mucosal inflammation and of metabolic action of the intraluminal bacteria [1, 7]. Maldigestion and malabsorption in SIBO are responsible for impaired absorption of the components of fat, carbohydrates, and proteins as well as of vitamins and iron. The very low concentration of cholesterol and tri-

glycerides in the serum is a result of a malabsorption of fatty acids and chylomicrons [1] and of a deconjugation of bile acids by small bowel bacteria, making them unavailable for micellar solubilisation. In addition, deconjugated bile acids inhibit the absorption and esterification of fatty acid and are toxic to the enterocytes [1, 5–7].

A low serum albumin level in blind loop syndrome has been previously described [12, 13]. Our patient had severe protein malnutrition, probably as a combined result of protein-losing enteropathy and reduced protein synthesis in the liver. A consequence of the obstruction and stasis of the small bowel is an inflammation of the epithelium, leading to increased exudation of plasma proteins. The ulcerations found in the resected small bowel led to a loss of plasma proteins and explain the observed blood loss in the stools. In addition, protein synthesis in the liver was most likely diminished due to bacterial deamination of amino acids [12, 13] as well as diminished brush border peptidases, followed by reduced amino acid uptake [1]. The consequence of hypoalbuminaemia is a diminished colloid osmotic pressure, followed by hyperaldosteronism, both leading to the observed oedema [14].

Diarrhoea, bloating, and distension of the abdomen, of which the patient complained, are a consequence of impaired monosaccharide absorption and subsequent bacterial degradation of sugars [1, 5]. D-xylose absorption is often reduced [4], as seen in this patient. Carbohydrate maldigestion and malabsorption is due to gut damage and diminished enterocyte brush border disaccharidases [1]. The presence of hydroxylated fatty acids and deconjugated bile acids may also contribute to the abdominal symptoms [5].

Each time after treatment with antibiotics directed against anaerobic bacteria (particularly with metronidazole; rifaximin was not available at that time) the condition of the patient improved, i.e. stools, laboratory tests, and body weight normalised. However, the symptoms always recurred at varying intervals. Only the elimination of the fistulas and the anastomosis, and thus of the stagnant loop, in addition to restoring the bowel continuity through surgery, finally led to permanent improvement, as was monitored by a gain in body weight and a normalisation of laboratory values such as haemoglobin, albumin, iron, and vitamin B12. This may indicate that the primary goal in surgically created SIBO should be the correction of the underlying small intestinal abnormality, whenever possible [4].

### Acknowledgment

The critical review of the manuscript by Andy Laycock is gratefully acknowledged.

### Disclosure Statement

The authors have nothing to disclose regarding this case report and declare that they have no competing interests.

## References

- 1 King CE, Toskes PP: Bacterial overgrowth syndromes; in Berk JE (ed): *Bockus Gastroenterology*. Philadelphia, Saunders, 1985, pp 1781–1791.
- 2 Husebye E: The pathogenesis of gastrointestinal bacterial overgrowth. *Chemotherapy* 2005;51(suppl 1):1–22.
- 3 Bures J, Cyrany J, Kohoutova D, et al: Small intestinal overgrowth syndrome. *World J Gastroenterol* 2010;16:2978–2990.
- 4 Gregg CR, Toskes PP: Enteric bacterial flora and small bowel bacterial overgrowth syndrome; in Feldman M, Friedman LS, Sleisenger MH (eds): *Gastrointestinal and Liver Disease*. Philadelphia, Saunders, 2002, pp 1783–1793.
- 5 Dibaise JK, Young RJ, Vanderhoof JA: Enteric microbial flora, bacterial overgrowth, and short-bowel syndrome. *Clin Gastroenterol Hepatol* 2006;4:11–20.
- 6 Buchman AL: Etiology and initial management of short bowel syndrome. *Gastroenterology* 2006;130:S5–15.
- 7 Stein JM, Schneider AR: Bacterial overgrowth syndrome. *Z Gastroenterol* 2007;45:620–628.
- 8 Quigley EMM, Quera R: Small intestinal bacterial overgrowth: roles of antibiotics, prebiotics, and probiotics. *Gastroenterology* 2006;130:S78–90.
- 9 Corazza GR, Menozzi MG, Strocchi A, et al: The diagnosis of small bowel bacterial overgrowth. Reliability of jejunal culture and inadequacy of breath hydrogen testing. *Gastroenterology* 1990;98:302–309.
- 10 Saltzman JR, Kowdley KV, Pedrosa MC, et al: Bacterial overgrowth without malabsorption in elderly hypochloric subjects. *Gastroenterology* 1994;106:615–623.
- 11 Weigand K, Weigand K: Percutaneous liver biopsy: retrospective study over 15 years comparing 287 inpatients with 428 outpatients. *J Gastroenterol Hepatol* 2009;24:792–799.
- 12 Weigand K: Synthese, Verteilung und Bedeutung von Serumalbumin; in Ahnefeld FW (ed): *Klinische Anästhesiologie und Intensivtherapie*. Berlin, Springer, 1980, pp 52–64.
- 13 Weigand K: Die Regulation des Serumalbuminspiegels unter physiologischen und pathologischen Bedingungen. *Klin Wochenschr* 1977;55:295–305.
- 14 Weigand K: Gastrointestinaler Proteinverlust; in Aeberhard P, Koelz HR (eds): *Gastroenterologische Pathologie*. Berlin, Springer, 1987, pp 169–176.