

ID Design Press, Skopje, Republic of Macedonia
 Open Access Macedonian Journal of Medical Sciences. 2019 Sep 30; 7(18):3015-3017.
<https://doi.org/10.3889/oamjms.2019.417>
 eISSN: 1857-9655
Global Dermatology



A Sheep in Wolf's Clothing: Lobular Pyogenic Granuloma Masquerading Nodular Amelanotic Melanoma

Jacqueline Schönlebe¹, Uwe Wollina^{2*}

¹*Institute of Pathology "Georg Schmorl", Städtisches Klinikum Dresden, Academic Teaching Hospital, Dresden, Germany;*
²*Department of Dermatology and Allergology, Städtisches Klinikum Dresden, Academic Teaching Hospital, Dresden, Germany*

Abstract

Citation: Schönlebe J, Wollina U. A Sheep in Wolf's Clothing: Lobular Pyogenic Granuloma Masquerading Nodular Amelanotic Melanoma. Open Access Maced J Med Sci. 2019 Sep 30; 7(18):3015-3017. <https://doi.org/10.3889/oamjms.2019.417>

Keywords: Amelanotic melanoma; Pyogenic granuloma; Histology; Treatment

***Correspondence:** Uwe Wollina, Department of Dermatology and Allergology, Städtisches Klinikum Dresden, Academic Teaching Hospital, Dresden, Germany. E-mail: Uwe.Wollina@klinikum-dresden.de

Received: 30-Jul-2019; **Revised:** 04-Aug-2019; **Accepted:** 15-Aug-2019; **Online first:** 30-Aug-2019

Copyright: © 2019 Jacqueline Schönlebe, Uwe Wollina. This is an open-access article distributed under the terms of the Creative Commons Attribution-NonCommercial 4.0 International License (CC BY-NC 4.0)

Funding: This research did not receive any financial support

Competing Interests: The authors have declared that no competing interests exist

BACKGROUND: Tumor masquerading is a common phenomenon seen in clinical dermatology. While amelanotic melanoma is known to simulate pyogenic granuloma, a benign vascular tumour, the contrary has been reported exceptionally scarce.

CASE PRESENTATION: We present a 52-year-old woman with a slow-growing lesion on her right flank, which developed over 12 months. On examination, we observed a large exophytic, easily bleeding tumour on the right flank, that resembled amelanotic malignant melanoma. Histologic analysis after complete excision of the lesion confirmed a pyogenic granuloma of the lobular capillary hemangioma subtype. In the present case masquerading of the lesion went to the better site after histologic investigations despite the delay of diagnosis caused by the patients.

CONCLUSION: Nevertheless, the diagnosis of uncertain lesions needs a rapid histologic analysis to gain the best possible prognosis for the patient.

Introduction

Pyogenic granuloma (syn. telangiectatic granuloma) is a common benign vascular tumour [1]. Genetic studies suggested that pyogenic granuloma is resulting from tissue injury, followed by an impaired wound healing response, during which vascular growth is driven by two major factors: (a) the ms-related tyrosine kinase 4, also known as FLT4, and (b) the nitric oxide pathway. The *FLT4* gene encodes a tyrosine kinase receptor for vascular endothelial growth factors C and D involved in angiogenesis [2]. Furthermore, BRAF mutations and probably herpes virus type 1, Orf virus and/or human papillomavirus type 2 may play a role in its pathogenesis [1].

Cawson et al., (1998) have described two subtypes depending on the rate of proliferation and vascularity: (a) lobular capillary hemangioma and (b) non-lobular capillary hemangioma. In the latter,

perivascular mesenchymal cells remain negative for alpha-smooth muscle actin but develop a vascular core that resembles granulation tissue [3]. They demonstrate a typical trajectory, starting with a cellular phase that transforms into capillary and eventually involution phase. Since malignancies such as melanoma and sarcoma can masquerade as pyogenic granuloma, early diagnosis and treatment may be life-saving [4].

Case Report

A 52-year-old woman presented with an easy bleeding exophytic lesion on her right flank.

She reported that the nodule had been grown for about 12 months. During the last weeks, the lesion started bleeding. Therefore, she consulted her doctor.

On examination, we observed an exophytic nodular, auburn tumour, easily bleeding, with a size of 3 x 2.7 cm (Figure 1). Dermoscopy was hampered by bleeding. The patient had no current medications and was otherwise healthy. The working hypothesis was a possible amelanotic melanoma. Tumour staging with imaging techniques (diagnostic ultrasound and X-ray) did exclude any metastatic spread. The lesion was completely surgically removed. The defect was closed by a large skin advancement flap. Healing was uneventful.

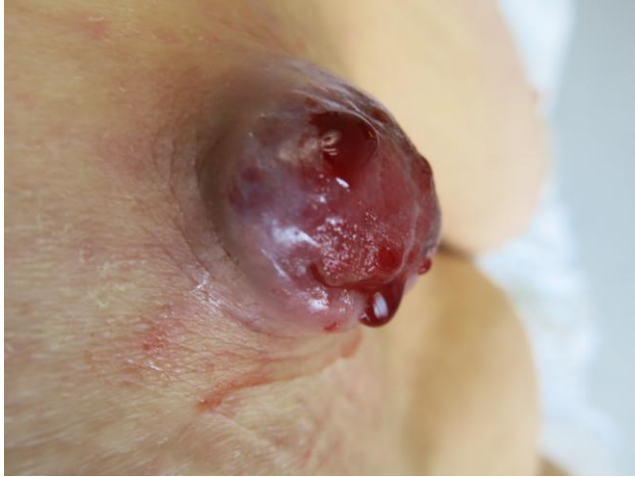

Figure 1: Clinical presentation of a large exophytic polypoid bleeding tumour

Histologic examination revealed a tumour thickness of 3.3 cm. The tumour was covered by a pseudo-capsule. We noticed a lobular vascular tumour with some larger vessels and numerous capillaries. There was a peripheral connective tissue septa formation. Numerous clumsy, partly epithelioid endothelial cells lined capillaries (Figure 2). Mitotic endothelial cells reactive with Ki67 were noticed. Several cavernous enlarged vascular spaces were located in the periphery. Thrombotic vascular obstructions could also be seen, some vessels with partial recanalisation.

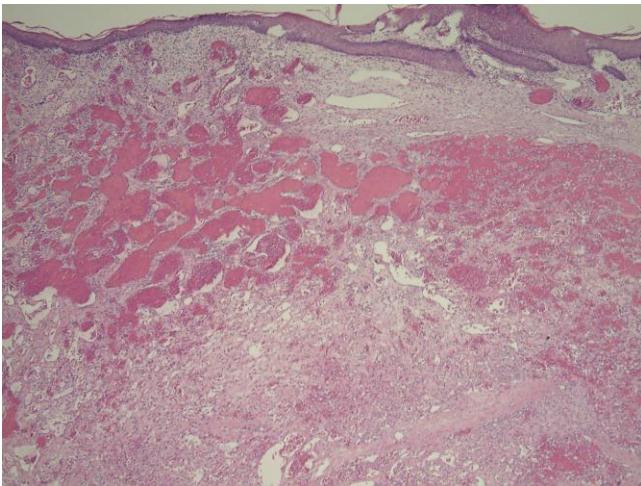


Figure 2: Histopathology of pyogenic granuloma demonstrating a lobular vascular structure (Hematoxylin-eosin x 2)

Endothelial cells were positive for CD31 and CD34, but completely negative for D2-40, human herpes virus-8 and c-Myc (Figure 3 and 4). The intra-tumoral vessels were surrounded by smooth muscle-actin positive pericytes. Tumour resection was complete (R0).

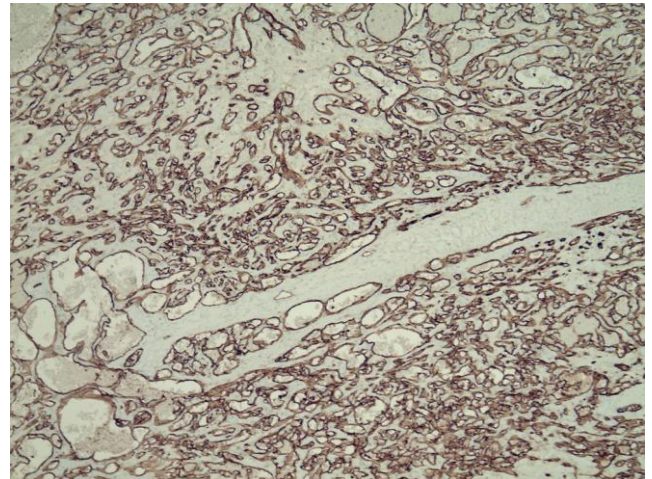


Figure 3: Immunohistology with a monoclonal antibody against CD31 staining the tumour vessels (Immunoperoxidase, x 4)

The diagnosis of a large lobular pyogenic granuloma was made.

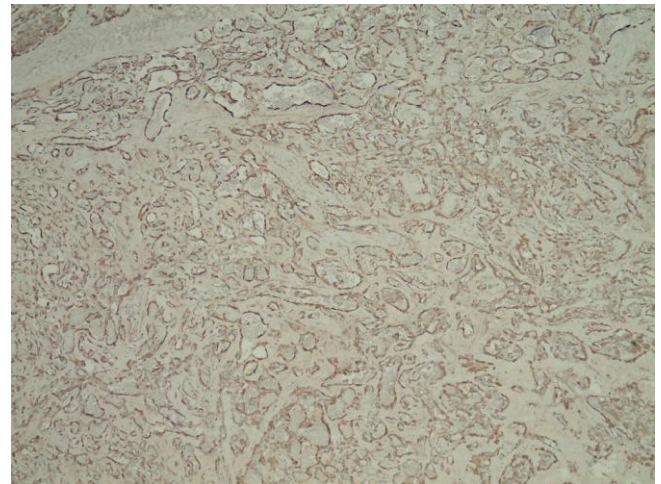


Figure 4: Immunohistology with a monoclonal antibody against smooth muscle actin staining the perivascular cells around tumour vessels (Immunoperoxidase, x 4)

Discussion

We reported a pyogenic granuloma mimicking AMM. This is a very rare observation. Charles and Kahn (2017) observed an infarcted tarsal pyogenic granuloma simulating melanoma in a 34-year older adult [5]. Zaballos et al., (2009) reported about an 18-year old male with a crusted lesion on the thorax measuring about 1 cm, which could not be

distinguished from melanoma by dermoscopy [6].

This group tried to define typical dermoscopic patterns for pyogenic granuloma and its differential diagnosis. Vascular structures were observed in 45% of pyogenic granulomas but with low sensitivity and specificity. The pattern composed of 'reddish homogeneous area', 'white rail lines' and 'vascular structures' showed the highest sensitivity (22.1%) and specificity (100%) for pyogenic granuloma [7]. Other lesions that might masquerade melanoma include small atypical congenital melanocytic nevi [8] and hypercellular encapsulated neuroma [9].

In contrast, amelanotic melanoma (AMM) may simulate pyogenic granuloma. AMM account for a small proportion of all melanomas, i.e. between 1.8% to 8.1% [10]. Due to the lack of typical clinical features of melanoma, they pose a risk of delayed diagnosis and poor prognosis. In a large study of 2038 patients diagnosed with melanoma, about 0.5% had a pyogenic granuloma-like AMM. The mean age at diagnosis was 56 years, and the meantime from lesion appearance to diagnosis was 91.5 ± 117.1 months. Nine tumours were located on the skin surface, and one on the oral mucosa. The mean Breslow's depth was 6.47 ± 3.1 mm. At diagnosis, 70% of patients had lymph node involvement or distant metastasis; two patients died of AMM within 12 months of diagnosis [11].

In conclusion, masquerading of other lesions, may they be benign or malignant, is a phenomenon that is not uncommon in clinical dermatology. It is important to be aware of this. We recommend a histologic analysis in case of suspected AMM and pyogenic granuloma to avoid diagnostic delay and to prevent a poor prognosis. Our patient was lucky because the suspected malignant tumour could be eliminated from suspected tumours and the healing was complete after surgical excision.

References

1. Godfraind C, Calicchio ML, Kozakewich H. Pyogenic granuloma, an impaired wound healing process, linked to vascular growth driven by FLT4 and the nitric oxide pathway. *Mod Pathol*. 2013; 26:247-55. <https://doi.org/10.1038/modpathol.2012.148> PMID:22955520
2. Wollina U, Langner D, França K, Gianfaldoni S, Lotti T, Tchernev G. Pyogenic granuloma - a common benign vascular tumor with variable clinical presentation: new findings and treatment options. *Open Access Maced J Med Sci*. 2017; 5:423-6. <https://doi.org/10.3889/oamjms.2017.111> PMID:28785323 PMID:PMC5535648
3. Cawson RA, Binnie WH, Speight PM, Barrett AW, Wright JM. *Lucas Pathology of Tumors of Oral Tissues*. 5th. St. Louis, Mo, USA: Mosby, 1998.
4. Marla V, Shrestha A, Goel K, Shrestha S. The histopathological spectrum of pyogenic granuloma: a case series. *Case Rep Dent*. 2016; 2016:1323798. <https://doi.org/10.1155/2016/1323798> PMID:27382492 PMID:PMC4921146
5. Charles NC, Kahn JB. Infarcted tarsal pyogenic granuloma simulating malignant melanoma. *Ophthalmic Plast Reconstr Surg*. 2017; 33(3S Suppl 1):S33-4. <https://doi.org/10.1097/IOP.0000000000000525> PMID:26164159
6. Zaballos P, Rodero J, Serrano P, Cuellar F, Guionnet N, Vives JM. Pyogenic granuloma clinically and dermoscopically mimicking pigmented melanoma. *Dermatol Online J*. 2009; 15:10.
7. Zaballos P, Carulla M, Ozdemir F, Zalaudek I, Bafiuls J, Llambrich A, Puig S, Argenziano G, Malvey J. Dermoscopy of pyogenic granuloma: a morphological study. *Br J Dermatol*. 2010; 163:1229-37. <https://doi.org/10.1111/j.1365-2133.2010.10040.x> PMID:20846306
8. Tchernev G, Chokoeva AA, Terziev I, Grigorov Y, Lotti T, Wollina U, Cardoso JC, Yungareva I, Lozev I, Maximov GK. Small dysplastic congenital melanocytic nevi in childhood as possible melanoma imitators. *Open Access Maced J Med Sci*. 2018; 6:149-51. <https://doi.org/10.3889/oamjms.2018.018> PMID:29484015 PMID:PMC5816289
9. May C, LeBoit P, McCalmont T, Argenyi Z. Hypercellular encapsulated neuroma imitating desmoplastic melanoma. *Am J Dermatopathol*. 2019; 41:358-60. <https://doi.org/10.1097/DAD.0000000000001302> PMID:30531539
10. Koch SE, Lange JR. Amelanotic melanoma: the great masquerader. *J Am Acad Dermatol*. 2000; 42:731-4. <https://doi.org/10.1067/mjd.2000.103981> PMID:10775846
11. Moshe M, Levi A, Ad-El D, Ben-Amitai D, Mimouni D, Didkovsky E, Feinmesser M, Lapidot M. Malignant melanoma clinically mimicking pyogenic granuloma: comparison of clinical evaluation and histopathology. *Melanoma Res*. 2018; 28:363-7. <https://doi.org/10.1097/CMR.0000000000000451> PMID:29750750