

Received: 21 November 2018 | Accepted: 15 February 2019

DOI: 10.1002/ame2.12060

**SHORT COMMUNICATION**

WILEY

# Animal models of acute gastric mucosal injury: Macroscopic and microscopic evaluation

Sandra Simões<sup>1</sup>  | Rui Lopes<sup>1</sup> | Maria Celeste Dias Campos<sup>2,3</sup> | Maria João Marruz<sup>4</sup> | Maria Eugénia Meirinhos da Cruz<sup>1</sup> | Luísa Corvo<sup>1</sup>

<sup>1</sup>Faculdade de Farmácia, Instituto de Investigação do Medicamento (iMed. ULisboa), Universidade de Lisboa, Lisboa, Portugal

<sup>2</sup>Serviço de Anatomia Patológica, Hospital Curry Cabral, Lisboa, Portugal

<sup>3</sup>ANATOMIK, Avenida Campo Grande 168, 1700-094, Lisboa, Portugal

<sup>4</sup>Hospital do Mar, Bobadela, Portugal

**Correspondence**

Sandra Simões and Luísa Corvo, Instituto de Investigação do Medicamento (iMed. ULisboa), Faculdade de Farmácia, Universidade de Lisboa, Lisboa, Portugal. Emails: [ssimoes@ff.ulisboa.pt](mailto:ssimoes@ff.ulisboa.pt); [lcorvo@ff.ulisboa.pt](mailto:lcorvo@ff.ulisboa.pt)

**Funding information**

Agência de Inovação, Grant/Award Number: XILOGASTRO/AdI/2003; Fundação para a Ciência e Tecnologia, Grant/Award Number: UID/DTP/04138/2013; FAIR, Grant/Award Number: FAIR-PI97 3811; JABA Recordati

**Abstract**

Acute gastric mucosal injury is a common disorder of the gastrointestinal tract and the search for new therapeutics is ongoing. The aim of this study is to update and expand the information related to the most widely used rat models of acute gastric ulcer, the ethanol-induced ulcer and the indomethacin-induced ulcer. These two models are compared in terms of macroscopic and microscopic features. Experimentally, ethanol was given orally in a single dose and indomethacin was subcutaneously injected into male Wistar rats. After ulcerative challenges, the stomachs were removed and visually inspected. Anti-ulcerative drugs were used to validate the models. Histological analysis of the stomachs determined the microscopic score. The methodology used for model evaluation applied to macroscopic and microscopic gastric lesions. With these methods it was possible to induce lesions in the gastric mucosa. Microscopic evaluation permitted assessment of the inflammatory and apoptotic impact in the mucosa not observable by macroscopic evaluation. Groups of animals were treated with two standard drugs: sulcralfate suspension or lansoprazole solution. Both drugs reduced macroscopic and microscopic lesions, particularly the hemorrhagic ones. Both models induced acute gastric mucosal injury and no single evaluation method can address all the aspects of the pathology of gastric lesions. As a complement to macroscopic evaluation, microscopy appears to be a relevant tool to selectively identify specific aspects of the development of mucosal injury, quantify the extent of lesions, and contribute to an appropriate interpretation of results. The score systems established here offer a reliable method for testing antiulcer drugs.

**KEYWORDS**

animal models, gastric ulcer, histology, pre-clinical assays

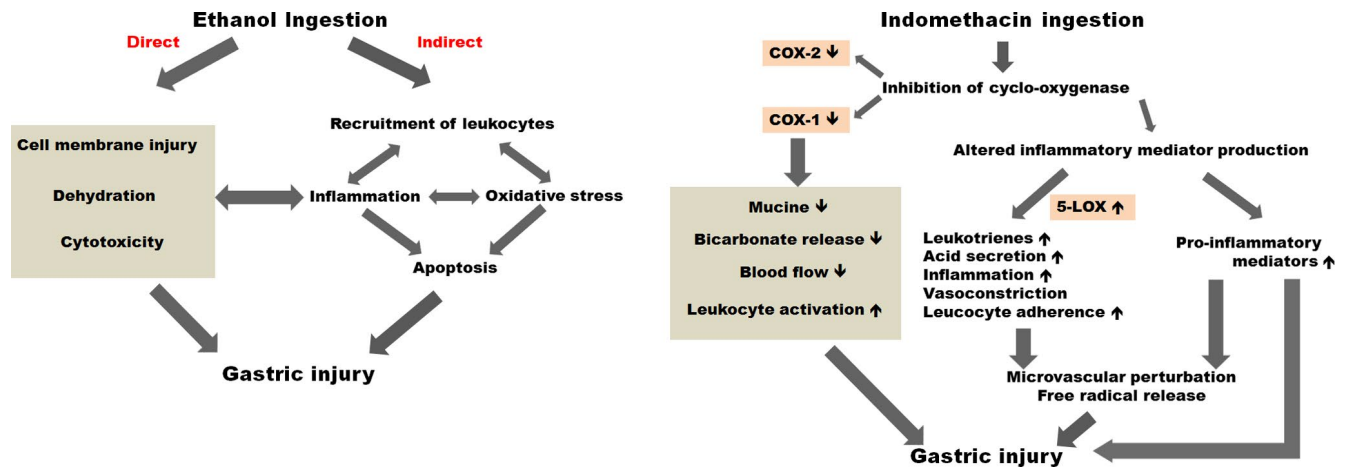
## 1 | INTRODUCTION

Gastric ulcers are common digestive disorders involving stomach mucosal lesions, with an estimated incidence of 4 million people worldwide annually.<sup>1</sup> They are mostly provoked by an imbalance

between aggressive factors such as acid, pepsin, refluxed bile salts, and ingested drugs, and defensive factors in the digestive tract such as the mucus bicarbonate barrier and the surface epithelial cells.<sup>2</sup> The discovery in the early 1980s that *Helicobacter pylori* is a major cause of peptic ulcer has had a significant impact on management of the

This is an open access article under the terms of the Creative Commons Attribution-NonCommercial-NoDerivs License, which permits use and distribution in any medium, provided the original work is properly cited, the use is non-commercial and no modifications or adaptations are made.

© 2019 The Authors. *Animal Models and Experimental Medicine* published by John Wiley & Sons Australia, Ltd on behalf of The Chinese Association for Laboratory Animal Sciences



**FIGURE 1** Left, Ethanol-induced gastric injury is caused by direct and indirect mechanisms. Right, Cellular and molecular events involved in the indomethacin-induced gastric injury

disease, and consequently a decrease of incidence of *H pylori* has occurred in the recent years. However, other factors like stress, smoking and alcohol-related behaviour, and excessive intake of non-steroidal anti-inflammatory drugs have increased the incidence of gastric ulcers of various origins.<sup>3</sup> Most of the commercially available drugs such as omeprazole and other anti-acid drugs show limited efficacy against gastric disorders and are often associated with serious side effects.<sup>4</sup>

It has long been known that alcohol consumption can trigger inflammation of the gastric mucosa (Figure 1, left). Once administered, ethanol rapidly penetrates the gastrointestinal mucosa causing membrane damage, cell exfoliation, and erosion. Increased mucosal permeability to gastric acid resulting from these effects, together with the release of vasoactive products from mast cells, macrophages, and blood cells can lead to necrosis and subsequently to ulcer formation.<sup>5</sup>

A wide number of models for inducing gastric lesions are used to screen for the ability of new therapeutics to protect the gastric mucosa, but no systematic comparison is available. Gastric mucosal lesions can be induced by hypothermic restraint stress, pylorus ligation, or agents that damage or necrotize the mucosa including ethanol, HCl, NaOH, and non-steroidal anti-inflammatory drugs (like aspirin, indomethacin, and phenylbutazone). Ethanol is generally used for ulcerogenesis studies. An example is the use of ethanol-induced ulcerogenesis models to evaluate the treatment of peptic ulcers in Turkish folk medicine through the application of mature fruits of *Momordica charantia* L.<sup>6</sup> Ligumskys and co-workers studied the effect of several antioxidants on ethanol-induced gastric lesions in rats,<sup>7</sup> and suggested that ethanol-induced gastric damage is associated with generation of oxygen-derived radicals independent of the xanthine oxidase system. Other authors<sup>8</sup> suggested that use of plant extracts of *Centella asiatica* prevents ethanol-induced gastric mucosal lesions by strengthening the mucosal barrier and reducing the damaging effects of reactive oxygen species (ROS). Pannangpetch et al reported an antipeptic ulcer effect using banana extracts, although the effect was found to be dependent on banana variety.<sup>9</sup> They hypothesized that a prostaglandin-type action mechanism could be present.

Other processes, such as the production of ROS, reduction of prostaglandin synthesis and increased synthesis of leukotrienes may

also contribute to alcohol-induced gastric lesions. Thus, the use of the ethanol-induced ulcer model allows the induction of gastric ulcers by direct action on the mucosa.<sup>5</sup>

Non-steroidal anti-inflammatory drugs (NSAIDs) such as indomethacin have been widely used clinically as anti-inflammatory and analgesic agents. However, gastrointestinal lesions have been documented as adverse effects attributed to the treatment of patients with NSAIDs.<sup>10</sup> Although the mechanisms of this ulcer action are not yet fully understood, previous studies suggest that inhibition of prostaglandin synthesis, neutrophil accumulation, reduced mucosal blood flow, and reduced mucosal cell proliferation contribute to the pathogenic mechanisms (Figure 1, right).<sup>11</sup>

Subcutaneous administration of indomethacin has been used as an animal model and is useful for testing the anti-ulcer activity of novel drugs. Although it presents the same eventual results as the ethanol induction model, that is, ulcer formation, this model constitutes an indirect route of ulcer induction. Indirect induction is currently responsible for a large proportion of the ulcers diagnosed in man due to prescription and administration of NSAIDs.

The aim of this work is to compare two common animal models generally used to develop pharmaceuticals for treating gastrointestinal tract disorders, the ethanol-induced gastric ulcers model and indomethacin-induced ulcers model, both in rats. Quantitative evaluation of gastric ulcers is an important concern for researchers. The score system developed in this work allowed a quantitative evaluation of both macroscopic and microscopically observable lesions, including the size and number of gastric erosions and also the degree of inflammation, apoptosis, and hemorrhage.

## 2 | MATERIALS AND METHODS

### 2.1 | Materials

Ethanol and indomethacin were purchased from Sigma Chemical Co. (St Louis, MO, USA). Sucralfate (1000 mg/5 mL oral suspension; Ulcermin<sup>®</sup> JABA Recordati) and lansoprazole (60 mg capsules; Alexin<sup>®</sup>, JABA

Recordati) were a gift from JABA Recordati. Sodium bicarbonate was analytical grade and was purchased from Merck (Darmstadt, Germany).

## 2.2 | Animals

Male Wistar rats weighting 200–250 g were provided by Instituto Gulbenkian de Ciência, Oeiras, Portugal. Animals were acclimatized before the experiments and housed (three per cage) in plastic cages (Tecniplast, Dias de Sousa S.A., Portugal) under standard laboratory conditions using corn cob bedding (CORNCOB ULTRA 12, Ultragene, Portugal). They were fed with standard laboratory autoclavable rodent diet (4RF21A, Ultragene, Portugal) and acidified drinking water ad libitum. The room was maintained at  $21 \pm 2^\circ\text{C}$  with  $55 \pm 10\%$  humidity and with a 12:12 hours light/dark cycle. All animal experiments were carried out with the permission of the local animal ethics committee, and in accordance with the Declaration of Helsinki, EEC Directive (2010/63/UE) and Portuguese Law (DL 113/2013, Despacho n° 2880/2015), and all following legislation for the humane care of animals in research. The experimental protocol was approved by the Direcção Geral de Alimentação e Veterinária (DGAV). For each model, two treatment groups were used (at least 3 animals per group), and one group received no treatment (3 animals). A group of animals (3 animals) received no ethanol, no indomethacin or any other substance, serving as the negative control. The intra-gastric gavage procedure was performed without anesthesia, by gently restraining the animal to immobilize the head and to maintain the animal in a vertical position, and passing the gavage needle along the side of the mouth.

## 2.3 | Animal models

### 2.3.1 | Ethanol-induced gastric ulcers

Animals were fasted for 24 hours with free access to water and maintained in this condition after ethanol administration. To induce gastric ulcers, ethanol (96%; 1 mL) was administered by intra-gastric gavage, using ball-tipped 18-gauge stainless steel curved feeding needle (76 mm length; Harvard Apparatus, Holliston, MA, USA).<sup>7</sup> Ethanol administration usually took place during the morning. One hour after ethanol administration animals were sacrificed.

### 2.3.2 | Indomethacin-induced gastric ulcers

Animals were fasted for 24 hours with free access to water and maintained in this condition after indomethacin administration. Ulcers were induced by the administration of 0.5 mL indomethacin solution (50 mg/kg) by subcutaneous injection. In a preliminary experiment, we tested the time needed to induce ulcers (Figure S1). For that study, animals were sacrificed at different time points. This test determined that the action of indomethacin is slower than that of ethanol, only inducing ulcers 8 hours after subcutaneous administration. Indomethacin administration usually took

place during the morning. Eight hours after subcutaneous administration animals were sacrificed.

### 2.3.3 | Treatment with model drugs

For each induced gastric ulcer model, one group of animals (at least three animals per group) was treated with 50 mg/kg (1 mL) sucralfate suspension by intra-gastric gavage, using a ball-tipped 18-gauge stainless steel curved feeding needle (76 mm length; Harvard Apparatus, Holliston, MA, USA), 15 minutes before challenge; and another group of animals was treated with 30 mg/kg (1 mL) lansoprazole solution (prepared from lansoprazole capsules solubilized in 8.4% sodium bicarbonate) by intra-gastric gavage, as described above, 15 minutes before challenge. As previously described, animals were sacrificed 1 hour after ethanol administration or 8 hours after indomethacin injection.

## 2.4 | Gastric lesion evaluation

### 2.4.1 | Macroscopic and microscopic evaluation

Stomachs were immediately removed after sacrifice, opened along the greater curvature and washed with saline solution (0.9% NaCl). After examination by a blinded pathologist, tissues were photographed and then fixed in buffered formalin to undergo histological preparation. The scoring system for macroscopic and microscopic evaluation used in this work is presented in Table 1.

### 2.4.2 | Histological studies

For histopathological examinations, stomachs were embedded in paraffin blocks, sectioned at 5  $\mu\text{m}$  intervals, mounted on glass microscope slides and stained with hematoxylin and eosin. Histological characterization comprised the following parameters: tissue erosion depth, and presence of hemorrhage, inflammation, and apoptosis. Representative histology images of each score are presented. (Figures S2 and S3).

## 3 | RESULTS AND DISCUSSION

The gastric ulcer induction assays revealed macroscopic or microscopic mucosal tissue damage in both ethanol and indomethacin models (Figure 2). The animals receiving 96% ethanol developed a consistent pattern of macroscopic damage, as evidenced by the presence of hemorrhagic ulceration (Figure 3A1). Identical damage was macroscopically observed in indomethacin-induced ulcers (Figure 3B1). Stomachs from negative control animals were scored as zero (panel labeled 0 in Figure 3).

Gastric mucosal damage was attenuated by the administration of sucralfate (50 mg/kg) and to a greater extent by lansoprazole (30 mg/kg) in both models tested macroscopically and microscopically (Figure 2), compared to non-treated animals (Figure 2, control groups). Macroscopically, the stomachs of animals treated with

**TABLE 1** Macroscopic and microscopic score evaluation

Macroscopic			
Hemorrhage	Score 1	Score 2	Score 3
Size	Punctiform (focal < 2 mm)	Mild (2-5 mm)	Intense or in bands (>5 mm)
Number	0-4	5-6	≥7
Site	Unilaterals	Bilaterals	
Microscopic			
	Score 1	Score 2	Score 3
Depth of the erosion	Up to 1/3 of total mucosa depth	Up to 1/3 of total mucosa depth	Total mucosa
Hemorrhage	Focal	Mild	Severe
Inflammation	Light	Mild	Severe
Apoptosis	Light	Mild	Severe

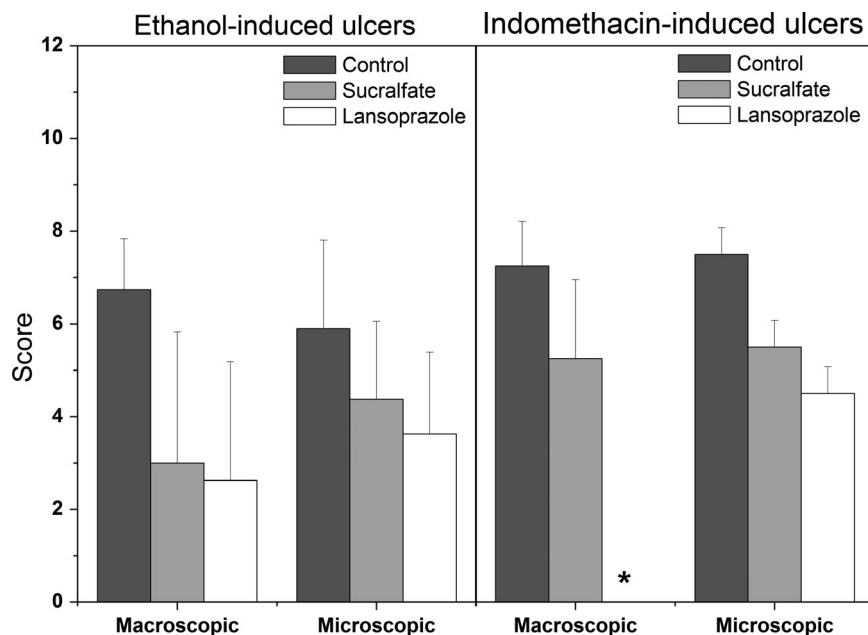
The macroscopic evaluation score was based in gastric mucosa hemorrhage. The sum of the scores for the different parameters allows calculation of the total macroscopic score, with a maximum possible of 8. The microscopic evaluation score was based in histological analysis. The sum of the scores for the different parameters allows calculation of the total microscopic score, with a maximum possible of 12.

sucralfate still presented some regions of hyperemia (Figure 3A2 and B2).

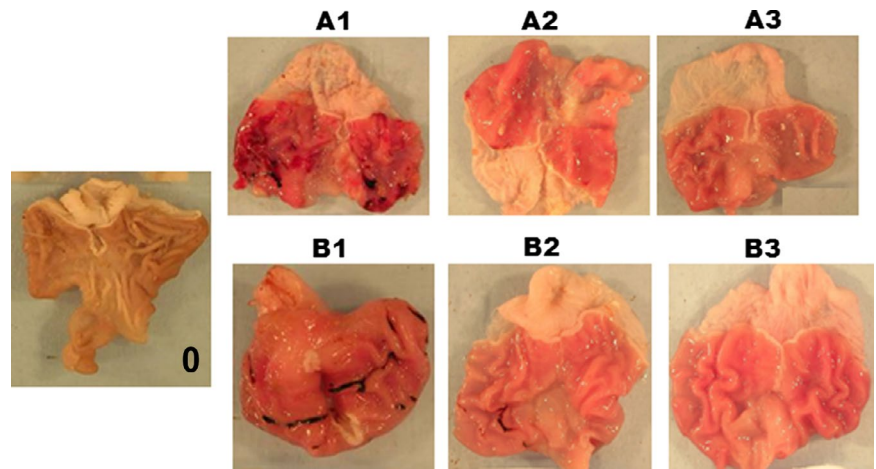
Considering the microscopic scores in both models of ulcer induction, a reduction in the total score was observed for both lansoprazole- and sucralfate-treated animals. Macro- and microscopic scores were comparable in the case of sucralfate but were different in the case of lansoprazole. Macroscopically, the administration of lansoprazole dramatically reduced the lesions observed. Microscopically, the damage was significantly reduced (Figure 4) but not to the same extent as observed macroscopically.

Both macroscopic and microscopic parameters are important tools in understanding the cellular processes in both models (indomethacin and ethanol). At the macroscopic level, both models present total scores calculated from similar partial evaluation scores (size, number, and site of hemorrhagic lesions) (Figure 4A). However, microscopic observations showed that ethanol resulted in more extensive hemorrhage and indomethacin in greater inflammation (Figure 4B).

When testing the anti-ulcerative drugs, macroscopically, a reduction in gastric lesions was observed (Figures 3A1-A3, B1-B3, and 5), particularly with lansoprazole. Microscopically, the anti-ulcerative

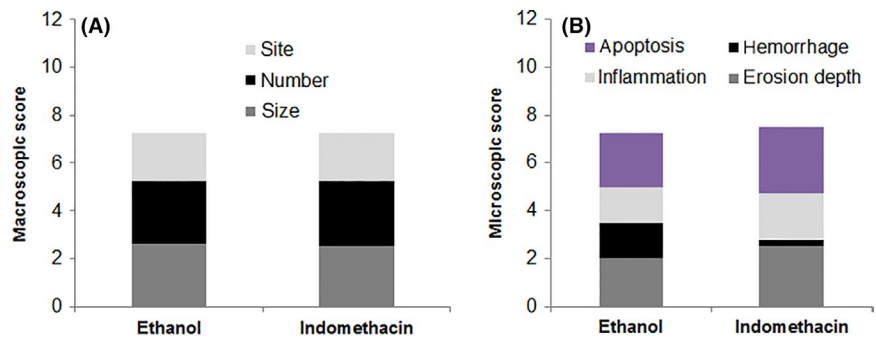
**FIGURE 2** Macroscopic and microscopic scores of ethanol- and indomethacin-induced gastric ulcers in control animals (induced non-treated animals; dark grey bars), animals treated with sucralfate (light grey bars) and animals treated with lansoprazole (white bars).

\*Animals treated with lansoprazole and induced with indomethacin presented macroscopic lesions scored as zero

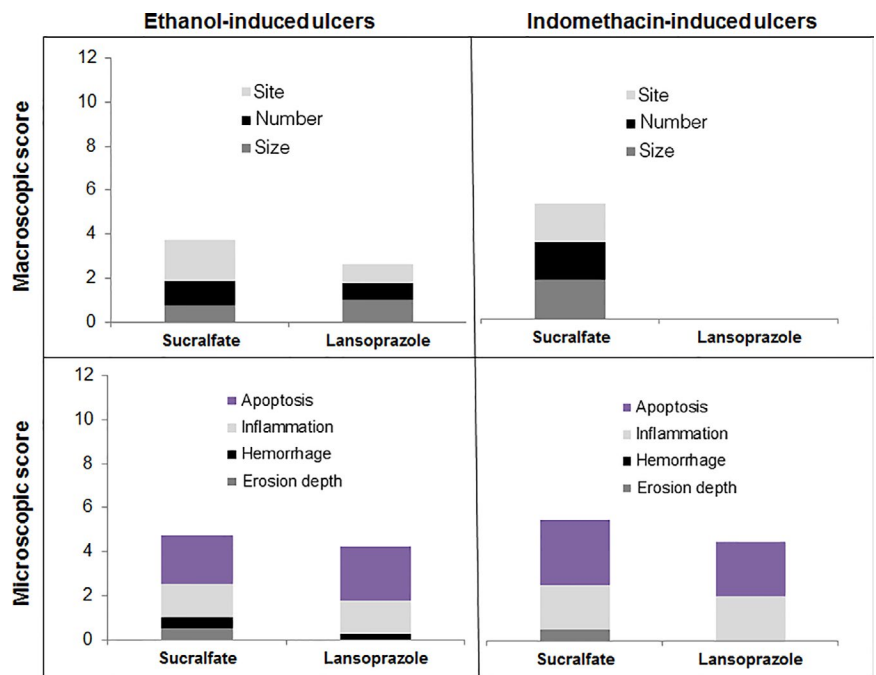


**FIGURE 3** Representative images of stomachs from experimental groups. Left panel, Negative control group (0). A1-A3, Ethanol-induced group (A1), sucralfate-treated ethanol-induced group (A2), and lansoprazole-treated ethanol-induced group (A3). B1-B3, Indomethacin-induced group (B1), sucralfate-treated indomethacin-induced group (B2) and lansoprazole-treated indomethacin-induced group (B3)

**FIGURE 4** A, Macroscopic score comprising the parameters evaluated (site, number, and size) for ethanol- and indomethacin-induced animals; B, Microscopic score comprising the parameters evaluated (erosion depth, hemorrhage, inflammation, and apoptosis) for ethanol- and indomethacin-induced animals



**FIGURE 5** Macroscopic and microscopic scores comprising the parameters evaluated for ethanol- and indomethacin-induced animals; Experimental groups: sucralfate- and lansoprazole-treated animals



drugs significantly reduced the depth of mucosal erosion and hemorrhage in both animal models (Figure 5).

Lansoprazole is a proton pump inhibitor which inhibits the production and secretion of acid into the gastric lumen, and its potential harmful action is normally neutralized by gastric mucosal protection mechanisms. In the ethanol-induced ulceration model, this protective mucosal barrier is probably damaged and the exposed mucosa

is vulnerable to the harmful action of the acid, preventing the healing and regeneration of the damaged tissues and enlarging the already formed lesions. The action of lansoprazole is dependent on its absorption by the body and subsequent action at the level of the proton pump in the gastric mucosa. This process certainly does not occur in time for lansoprazole to exert an anti-ulcer action in the ethanol induction model, in which ulceration is achieved in only 1 hour.

The ulcerative process is thus sometimes preponderant, leading to highly variable results.

The anti-ulcer action of lansoprazole is independent of acid production and secretion. Lansoprazole induces mucosal protection through gastrin receptor-dependent up-regulation of cyclooxygenase-2 in rats.<sup>12</sup> In this work, lansoprazole granules were dissolved in 8.4% sodium bicarbonate, a common vehicle used to suspend and solubilize this drug.<sup>12</sup> The administration of sodium bicarbonate can to some extent exert a neutralizing action, increasing the effect of lansoprazole on the mucosa.

The administration of sucralfate did not prevent the macroscopic effects induced by ethanol. In contact with the acidic environment of the stomach, sucralfate dissociates to form sucrose sulfate ions, which bind to the existing proteins in the injured mucosa. In our study, the animals were fasted for 24 hours before each test and the fasting period may have caused some gastric lesions, allowing the proteins exposed to bind to the sucralfate. Other mucosal areas may not be damaged by the fasting period, and these areas may stay vulnerable to the action of ethanol. When sucralfate is administered, a sucrose-protein-sulfate complex can form that is resistant to peptidic hydrolysis and indifferent to the action of HCl, bile acids, and salts. However, it is not known whether this complex is resistant to the absolute ethanol volume administered, and part of the protective system produced by sucralfate may be destroyed.

## 4 | CONCLUSIONS

Development of strategies to treat and prevent gastric ulcers is dependent on creating models that mimic physiologic lesions. Each model provides an opportunity to create reproducible levels of injury, and different models should be complementarily considered to investigate and treat acute gastric mucosal lesions. Microscopic evaluation is a valuable tool to complement the macroscopic evaluation of induced ulcers in rats. The score system presented in this work for the quantitative evaluation of biochemical and immunological parameters should be considered when exploring new therapeutic entities with potential anti-ulcerative activity.

## ACKNOWLEDGEMENTS

This work was partially funded by Agência de Inovação through the project XILOGASTRO/AdI/2003, FAIR through the project FAIR-PI97 3811, JABA Recordati, Fundação para a Ciência e Tecnologia (FCT, Portugal) through UID/DTP/04138/2013.

## CONFLICT OF INTEREST

None.

## AUTHOR CONTRIBUTIONS

LC, MEM da C, and MJM developed the study concept and the study design. LC, RL, SS, and MCDC performed the experiments and data

collection. RL, SS, and MCDC performed the data analysis and interpretation under the supervision of LC, MEM da C, and MJM. SS and LC drafted the manuscript and the final version. MEM da C, MJM, and MCDC provided critical revisions. All authors approved the final version of the manuscript for submission.

## ORCID

Sandra Simões  <https://orcid.org/0000-0002-5685-1790>

## REFERENCES

1. Chung KT, Shelat VG. Perforated peptic ulcer - an update. *World J Gastrointest Surg.* 2017;9:1-12.
2. Laine L, Takeuchi K, Tarnawski A. Gastric mucosal defense and cytoprotection: bench to bedside. *Gastroenterology.* 2008;135:41-60.
3. Groenen MJ, Kuipers EJ, Hansen BE, Ouwendijk RJ. Incidence of duodenal ulcers and gastric ulcers in a Western population: back to where it started. *Can J Gastroenterol.* 2009;23:604-608.
4. Mota KS, Dias GE, Pinto ME, et al. Flavonoids with gastroprotective activity. *Molecules.* 2009;14:979-1012.
5. Liang J, Dou Y, Wu X, et al. Prophylactic efficacy of patchoulene epoxide against ethanol-induced gastric ulcer in rats: influence on oxidative stress, inflammation and apoptosis. *Chem Biol Interact.* 2018;283:30-37.
6. Gürbüz I, Akyüz C, Yeşilada E, Sener B. Anti-ulcerogenic effect of *Momordica charantia* L. fruits on various ulcer models in rats. *J Ethnopharmacol.* 2000;71:77-82.
7. Ligumsky M, Sestieri M, Okon E, Ginsburg I. Antioxidants inhibit ethanol-induced gastric injury in the rat. Role of manganese, glycine, and carotene. *Scand J Gastroenterol.* 1995;30:854-860.
8. Cheng CL, Koo MW. Effects of *Centella asiatica* on ethanol induced gastric mucosal lesions in rats. *Life Sci.* 2000;67:2647-2653.
9. Pannangpetch P, Vuttivirojana A, Kularbkaew C, Tesana S, Kongyingoes B, Kukongviriyapan V. The antiulcerative effect of Thai Musa species in rats. *Phytother Res.* 2001;15:407-410.
10. Vonkeman HE, van de Laar MA. Nonsteroidal anti-inflammatory drugs: adverse effects and their prevention. *Semin Arthritis Rheum.* 2010;39:294-312.
11. Blandizzi C, Fornai M, Colucci R, et al. Lansoprazole prevents experimental gastric injury induced by non-steroidal anti-inflammatory drugs through a reduction of mucosal oxidative damage. *World J Gastroenterol.* 2005;11:4052-4060.
12. Morrison JT, Lugo RA, Thigpen JC, Brown SD. Stability of extemporaneously prepared lansoprazole suspension at two temperatures. *J Pediatr Pharmacol Ther.* 2013;18:122-127.

## SUPPORTING INFORMATION

Additional supporting information may be found online in the Supporting Information section at the end of the article.

**How to cite this article:** Simões S, Lopes R, Campos MCD, Marruz MJ, da Cruz MEM, Corvo L. Animal models of acute gastric mucosal injury: Macroscopic and microscopic evaluation. *Animal Model Exp Med.* 2019;2:121-126. <https://doi.org/10.1002/ame2.12060>