

Familial colloid cyst of the third ventricle[☆]

Luke J. Weisbrod^a, Kyle A. Smith^{b,*}, Roukoz B. Chamoun^b

^a School of Medicine, University of Kansas Medical Center, Kansas City, KS, USA

^b Department of Neurosurgery, University of Kansas Medical Center, Kansas City, KS, USA



ARTICLE INFO

Keywords:

Familial
Colloid cyst
Third ventricle

ABSTRACT

Colloid cysts of the third ventricle are rare benign lesions. They can present as incidental finding on imaging or with symptoms of obstructive hydrocephalus. To date, 18 familial cases of colloid cyst have been reported. Due to the extreme rarity of these cysts, it has been suggested that there is a genetic component involved. This report presents a familial colloid cyst in non-twin brothers who both presented in their early twenties. In addition, both of them had congenital inguinal hernia. This may represent a potential association between familial colloid cysts and congenital inguinal hernia that could provide us with insight into the genetic mechanism involved.

1. Background

Colloid cysts of the third ventricle are rare, benign, slow-growing intra-cranial cysts. They are primarily located just posterior to the foramen of Monro in the anterior aspect of the third ventricle, originating from the roof of the ventricle [1]. Colloid cysts are considered to be a developmental malformation, rather than neoplasm, and are histologically composed of a fibrous outer layer, internally bordered by a ciliated or mucus-producing epithelium of endodermal origin [2,3]. Colloid cysts can present as either an incidental finding on imaging or with symptoms of obstructive hydrocephalus, due to obstruction of the foramen of Monro as the cyst expands in size [4]. Obstruction typically follows several years of indolent growth, leading to non-specific symptoms of headache and nausea, but can be acute, possibly leading to coma and sudden death [1]. We present a case of familial colloid cysts in non-twin brothers.

2. Case report

Our patient is a 41 year-old male who was diagnosed with a colloid cyst when he was 30 years old. At that time, he complained of headache and dizziness. His magnetic resonance imaging of the head revealed a 10 mm colloid cyst and no hydrocephalus. The cyst was initially

followed with serial imaging. He presented to us after he started complaining of constant headaches, increased fatigue and sleepiness. There was an increase in size of the cyst on imaging, so he underwent surgical resection of the cyst. His brother had colloid cyst that was removed at the age of 27, with symptoms reported by patient of headache and hydrocephalus. Interestingly, the patient had inguinal hernia repair within 1st year of birth in 1976, and subsequent repair in 2011. His brother had a congenital inguinal hernia as well. His mother had umbilical hernia repair in her early 20s (Figs. 1 and 2).

3. Discussion

Colloid cysts are extremely rare, accounting for 0.5%–2% of all intracranial tumors and 15–20% of intra-ventricular neoplasms [5]. In a previous case report, the probability of colloid cysts occurring within two or more family members was calculated as 1×10^{10} or 1 in 10,000,000,000 [4]. This calculation implies there is likely a genetic component involved in colloid cysts, rather than statistical chance of co-occurrence in first-degree relatives. The genetic mechanism involved in the development of familial colloid cysts and the mode-of-inheritance remain unknown. The literature surrounding this topic currently exists only in cases reports and is purely speculative.

Several intra-cranial anomalies have been described in association

[☆] We declare that this manuscript is original, has not been published before and is not currently being considered for publication elsewhere.

We know of no conflicts of interest associated with this publication, and there are no financial disclosures concerning the materials or methods used in this study or the findings specified in this paper that could have influenced its outcome. As Corresponding Author, I confirm that the manuscript has been read and approved for submission by all the named authors.

We received no financial support and have no industrial affiliation.

* Corresponding author at: University of Kansas Medical Center, Department of Neurosurgery, 3901 Rainbow Blvd, Delp 5080, Mailstop 3021, Kansas City, KS 66160, USA.

E-mail address: ksmith9@kumc.edu (K.A. Smith).

<https://doi.org/10.1016/j.inat.2018.09.001>

Received 11 February 2018; Received in revised form 4 August 2018; Accepted 3 September 2018

2214-7519/© 2018 The Authors. Published by Elsevier B.V. This is an open access article under the CC BY-NC-ND license (<http://creativecommons.org/licenses/by-nc-nd/4.0/>).

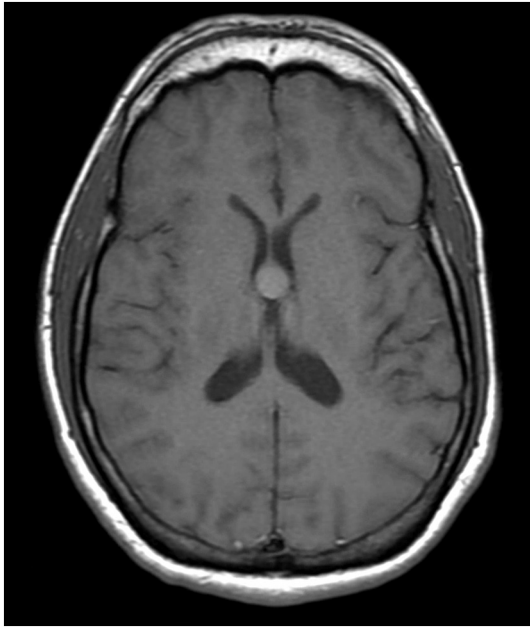


Fig. 1. MRI colloid cyst - axial T1 sequence.

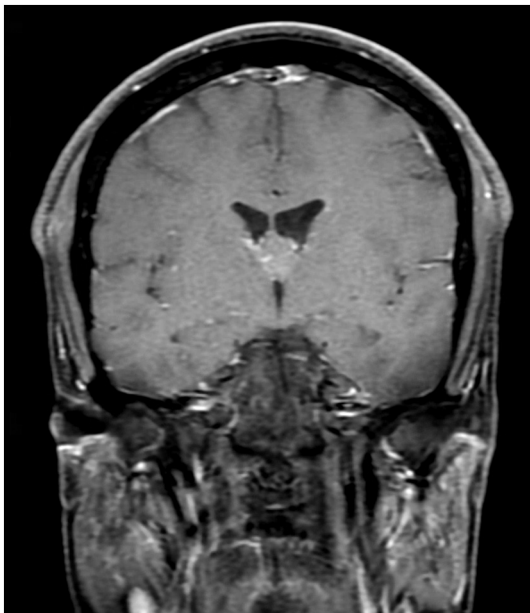


Fig. 2. MRI colloid cyst - coronal T1 sequence.

with colloid cysts, including xanthogranuloma [6,7], astrocytoma [8] and arteriovenous malformation [9], any of which could provide further insight into the pathophysiology of colloid cyst development. Our case presents an extra-cranial association between colloid cyst and congenital inguinal hernia.

Inguinal hernia is a common condition in childhood. In some cases however, inguinal hernia can be a presenting feature of an underlying genetic condition. Online Mendelian Inheritance in Man lists 49 genetic syndromes associated with umbilical and inguinal hernia [10]. Several of these genetic syndromes have been postulated to be directly related to disorders of the microfibril or elastin, such as Marfan syndrome [11] and Menkes disease [12] respectively, which could lead to abnormal connective tissue within the inguinal canal. Interestingly, there also exists chromosomal disorders, single gene defects and genetic syndromes, where the etiology of hernia is unknown, including 22q11.2 microdeletion syndrome [10,13].

The association between colloid cyst and inguinal hernia might simply be due to chance, relating to the fairly high incidence of inguinal hernia in childhood. However, it might also provide us with insight into the potential genetic mechanism of familial colloid cysts. The genetic mechanism might be due to a shared genetic or hormonal factor involved in sexual development or could reside on one of the shared chromosomes or genes with a currently established association with inguinal hernia, despite the unknown etiology behind the genetic mechanism.

References

- [1] L.A. Benoit, et al., Familial colloid cyst, *J. Clin. Neurosci.* 21 (3) (2014) 533–535.
- [2] P. Charalampaki, et al., Endoscope-assisted removal of colloid cysts of the third ventricle, *Neurosurg. Rev.* 29 (1) (2006) 72–79.
- [3] T. Yoshimine, et al., Colloid cysts of the third ventricle—a case report and 350 cases in previous publications (author's transl), *Neurol. Med. Chir. (Tokyo)* 20 (10) (1980) 1029–1038.
- [4] A. Aggarwal, A. Corbett, J. Graham, Familial colloid cyst of the third ventricle, *J. Clin. Neurosci.* 6 (6) (1999) 520–522.
- [5] J. Hernesniemi, et al., Microsurgical treatment of third ventricular colloid cysts by interhemispheric far lateral transcallosal approach—experience of 134 patients, *Surg. Neurol.* 69 (5) (2008) 447–453 (discussion 453–6).
- [6] M.G. Hadfield, N.R. Ghatak, G.P. Wanger, Xanthogranulomatous colloid cyst of the third ventricle, *Acta Neuropathol.* 66 (4) (1985) 343–346.
- [7] T. Matsushima, et al., Mixed colloid cyst-xanthogranuloma of the third ventricle. A light and electron microscopic study, *Surg. Neurol.* 24 (4) (1985) 457–462.
- [8] M. Gelabert, et al., Coincidence of a frontal lobe astrocytoma and colloid cyst of the third ventricle, *Neurochirurgia (Stuttg)* 34 (2) (1991) 69–70.
- [9] H.R. Niknejad, et al., Huge familial colloid cyst of the third ventricle: an extraordinary presentation, *Surg. Neurol. Int.* 6 (Suppl. 11) (2015) S349–S353.
- [10] C. Barnett, et al., Looking past the lump: genetic aspects of inguinal hernia in children, *J. Pediatr. Surg.* 44 (7) (2009) 1423–1431.
- [11] R.E. Pyeritz, V.A. McKusick, The Marfan syndrome: diagnosis and management, *N. Engl. J. Med.* 300 (14) (1979) 772–777.
- [12] S.A. Mandelstam, R. Fisher, Menkes disease: a rare cause of bilateral inguinal hernias, *Australas. Radiol.* 49 (2) (2005) 192–195.
- [13] S. Oskarsdottir, et al., Presenting phenotype in 100 children with the 22q11 deletion syndrome, *Eur. J. Pediatr.* 164 (3) (2005) 146–153.