



## Original article

# The retrospective study of 93 patients with transmigration of mandibular canine and a comparative analysis with a control group

Paweł Plakwicz<sup>1</sup>, Joanna Abramczyk<sup>2</sup>, Julita Wojtaszek-Lis<sup>3</sup>,  
Jolanta Sajkowska<sup>4</sup>, Barbara Warych<sup>5</sup>, Katarzyna Gawron<sup>6</sup>,  
Tomasz Burzykowski<sup>7,8</sup>, Małgorzata Zadurska<sup>2</sup>,  
Ewa Monika Czochołowska<sup>2</sup>, Andrzej Wojtowicz<sup>9</sup>,  
Renata Górńska<sup>1</sup> and Krzysztof Kukuła<sup>9</sup>

Departments of <sup>1</sup>Periodontology and <sup>2</sup>Orthodontics, Medical University of Warsaw, <sup>3</sup>Private Practice, Warsaw, <sup>4</sup>Private Practice, Giszczko, <sup>5</sup>Private Practice, Wrocław, <sup>6</sup>Department of Microbiology, Faculty of Biochemistry, Biophysics and Biotechnology, Jagiellonian University, Krakow, Poland, <sup>7</sup>Interuniversity Institute for Biostatistics and Statistical Bioinformatics (I-BioStat), Hasselt University, Belgium, and <sup>8</sup>Department of Statistics and Medical Informatics, Faculty of Health Sciences, Medical University of Białystok, Poland and <sup>9</sup>Department of Oral Surgery, Medical University of Warsaw, Poland

Correspondence to: Krzysztof Kukuła, Department of Oral Surgery, Medical University of Warsaw, ul. Nowogrodzka 59, 02-006 Warsaw, Poland. E-mail: [kkukula@gazeta.pl](mailto:kkukula@gazeta.pl)

## Summary

**Objectives:** The aim of this study was to evaluate characteristics of patients with unilateral transmigration of a mandibular canine in the largest study group presented until now.

**Materials and methods:** The study group consisted of 93 patients with unilateral transmigration of mandibular canine; the control group included 85 non-affected patients. Type of transmigration, status of deciduous and permanent canines, prevalence of missing teeth, class of occlusion, and space conditions were assessed to draw comparisons between groups.

**Results:** In this study, 64.5 per cent patients presented type 1 of transmigration; types 2, 3, 4, and 5 were present in, respectively, 23.7, 5.4, 4.3, and 2.1 per cent patients. There was a clear, statistically significant difference ( $P < 0.0001$ ) between the mean crown and apex migration and angulation for the three groups of canines (transmigrated, contralateral, and control), whereas no differences were observed for the total number of permanent teeth present. In the study group, 73.1 per cent patients retained their primary canine on the affected side and 18.3 per cent on the contralateral side; in the control group, 22.3 per cent subjects had at least one primary canine. There was a statistically significant difference in the distribution of types of malocclusion between the study and the control groups.

**Conclusions:** Transmigration of mandibular canine was associated with the presence of retained primary canine on the affected side, higher mesial tilting of contralateral mandibular canine when compared to the canines in the control group. Additionally, higher prevalence of Angle's Class I occlusion in patients with canine transmigration was recorded.

## Introduction

Transmigration of mandibular canine is a spontaneous pre-eruptive migration of permanent canine across the midline of the mandible. This rare phenomenon was first described by Ando in 1964 (1); few subsequent studies reported the incidence of this condition at between 0.1 and 0.3 per cent (2–10). Exceptionally, bilateral transmigration may also take place (11). The patterns of transmigration were described by Mupparapu and colleagues (6, 8). Clinical and radiological findings (the condition is routinely detected on orthopantomograms) are sufficient for initial diagnosis. Treatment of transmigration includes orthodontic forced eruption, observation, extraction, or transalveolar canine autotransplantation. The indications for treatment depend on patient's age and occlusion, stage of canine's root development, position of the canine, and the relationship between canine and adjacent teeth. So far, no protocol has been established for canine transmigration management, which could be routinely applied.

This study describes clinical and radiographic findings from a cohort of 93 patients with unilateral transmigration of mandibular canine to compare similar data from 85 control patients.

## Objectives of the study

The primary aim of the study was to examine differences between affected and contralateral sides in patients with unilateral transmigration of mandibular canine.

The secondary aim was to compare data from the study group with the control group (not affected with transmigration) to investigate whether there are any differences between oral findings.

An additional objective was to investigate the effect of age of affected patients on the position of transmigrated canine and the distance of migration.

## Material and methods

Between 2005 and 2017, 104 Caucasian patients with transmigration of permanent mandibular canine presented at five orthodontic practices, two oral surgery practices, and two university departments. The exclusion criteria were as follows: missing clinical data or low-quality radiographs, including positioning errors caused by inappropriate position of the head during X-ray examination (nine patients), bilateral transmigration of mandibular canines (two patients), general conditions that could influence bone metabolism or teeth eruption, and syndromes (none). After exclusion, 93 non-syndromic patients were included in the study group.

The control group consisted of 85 Caucasian orthodontic patients not affected with transmigration who met the same exclusion criteria. The patients in the control group were matched in terms of age and gender distribution for comparisons with the study group (such as Angle's classification, dental stages, and number of teeth).

Records of all patients consisted of high-quality and properly performed orthopantomograms (OPGs), intra-oral photographs, plaster models, and dental records.

The ethical committee approved the study (AKBE/86/14).

## Radiological examination

Transmigration of canine was diagnosed on OPG when at least a part of the crown of migrated canine has passed behind the mandibular midline to the contralateral side. The first OPG revealing transmigration served for analysis in the case when several OPGs (from different periods) of the same patient were available.

The types of transmigration were recorded based on classification proposed by Mupparapu (6) and are presented in Table 1. Two examiners (PP and KK) diagnosed and classified types of transmigration and performed all measurements. The first evaluation was performed separately. After 4 weeks, both examiners performed a second evaluation simultaneously. The type, position, and values of measurements were recorded after agreement.

The position of mandibular canines was assessed in relation to three vertical lines, a single horizontal line, and twin oblique lines, which were traced and superimposed on OPGs to detect any deviations from the normal position. The lines were as follows:

1. Mandibular midline (ML): a vertical line between approximal surfaces of mandibular central incisors (Figure 1a–c)
2. Canine lines (CL): twin vertical lines in the centre of the spaces between lateral incisors and first premolars (or first primary molars) on affected and contralateral sides (Figure 1a and b)
3. A horizontal line (HL): at the level of apices of mandibular incisors (Figure 1a)
4. Twin angulation lines (AL): drawn along the long axis of affected and contralateral canines (Figure 1c)

The distance of canine's crown migration (CM) was calculated in relation to the CL with the accuracy to the half of the width of the tooth located above the canine's crown. This type of measurement allowed descriptive presentation of migration without measurement bias (different magnifications related to various manufacturers of digital OPG machines), which could be present if measurements were performed in millimetres. Therefore, the minimal recorded CM (representing the mildest transmigration) was 3.0. It corresponded to the position of the tip of the canine's crown below the mid-portion of the central incisor on the contralateral side (Figure 1b). Similar measurements were taken for the position of the contralateral canines. The values for contralateral canines could be positive or negative depending on whether the crown was tilted forwards or backwards in relation to the CL.

Additionally, CL served to calculate migration of apices of mandibular canines. The distance of apex migration (AM) was calculated from CL (for affected and contralateral canines) also with the same accuracy, as for CM. Values of AM could be negative or positive. Positive values represented AM from appropriate CL towards midline. Negative values represented distal migration towards the roots of premolars (Figure 1b). A similar method was used to assess migration of crowns and apices of mandibular canines in the control group.

The measurements in relation to the HL were taken only in the study group in relation to the transmigrated canine. Two types of position were recognized: below the HL and above the HL (i.e. superimposing the roots of mandibular incisors; Figure 1a).

AL served to measure angulation of the affected and contralateral canines. The angulation (A) between AL and ML was measured and recorded for transmigrated and contralateral canines (Figure 1c). Similar measurements were taken for canines in the control group.

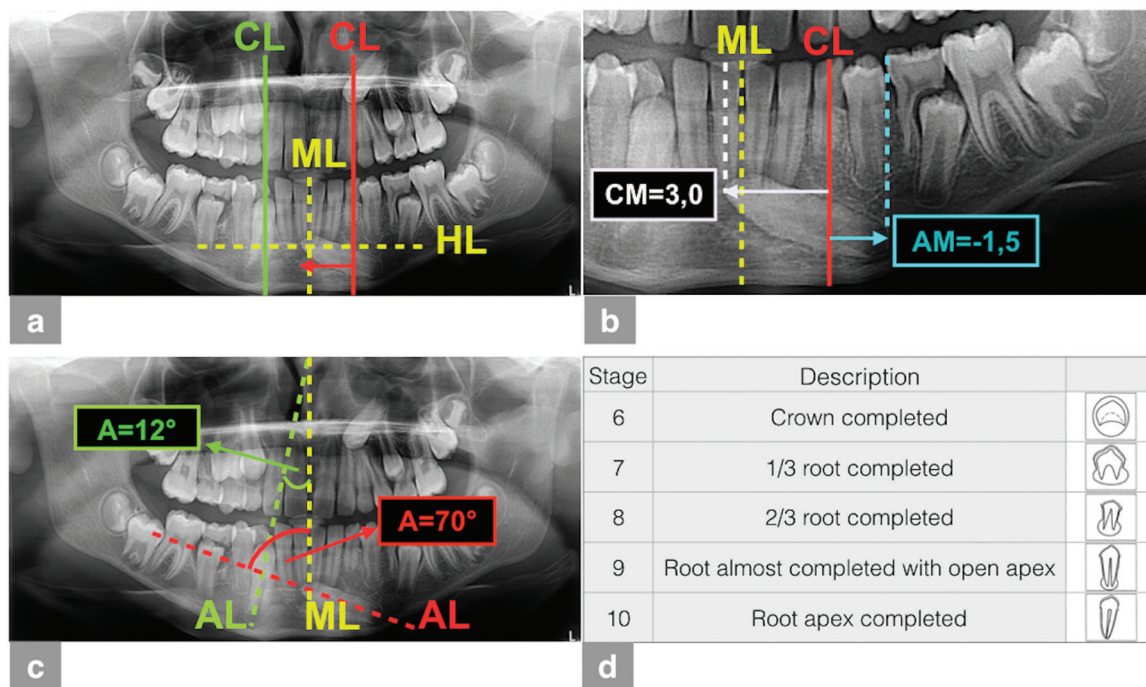
The presence of primary canines, other impacted canines, and assessment of development of roots of mandibular canines were also analysed.

Root development was assessed using classification proposed by Nolla (12) (Figure 1d). The canine's radiographic image was compared to Nolla's scheme and graded 6, 7, 8, 9, or 10, respectively.

OPGs served to record missing teeth (particularly maxillary lateral incisors and mandibular premolars). Because of the age of patients or lack of information regarding previous removal of third molars, these

**Table 1.** Types of transmigration and their distribution in relation to the age category. The first column describes types of transmigration according to the classification proposed by Mupparapu. The following columns describe the total number of particular types in the study group (column 2) and the detailed (and the percentages in parentheses) distribution of each type of transmission in the age groups (columns from 3 to 6). The last row shows the distribution of age in the control group of patients

Types of transmigration/age category		Age <11 (years)	Age 11–12.5 (years)	Age 12.5–15.5 (years)	Age >15.5 (years)
Study group	Total (n = 93)	(n = 25)	(n = 26)	(n = 22)	(n = 20)
Type 1: the canine is positioned mesio-angularly across the midline	60 (64.5%)	18 (72%)	18 (69.2%)	13 (59.1%)	11 (55%)
Type 2: the canine is located horizontally near the inferior border of the mandible below apices of the incisors	22 (23.7%)	7 (28%)	4 (15.4%)	6 (27.3%)	5 (25%)
Type 3: the canine is erupted either mesially or distally to the contralateral canine	5 (5.4%)	0	2 (7.7%)	3 (13.6%)	0
Type 4: the canine is positioned horizontally near the inferior border of the mandible below apices of either contralateral premolars or molars	4 (4.3%)	0	0	0	4 (20%)
Type 5: the canine is located vertically in the midline irrespective of its eruption status	2 (2.1%)	0	2 (7.7%)	0	0
Control group without transmigration of mandibular canine	Total (n = 85)	n = 27 (31.8%)	n = 16 (18.8%)	n = 21 (24.7%)	n = 21 (24.7%)



**Figure 1.** Methods of radiological assessment presented on an example of a patient's X-ray. An orthopantomogram (OPG) of a 12-year-old male patient with transmigration of mandibular left canine (tooth 33) presents vertical and horizontal lines established for evaluation of canines' position. Canine line (CL) of transmigrated canine is marked with red continuous line. CL of contralateral canine is marked with green continuous line. Mandibular midline (ML) and horizontal line (HL) are marked with yellow intermittent lines (a). The cropped OPG (from panel a) showing the measurement of distance of crown migration (CM) and apex migration (AM) in relation to CL on the affected side. CM = 3.0 (marked with a white arrow) corresponds to a distance of width of three teeth towards the midline (marked with white intermittent line in the mid-portion of the central incisor on the contralateral side). AM = -1.5 (marked with a blue arrow) corresponds to a distance of 1.5 width of a tooth backwards (marked with a blue intermittent line behind the distal surface of the first premolar) (b). Presentation of twin oblique lines established for the evaluation of canines' angulation in relation to the midline (ML, marked in yellow). Angulation line (AL) of transmigrated canine and adequate angulation value (A) in degrees are marked in red. AL of contralateral canine and adequate angulation value (A) is marked in green (c). Description and schematic drawings illustrating stages of development of permanent mandibular canine's root as proposed by Nolla (d).

teeth were excluded from the assessment. According to results from a previous study (13), hypodontia of permanent premolars was considered positive only in patients who were older than 11 years, when no mineralization of premolars' crown was detected on OPG.

Additionally, OPGs could reveal the presence of cysts, odontomas, and supernumerary teeth.

### Clinical examination

The records included the presence of primary canines on the affected, contralateral or control side, missing teeth, and morphology of erupted teeth. In the case when permanent teeth were missing during clinical examination, the presence/absence of unerupted teeth was confirmed on radiographs. Space conditions (no space deficiency or teeth crowding), ML shift in relation to maxillary midline, and Angle's classification were assessed in the study and in the control group.

### Statistical analysis

Contingency tables were used to describe the distribution of categorical responses between the compared groups. Differences in observed distributions were compared by (the exact, in the case of low counts) Pearson's chi-square test. Distributions of continuous responses were described using the sample mean and standard deviation. Differences in the observed distributions of continuous responses were analysed using a general linear model for correlated data (14) that included the age category, tooth location (33 or 43), and the group indicator (affected, contralateral, or control). The model was adjusted for the possible correlation between responses obtained for teeth from the same individual. The fit of the model to the data was evaluated with standardized (Pearson) residuals. Results of statistical significance tests were evaluated at 0.05 significance level (two-sided). No multiple-testing adjustment was applied. The analyses were conducted with SAS, version 9.4, and STATA, version 13.1, software.

## Results

A total of 29 male and 64 female patients were included in the study group (male to female ratio, 1:2.2). The control group consisted of 24 male and 61 female (ratio 1:2.5) patients. Unilateral transmigrating of 50 right (13 in male and 37 in female patients) and 43 left (16 in male and 27 in female patients) permanent mandibular canines was diagnosed on OPGs.

The mean age of patients in the study and the control groups was equalled to 14.4 years (SD = 6.9 years, range from 7.6 to 49.5 years) and 14 years (SD = 4.9 years, range from 8 to 35 years), respectively. In the analyses, four age categories (Table 1) were used to investigate the impact of age on selected parameters. The cut-offs were selected to obtain an approximately balanced distribution of the categories.

### Types of transmigration

The distribution of the types of transmigration showed statistically significant difference (exact Pearson's chi-square test,  $P = 0.03$ ) among the four age groups (Table 1).

### Position of canines

The CM ranged from 3.0 (the mildest transmigration) to 7.5 width of the tooth (the most advanced type 4 transmigration). Most canines (70 per cent) presented mild transmigration in types 1 and 3. There were 30 per cent severely transmigrated canines in types 2 and 4.

The sample means of CM for transmigrated, contralateral, and control canines are given in Table 2. The model-based analysis indicated that there was a clear, statistically significant difference ( $P < 0.0001$ ) between the mean CM for the three groups of canines (transmigrated, contralateral, and control) after adjustment for the effect of age and tooth location (33 or 43). In particular, the mean CM for contralateral canines (in the study group) was similar to the mean CM in the control group ( $P = 0.09$ ), but the mean CM for the transmigrated canines was estimated to be larger by about 3.9 ( $P < 0.0001$ ). The effects of age and tooth location were not statistically significant ( $P = 0.58$  and  $0.12$ , respectively).

The sample means of AM for transmigrated, contralateral, and control canines are given in Table 2. The model-based analysis indicated that there was a clear, statistically significant difference ( $P < 0.0001$ ) between the mean AM for the three groups of teeth (transmigrated, contralateral, and control) after adjustment for the effect of age and tooth location. In particular, the mean AM for contralateral canines in the study group was estimated to be smaller by about 0.24 than the mean AM in the control group ( $P = 0.01$ ), and the mean AM for the transmigrated canines was estimated to be smaller by about 0.52 ( $P < 0.0001$ ). The effect of tooth location was not statistically significant ( $P = 0.19$ ), whereas the effect of age was statistically significant ( $P = 0.003$ ). In general, the mean AM increased with age.

The sample means of angulation (A) for transmigrated, contralateral, and control canines are given in Table 2. The model-based analysis indicated that there was a clear, statistically significant difference ( $P < 0.0001$ ) between the mean A for the three groups of teeth. In particular, the mean angle for contralateral canines was estimated to be larger by about 5.8 than the mean angle for control canines ( $P = 0.002$ ). The mean angle for the transmigrated canines was estimated to be larger by about 62.8 ( $P < 0.0001$ ). The effect of tooth location (33 versus 43) was not statistically significant ( $P = 0.06$ ), whereas the effect of age was statistically significant ( $P = 0.002$ ). In general, the mean A decreased with age.

The number (and proportion) of patients, who had primary canines and root development of permanent canines, are given in Table 2. Generally, the transmigrated canines had earlier stages of root development than the canines from the control group (exact Pearson's chi-square test,  $P = 0.02$  and  $<0.0001$  for the affected canine 33 and 43, respectively).

A descriptive statistics for impaction of other canines, upper (in the affected, contralateral, and control group) and lower (in the contralateral and control group), are presented in Table 2.

None of transmigrated canines caused (neither diagnosed on radiograph nor reported during the surgery) root resorption of adjacent teeth or formation of a follicular cyst.

Sixty-seven (72 per cent) patients had crowns of transmigrated canines located above HL, i.e. superimposing the apical part of roots of mandibular incisors; however, no resorption of incisors' roots was detected on radiographs. Seven canines (7.5 per cent in types 3 and 5) erupted spontaneously in transmigrated/contralateral positions, all of them labially to the incisors and/or contralateral canines.

### Tooth agenesis

In the control group, 72 patients (84.7 per cent) had a normal number of teeth. In the study group, 82 patients (88.2 per cent) had a normal number of teeth; the difference, as compared to the control group, is statistically not significant ( $P = 0.50$  for Pearson's chi-square test). Nine patients (9.7 per cent) in the study group lacked maxillary lateral incisors, whereas seven patients (7.5 per cent) had



missing lower second premolars. A more detailed account of findings regarding the number of teeth is given in Table 3.

### Orthodontic findings

Teeth crowding, midline shift, and Angle's classification are given in Table 3.

There was no statistically significant difference in the presence of crowding between the study and the control groups ( $P = 0.33$  and  $0.54$  for Pearson's chi-square test for the mandible and maxilla, respectively). There was a statistically significant association ( $P < 0.0001$  for Pearson's chi-square test) between the direction of the midline shift (left, none, and right) and subject's status (control, study with affected left side, and study with affected right side).

Most patients in the study group, and all in the control group, demonstrated the same Angle's classification on both sides. There was a statistically significant difference in the distribution of Angle's classes for the affected canines on both sides (33 or 43), depending on whether the canine was transmigrated, contralateral to the transmigrated one, or present in a control subject ( $P = 0.001$  and  $0.002$  for Pearson's chi-square test for canine 33 and 43, respectively). The difference was mainly due to the difference in the distribution of the classes for teeth contralateral to transmigrated ones in affected patients and the corresponding teeth in control subjects ( $P = 0.005$  and  $0.001$  for Pearson's chi-square test for canine 33 and 43, respectively). In particular, the proportion of Class I in control subjects (41.2 per cent for both canine 33 and 43) was substantially lower than the proportion of Class I contralateral to transmigrated

**Table 2.** Descriptive statistics for position (mean crown and apex migration in tooth width, mean angulation in degrees) and development (presence of a primary canine) and grades of development (according to Nolla) of mandibular canines. Additionally, the number of patients diagnosed with impaction of the other canine is given in the last row. Inferential statistics ( $P$  values) discussed in the text. SD, standard deviation; CM, crown migration; AM, apex migration; A, angulation.

Variables from the radiological examination	Affected side in the study group		Contralateral side in the study group		Control group (sides left and right)	
	33	SD	43	SD	33	SD
Crown migration (mean value)	CM = 3.8 CM = 4.0	1.01 1.04	CM = 0.19 CM = 0.16	0.43 0.45	CM = 0.02 CM = 0.06	0.22 0.18
Apex migration (mean value)	AM = -0.62 AM = -0.88	1.12 1.15	AM = -0.41 AM = -0.53	0.47 0.57	AM = -0.19 AM = -0.28	0.53 0.48
Angulation (mean value)	A = 63.6° A = 70.1°	19.1 18.7	A = 9.5° A = 10.7°	11.4 14.7	A = 3.7° A = 5.3°	9.5 8.7
Number of patients with primary canines	68 (73.1%), including 16 patients bilaterally		17 (18.3%), including 16 patients bilaterally		19 (22.3%), including 14 patients bilaterally	
Grades of root development according to Nolla	7 ( $n = 0$ ) 8 ( $n = 32$ ) 9 ( $n = 22$ ) 10 ( $n = 39$ )		7 ( $n = 0$ ) 8 ( $n = 24$ ) 9 ( $n = 24$ ) 10 ( $n = 45$ )		7 ( $n = 18$ ) 8 ( $n = 34$ ) 9 ( $n = 14$ ) 10 ( $n = 104$ )	
Number of the impaction of other canines	2 upper unilateral 4 upper bilateral		9 lower 3 upper unilateral 4 upper bilateral		1 lower 6 upper unilateral 2 upper bilateral	

**Table 3.** Descriptive statistics for clinical findings from the examination of the three groups/sides; side affected with transmigration and contralateral side in the study group and both right and left sides in the control group of patients. Inferential statistics ( $P$  values) discussed in the text

Variables from the clinical examination	Affected side in the study group	Contralateral side in the study group	Control group (sides left and right)
Peg-shaped maxillary lateral incisors	3 unilateral 2 bilateral	3 unilateral 2 bilateral	3 bilateral
Agenesis of maxillary lateral incisors	2 unilateral 3 bilateral	4 unilateral 3 bilateral	3 bilateral
Agenesis of mandibular premolars	1 unilateral 5 bilateral	1 unilateral 5 bilateral	2 bilateral
Crowding of teeth	32 patients (34.4%) in the maxilla 36 patients (38.7%) in the mandible (including 26 patients with crowding in both arches) 51 patients (54.8%) had no crowding		33 patients (38.8%) in the maxilla 27 patients (31.8%) in the mandible (including 19 patients with crowding in both arches) 44 patients (51.8%) had no crowding
Midline shift	50 patients (53.8%) to affected 15 patients (16.1%) to contralateral 28 patients had no midline shift		43 patients had midline shift to the right or left side
Angle's classification	Class I 66 (71%) Class II 25 (26.9%) Class III 2 (2.1%)	Class I 68 (73.1%) Class II 23 (24.7%) Class III 2 (2.1%)	Class I 35 (41.2%) Class II 47 (55.3%) Class III 3 (3.5%)

ones in affected patients (70 and 76.7 per cent for canine 33 and 43, respectively).

## Discussion

Studies on transmigration of a mandibular canine are very inconsistent because the majority of published reports presents isolated cases, or case series, and very few studies investigated a large number of patients (5, 6, 15, 16). In this study, 93 patients with unilateral mandibular canine transmigration were examined, which seems to be the largest and the most homogenous group described so far. There are various definitions of transmigration, which depend on the extent of migration of the affected tooth across the midline (5, 6, 17). The comparisons with the control group of patients allowed us to answer questions that could not be answered through other study designs.

In this study, the male to female ratio (1:2.5) was higher than that reported by Peck (1:1.6) (18).

Type 1 transmigration was significantly more often diagnosed, and types 3–5 were presented at significantly lower incidence when compared to a previous study (6). This indicates that the majority of patients examined here had milder transmigration in comparison with other studies. Interestingly, type 4 transmigration was diagnosed exclusively in patients older than 15.5 years, whereas type 2 was revealed in younger patients. This may indicate that type 4 is a continuation of type 2 transmigration. Type 4 transmigration seems to be a logical consequence of continuing movement of canine in type 2. Unfortunately, a limited number of cases and the inability to observe the same patients at different ages do not make a certain conclusion.

Angulation of canines in the study group was statistically significantly higher than in the control group, which was expected, but interestingly, the contralateral canines in the study group also presented a statistically significantly higher angulation when compared to the control canines.

There were nine impacted mandibular canines in the contralateral group. Incidentally, only one patient in the control group had an impacted mandibular canine. There was similar prevalence of upper canine impaction in three groups.

The presence of primary canines in the study group was higher when compared to previous studies; (5) however, the information regarding primary teeth in the cited study, was not always provided.

None of transmigrated canines caused (neither diagnosed on radiograph nor reported during the surgery) root resorption of adjacent teeth; however, the resorption of the buccal or lingual surface of the teeth could not be ruled out. Only three-dimensional X-ray examination (for example cone beam computed tomography) could provide adequate information about the status of surface of adjacent teeth.

In this study, there was no pathology associated with transmigrated canines. Several studies reported odontomas or dentigerous cysts as associated anomalies (5, 17, 19), but no explanation regarding the aetiology of transmigration was given (6). The larger volume of the body of anterior mandible when compared to maxilla can indicate why transmigration of a canine is almost exclusively found in the mandible (7).

Crowding of mandibular teeth was not statistically significantly associated with transmigration, which is at variance with the findings of Shapira and Kuftinec (20). According to one limited case series, Class II malocclusion with deep bite and increased lower anterior face height was suggested as a predisposing factor in the aetiology of transmigration (21). This assertion was not supported in this

study because the majority of patients with canine transmigration had Angle's Class I occlusion.

The position of transmigrated canine in relation to mandibular incisors seems to be the most important factor determining potential risk of complications. In the study group, few affected canines presented types 2 and 4 of transmigration, which may usually require only observation as a treatment of choice (if no pathology accompanies the affected canine and if this is in agreement with the orthodontic treatment plan). According to Frank (22), the clinical and radiographic examination is recommended every 18–24 months during postimpaction observation period. In this article, the majority of patients were diagnosed with a canine that was superimposed on the apical part of the roots of mandibular incisors (types 1, 3, and 5). In these cases, careful evaluation of individual treatment options is required. According to the results of other studies, most patients are treated with surgical removal of transmigrated canine (20, 23). In mild cases of transmigration, surgical exposure of the canine, followed by forced orthodontic eruption, may be attempted depending on the initial position of canine, orthodontic indications, and the potential risk to anterior teeth (23, 24). Autotransplantation may be an option when the impaction pattern prevents orthodontic traction. The alveolar bone growth accompanying the eruption of the autotransplanted developing canine and normal healing were described previously (25, 26). However, cases are reported when autotransplantation of mature teeth to recipient sites with osseous defect has not resulted in regeneration of bone (27).

This study has several strengths. It examined a large number of unilateral cases of transmigrated canines, which enhanced statistical power to examine differences between affected and contralateral sides. Additionally, comparisons, which were made with the control group, allowed finding out some differences between the contralateral canines in the study group and canines in the control patients. The study introduces a two-dimensional model, which allows one to determine the position of transmigrated canine. The measurements are based on OPGs, which are still the primary method to assess jaws in growing patients before orthodontic treatment. Only high-quality OPGs (regarding both position of the patient and graphic quality) were used for evaluation. There could be some magnification of different OPGs, but it was always symmetrical, because only symmetrical X-rays were included in the study. The same rule applied to the measurement of angulation.

The measurements of the distance of CM and AM were performed with the accuracy to the half of the width of the tooth unit (and not in millimetres). This kind of presentation of the migration is the most descriptive and limits the measurement error the most. This model can be applied to make comparisons with other studies in the future. Moreover, it may help to introduce criteria or threshold values for clinical guidelines of treatment.

## Conclusions

Transmigration of a mandibular canine was associated with the presence of retained primary canine on the affected side, higher mesial tilting of contralateral mandibular canine when compared to the canines in the control group. There was a clear, statistically significant difference ( $P < 0.0001$ ) between the mean CM and AM and angulation for the three groups of canines (transmigrated, contralateral, and control), whereas no differences were observed for the total number of permanent teeth present. Additionally, higher prevalence of Angle's Class I occlusion in patients with canine transmigration was recorded.

Within the limitation of the study, no other oral findings seemed to be associated with or prognostic in relation to mandibular canine transmigration. These findings suggest that the screening of patients at the age of 7–9 years seems to be the only diagnostic tool to detect an abnormal path of canine eruption.

## Conflict of interest

None declared.

## References

- Ando, S., Aizawa, K., Nakashima, T., Sanka, Y., Shimbo, K. and Kiyokawa, K. (1964) Transmigration process of the impacted mandibular cuspid. *Journal of Nihon University School of Dentistry*, 6, 66–71.
- Tarsitano, J.J., Wooten, J.W. and Burditt, J.T. (1971) Transmigration of nonerupted mandibular canines: report of cases. *Journal of the American Dental Association* (1939), 82, 1395–1397.
- Joshi, M.R. and Shetye, S.B. (1994) Transmigration of mandibular canines: a review of the literature and report of two cases. *Quintessence International (Berlin, Germany: 1985)*, 25, 291–294.
- Andreasen, J.O., Petersen, K.J. and Laskin, D.M. (eds) (1997) *Textbook and Color Atlas of Tooth Impactions: Diagnosis, Treatment, Prevention*. Munksgaard, Copenhagen, Denmark, 1st edn, pp. 168.
- Joshi, M.R. (2001) Transmigrant mandibular canines: a record of 28 cases and a retrospective review of the literature. *Angle Orthodontist*, 71, 12–22.
- Mupparapu, M. (2002) Patterns of intra-osseous transmigration and ectopic eruption of mandibular canines: review of literature and report of nine additional cases. *Dento Maxillo Facial Radiology*, 31, 355–360.
- Aydin, U., Yilmaz, H.H. and Yildirim, D. (2004) Incidence of canine impaction and transmigration in a patient population. *Dento Maxillo Facial Radiology*, 33, 164–169.
- Mupparapu, M., Auluck, A., Suhaz, S., Pai, K.M. and Nagpal, A. (2007) Patterns of intraosseous transmigration and ectopic eruption of bilaterally transmigrating mandibular canines: radiographic study and proposed classification. *Quintessence International (Berlin, Germany: 1985)*, 38, 821–828.
- Celikoglu, M., Kamak, H. and Oktay, H. (2010) Investigation of transmigrated and impacted maxillary and mandibular canine teeth in an orthodontic patient population. *Journal of Oral and Maxillofacial Surgery*, 68, 1001–1006.
- Aktan, A.M., Kara, S., Akgünlü, F. and Malkoç, S. (2010) The incidence of canine transmigration and tooth impaction in a Turkish subpopulation. *European Journal of Orthodontics*, 32, 575–581.
- Joshi, M.R., Daruwala, N.R. and Ahuja, H.C. (1982) Bilateral transmigration of mandibular canines. *British Journal of Orthodontics*, 9, 57–58.
- Nolla, C.M. (1960) The development of permanent teeth. *Journal of Dentistry for Children*, 27, 254–266.
- Wisth, P.J., Thunold, K. and Bøe, O.E. (1974) Frequency of hypodontia in relation to tooth size and dental arch width. *Acta Odontologica Scandinavica*, 32, 201–206.
- Galecki, A. and Burzykowski, T. (2013) *Linear Mixed Effects Models Using R: A Step-by-Step Approach*. Springer, New York.
- Kara, M.I., Ay, S., Aktan, A.M., Sener, I., Bereket, C., Ezirganli, S. and Demirkol, M. (2011) Analysis of different type of transmigrant mandibular teeth. *Medicina Oral, Patologia Oral Y Cirugia Bucal*, 16, e335–e340.
- Dalessandri, D., Parrini, S., Rubiano, R., Gallone, D. and Migliorati, M. (2017) Impacted and transmigrant mandibular canines incidence, aetiology, and treatment: a systematic review. *European Journal of Orthodontics*, 39, 161–169.
- Javid, B. (1985) Transmigration of impacted mandibular cuspids. *International Journal of Oral Surgery*, 14, 547–549.
- Peck, S. (1998) On the phenomenon of intraosseous migration of nonerupting teeth. *American Journal of Orthodontics and Dentofacial Orthopedics*, 113, 515–517.
- al-Waheidi, E.M. (1996) Transmigration of unerupted mandibular canines: a literature review and a report of five cases. *Quintessence International (Berlin, Germany: 1985)*, 27, 27–31.
- Shapira, Y. and Kuftinec, M.M. (2003) Intrabony migration of impacted teeth. *Angle Orthodontist*, 73, 738–743; discussion 744.
- Holla, A., Saify, M. and Parashar, S. (2012) Transmigration of impacted mandibular canines and its association with malocclusion and morphology: an analysis of seven cases. *Orthodontics: The Art and Practice of Dentofacial Enhancement*, 13, 156–165.
- Frank, C.A. (2000) Treatment options for impacted teeth. *Journal of the American Dental Association* (1939), 131, 623–632.
- Mazinis, E., Zafeiriadis, A., Karathanasis, A. and Lambrianidis, T. (2012) Transmigration of impacted canines: prevalence, management and implications on tooth structure and pulp vitality of adjacent teeth. *Clinical Oral Investigations*, 16, 625–632.
- Wertz, R.A. (1994) Treatment of transmigrated mandibular canines. *American Journal of Orthodontics and Dentofacial Orthopedics*, 106, 419–427.
- Paulsen, H.U. and Andreasen, J.O. (1998) Eruption of premolars subsequent to autotransplantation. A longitudinal radiographic study. *European Journal of Orthodontics*, 20, 45–55.
- Plakwicz, P., Wojtaszek, J. and Zadurska, M. (2013) New bone formation at the site of autotransplanted developing mandibular canines: a case report. *International Journal of Periodontics & Restorative Dentistry*, 33, 13–20.
- Imazato, S. and Fukunishi, K. (2004) Potential efficacy of GTR and autogenous bone graft for autotransplantation to recipient sites with osseous defects: evaluation by re-entry procedure. *Dental Traumatology*, 20, 42–47.