



Successful treatment of *Trichosporon asahii* fungemia with isavuconazole in a patient with hematologic malignancies

Guillaume Feugray, Daphne Krzisch, Marion Dehais, Romy Razakandrainibe, Gilles Gargala, Loïc Favennec, Stéphane Leprêtre, Vincent Camus, Damien Costa

► To cite this version:

Guillaume Feugray, Daphne Krzisch, Marion Dehais, Romy Razakandrainibe, Gilles Gargala, et al.. Successful treatment of *Trichosporon asahii* fungemia with isavuconazole in a patient with hematologic malignancies. *Infection and Drug Resistance*, Dove Medical Press, 2019, 12, pp.2015-2018. 10.2147/IDR.S211148 . hal-02316531

HAL Id: hal-02316531

<https://hal-normandie-univ.archives-ouvertes.fr/hal-02316531>

Submitted on 15 Oct 2019

HAL is a multi-disciplinary open access archive for the deposit and dissemination of scientific research documents, whether they are published or not. The documents may come from teaching and research institutions in France or abroad, or from public or private research centers.

L'archive ouverte pluridisciplinaire **HAL**, est destinée au dépôt et à la diffusion de documents scientifiques de niveau recherche, publiés ou non, émanant des établissements d'enseignement et de recherche français ou étrangers, des laboratoires publics ou privés.

Successful treatment of *Trichosporon asahii* fungemia with isavuconazole in a patient with hematologic malignancies

This article was published in the following Dove Press journal:
Infection and Drug Resistance

Guillaume Feugray¹
Daphné Krzisch²
Marion Dehais¹
Romy Razakandrainibe³
Gilles Gargala^{1,3}
Loïc Favennec^{1,3}
Stéphane Lepretre²
Vincent Camus²
Damien Costa^{1,3}

¹Department of Parasitology/Mycology, Rouen University Hospital, Rouen, France; ²Department of Hematology, Centre Henri Becquerel, Normandie Univ UNIROUEN, Inserm U1245, Rouen, France; ³Department of Parasitology/Mycology, University of Medicine Pharmacy Rouen EA ESCAPE 7510, Rouen, France

Abstract: *Trichosporon* spp. are yeast-like microorganisms responsible for skin, urinary, pulmonary, or bloodstream infections. Due to intrinsic resistance to echinocandins, poor susceptibility to polyenes, and preferred occurrence in immunocompromised patients, such infections are often of poor prognosis. Yet no consensual therapeutic guidelines are presently available. Several clinical cases of *Trichosporon* infections have been successfully treated with azole therapy, including voriconazole which appeared frequently effective against *Trichosporon* both in vitro and in vivo. However, the low efficacy associated with some *Trichosporon* genotypes, complex pharmacokinetics, and the side effects of voriconazole represent limitations for its use and has prompted a search for other therapeutic options. Here, we report a case of *T. asahii* fungemia in a patient with B-cell acute lymphoblastic leukemia which was successfully treated with isavuconazole consecutive to stopping voriconazole therapy due to severe side effects. This observation suggests that isavuconazole with a similar spectrum to voriconazole, fewer pharmacology interactions, and side effects may be considered as a valuable therapeutic option against *Trichosporon* infections.

Keywords: fungemia, *Trichosporon asahii*, isavuconazole, acute lymphoid leukemia

Case

Trichosporon species are a common cause of fungemia after *Candida* species in patients with hematologic malignancies. Among all species, *Trichosporon asahii* is the most frequently implicated. Several fatal cases of *Trichosporon asahii* infections have been reported, and early use of an appropriate antifungal appears essential for survival. While *Trichosporon* spp. exhibits intrinsic resistance to echinocandins and amphotericin B, azoles appear to be the most constantly effective agents, and voriconazole has been successfully used in clinical cases although no well-documented consensus guidelines are presently available.¹⁻³ Here, we report a case of a *T. asahii* infection which was successfully treated with isavuconazole in a patient suffering from hematologic malignancies.

A 66-year-old man of 76 kg was hospitalized in June 2018 with a recurrence of acute lymphoid leukemia. This patient was initially diagnosed with an IgG-kappa type multiple myeloma in 2008. Treatment was based on bortezomib-dexamethasone in association with dorso-lumbar D9-L1 radiotherapy and melphalan[®] 200 autologous stem cell transplant followed by 33 cycles of lenalidomide maintenance therapy (IFM-2005 clinical trial). Complete remission of myeloma was obtained with this scheme. In March 2015, an acute biphenotypic monosomy 7 and FLT3

Correspondence: Damien Costa; Loïc Favennec
Normandie Univ, UNIROUEN, EA 7510, Rouen University Hospital, Department of Parasitology, IBC 3rd Floor, 1 rue de Germont, Rouen 76000, France
Tel +33 23 286 4175; +33 23 288 0115
Fax +33 23 288 6875; +33 23 288 6875
Email damien.costa@chu-rouen.fr;
Loic.favennec@chu-rouen.fr

negative leukemia was diagnosed and treated by chemotherapy. In February 2018, magnetic resonance imaging revealed hemochromatosis following multiple transfusions. In June 2018, the patient had pancytopenia and a diagnosis of acute pro-B lymphoblastic leukemia was established. The patient was treated with blinatumomab, a bi-specific anti-CD3 and anti-CD19 monoclonal antibody. Due to febrile neutropenia, a large spectrum of antibiotics was initiated on June 26th, 2018. Empiric caspofungin therapy was started on July 6th due to prolonged febrile neutropenia with suspicion of invasive fungal infection. However, fungemia occurred on July 13th. *T. asahii* was identified by mass spectrometry (maldi biotyper, Bruker) from blood culture. At this date, on July 13th, the patient had leucopenia (0.3 G/L). Minimal inhibitory concentrations (MICs) for *T. asahii* isolates were determined by E test (Table 1). On July 18th, based on obtained MICs, a combined voriconazole (IV: 6 mg/kg every 12 hrs for 1 day and then, 4 mg/kg every 12 hrs) + amphotericin B therapy (Ambisome: liposomal form 3 mg/kg/day) was started and blinatumomab therapy was stopped. Consecutively to stopping blinatumomab therapy, leucocyte concentration gradually increased from: 0.3 G/L, 2 G/L (polymorphonuclear neutrophils: 1.5 G/L), 2.8 G/L (polymorphonuclear neutrophils: 2.2 G/L), 4.5–5 G/L and finally 10.3 G/L on July 18th, August 1st, August 3rd, August 7th to 16th and August 20th, respectively. Two days consecutively to voriconazole introduction, on July 20th, voriconazole plasma concentration was 4.9 µg/mL, increasing to 6.5 µg/mL on July 26th (N: 1–5µg/mL). Consecutively to this dosage and due to neurological adverse effects, voriconazole dose was decreased from 4 mg/kg to 2 mg/kg every 12 hrs. Four days later, on July

30th voriconazole plasma concentration was within the normal range at 1.1 µg/mL (N: 1–5 µg/ml). On August 1st, the patient had grade III neurological toxicity with persistent invalidating hallucinations and voriconazole therapy was discontinued. Within two days of liposomal amphotericin B monotherapy, erythematous skin lesions appeared on the patient's right thigh and disseminated in a few days (biopsy confirmed *T. asahii* infection) even with leucocyte concentrations ranging between 2.8 and 5 G/L. On August 13th, based on MIC results, isavuconazole (IV 200 mg twice a day) was added to liposomal amphotericin B therapy. Two days later, the infection declined with regression of skin lesions and culture-negative results. Isavuconazole (IV) was then used at 200 mg a day for 2 weeks and then, orally at the same dose for 3 months (Figure 1). Finally, the fungemia was successfully treated with an isavuconazole-based therapy. Eleven months later (to date with the current report), the patient is still in complete remission from his underlying pathology.

In this reported case, we observed both the inefficacy of amphotericin B-based therapy and successful treatment with isavuconazole. Immune restoration probably potentiated the efficacy of isavuconazole. However, it is difficult to attribute recovery to immune restoration alone since the patient had leucocytes ranging from 4.5 to 5 G/L for 6 days before isavuconazole initiation and infection was out of control. In this patient, several previously identified conditions promoting *Trichosporon* infection were present. In the present case, immunodepression was associated with malignant hemopathies, and the additional role of anti-CD3 and anti-CD19 blinatumomab therapy for the treatment of acute lymphoid leukemia requires further investigation. Moreover, among

Table 1 Sequential susceptibilities of *Trichosporon asahii* isolates to antifungal agents. Susceptibilities were estimated based on *Candida albicans* EUCAST breakpoints version 9.0 and provided as “indicative” to clinicians in absence of available breakpoints

Tested antifungal agent	Isolate 1 ^a		Isolate 2 [#]	
	Minimal inhibitory concentrations (mg/L)	Susceptibility	Minimal inhibitory concentrations (mg/L)	Susceptibility
Amphotericin B	0.75	Susceptible	1.5	Intermediate
Voriconazole	0.023	Susceptible	0.023	Susceptible
Isavuconazole	0.023	Susceptible	0.047	Susceptible
Flucytosine	32	Resistant	32	Resistant
Anidulafungin	32	Resistant	32	Resistant
Itraconazole	0.5	Resistant	1.0	Resistant
Posaconazole	0.094	Resistant	0.094	Resistant

Notes: ^aIsolate 1 was obtained from blood culture 7 days after initiation of empiric caspofungin treatment (one month before isavuconazole therapy). Isolate 2 was obtained from cutaneous biopsy the day voriconazole therapy was stopped (12 days before isavuconazole therapy).

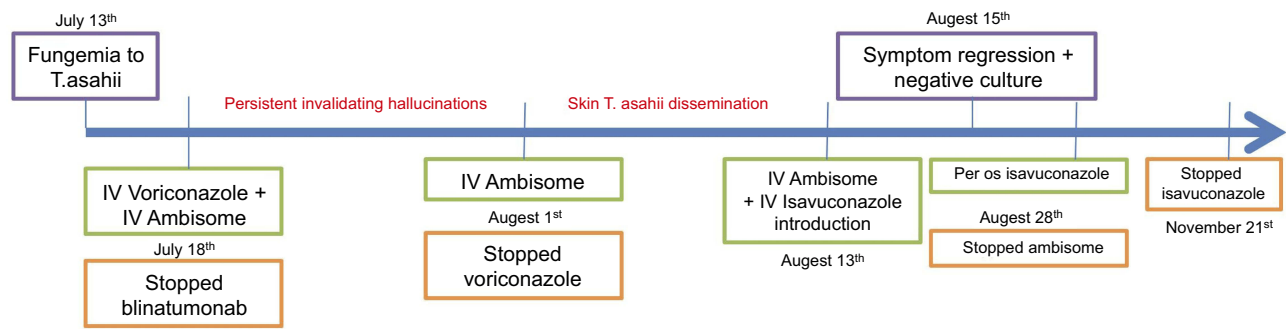


Figure 1 Case study timeline.

risk factors our patient presented hemochromatosis. Indeed, in 2010, Shih-Ta Shang et al described *Trichosporon* fungemia in an immunocompetent patient with hemochromatosis.⁴ They hypothesized that iron overload decreased T-cell immunity, natural killer cell, and neutrophil activities and monocyte phagocytosis. Additionally, our patient had a vascular catheter that was removed after *Trichosporon* infection diagnosis and was suspected as the source of fungemia.

No consensus guidelines are currently available for the treatment of *Trichosporon* infections even if voriconazole is presented as a preferred therapy.³ *Trichosporon* exhibits natural resistance to echinocandins and inconsistent sensitivity to amphotericin B according to species. The azole class of antifungals is the most efficient for the treatment of *Trichosporon* infections, and several cases of *Trichosporon* infection have been treated with voriconazole often associated with amphotericin B.² Voriconazole, however, may interact with several other pharmaceutical agents. In addition, high intra- and inter-individual pharmacokinetic variability is well established and can easily cause over- or underdosing. Consequently, many side effects of voriconazole therapy have been observed such as hallucinations which led to treatment discontinuation in our case. These side effects require a search for alternative therapeutic options. Isavuconazole has exhibited an excellent in vitro activity against *Trichosporon*.⁵ In the present clinical case, voriconazole, used in first intention with amphotericin B, was discontinued due to side effects. Isavuconazole administration resulted in improved skin lesions and finally fungemia was controlled in absence of side effects. This observation suggests that isavuconazole with fewer side effects and similar efficiency against *Trichosporon* spp. compared with voriconazole should be considered as a valuable alternative to voriconazole in *Trichosporon* infections.

Ethic statement

Written informed consent has been provided by the patient to have the case details published.

Transparency declaration

No institutional approval is required to publish the case details.

Acknowledgments

The authors are grateful to Nikki Sabourin-Gibbs, Rouen University Hospital, and JJ Ballet for their help in editing the manuscript. We are also grateful to laboratory technicians.

Author contributions

All authors contributed to data analysis, drafting or revising the article, gave final approval of the version to be published, and agree to be accountable for all aspects of the work.

Disclosure

Dr Vincent Camus report personal fees, non-financial support from ROCHE, personal fees, non-financial support from AMGEN, outside the submitted work. The authors report no other conflicts of interest in this work.

References

1. Karigane D, Sakurai M, Matsuyama E, et al. Successful treatment of breakthrough disseminated *Trichosporon asahii* fungemia in a patient with acute myeloid leukemia receiving itraconazole prophylaxis. *Med Mycol Case Rep.* 2018;20:1–3. doi:10.1016/j.mmcr.2017.11.006
2. Asada N, Uryu H, Koseki M, Takeuchi M, Komatsu M, Matsue K. Successful treatment of breakthrough *Trichosporon asahii* fungemia with voriconazole in a patient with acute myeloid leukemia. *Clin Infect Dis.* 2006;43(4):e39–e41. doi:10.1086/505970
3. Arendrup MC, Boekhout T, Akova M, Meis JF, Cornely OA, Lortholary O. ESCMID† and ECMM‡ joint clinical guidelines for the diagnosis and management of rare invasive yeast infections. *Clin Microbiol Infect.* 2014;20:76–98. doi:10.1111/1469-0691.12360

4. Shang S-T, Yang Y-S, Peng M-Y. Nosocomial *Trichosporon asahii* fungemia in a patient with secondary hemochromatosis: a rare case report. *J Microbiol Immunol Infect.* 2010;43(1):77–80. doi:10.1016/S1684-1182(10)60012-6
5. Thompson GR, Wiederhold NP, Sutton DA, Fothergill A, Patterson TF. In vitro activity of isavuconazole against *Trichosporon*, *Rhodotorula*, *Geotrichum*, *Saccharomyces* and *Pichia* species. *J Antimicrob Chemother.* 2009;64(1):79–83. doi:10.1093/jac/dkp138

Infection and Drug Resistance

Dovepress

Publish your work in this journal

Infection and Drug Resistance is an international, peer-reviewed open-access journal that focuses on the optimal treatment of infection (bacterial, fungal and viral) and the development and institution of preventive strategies to minimize the development and spread of resistance. The journal is specifically concerned with the epidemiology of

antibiotic resistance and the mechanisms of resistance development and diffusion in both hospitals and the community. The manuscript management system is completely online and includes a very quick and fair peer-review system, which is all easy to use. Visit <http://www.dovepress.com/testimonials.php> to read real quotes from published authors.

Submit your manuscript here: <https://www.dovepress.com/infection-and-drug-resistance-journal>