

The two FIGO systems for normal and abnormal uterine bleeding symptoms and classification of causes of abnormal uterine bleeding in the reproductive years: 2018 revisions

Malcolm G. Munro^{1,2,*} | Hilary O.D. Critchley³ | Ian S. Fraser⁴ | for the FIGO Menstrual Disorders Committee

¹Departments of Obstetrics and Gynecology, David Geffen School of Medicine at UCLA, University of California, Los Angeles, CA, USA

²Kaiser Permanente, Los Angeles Medical Center, Los Angeles, CA, USA

³MRC Centre for Reproductive Health, The University of Edinburgh, The Queen's Medical Research Institute, Edinburgh, UK

⁴School of Women's and Children's Health, Royal Hospital for Women, University of New South Wales, Randwick, NSW, Australia

*Correspondence

Malcolm G. Munro, Kaiser Permanente, Los Angeles Medical Center, Los Angeles, CA, USA.

Email: mmunro@ucla.edu

Participating Members of the FIGO Menstrual Disorders Committee, 2015–2018 are listed at the end of the paper.

Abstract

Background: The International Federation of Gynecology and Obstetrics (FIGO) systems for nomenclature of symptoms of normal and abnormal uterine bleeding (AUB) in the reproductive years (FIGO AUB System 1) and for classification of causes of AUB (FIGO AUB System 2; PALM-COEIN) were first published together in 2011. The purpose was to harmonize the definitions of normal and abnormal bleeding symptoms and to classify and subclassify underlying potential causes of AUB in the reproductive years to facilitate research, education, and clinical care. The systems were designed to be flexible and to be periodically reviewed and modified as appropriate.

Objectives: To review, clarify, and, where appropriate, revise the previously published systems.

Methodology and outcome: To a large extent, the process has been an iterative one involving the FIGO Menstrual Disorders Committee, as well as a number of invited contributions from epidemiologists, gynecologists, and other experts in the field from around the world between 2012 and 2017. Face-to-face meetings have been held in Rome, Vancouver, and Singapore, and have been augmented by a number of teleconferences and other communications designed to evaluate various aspects of the systems. Where substantial change was considered, anonymous voting, in some instances using a modified RAND Delphi technique, was utilized.

KEYWORDS

Abnormal uterine bleeding; Adenomyosis; Anovulatory bleeding; Arteriovenous malformation; Coagulopathy; Endometrial hyperplasia; Endometrial polyp; FIGO; Heavy menstrual bleeding; Heavy uterine bleeding; Intermenstrual bleeding; Irregular menstrual bleeding; Irregular uterine bleeding; Isthmocele; Leiomyoma; Menorrhagia; Metrorrhagia; PALM-COEIN

1 | INTRODUCTION

The worldwide impact of abnormal uterine bleeding (AUB) in the reproductive years is substantial, with a prevalence of approximately 3%–30% among reproductive aged women. The reasons for the wide spectrum of estimates are unclear but vary with age, being higher in adolescents and in the fifth decade of life, and varying somewhat with country of

origin.^{1–9} Approximately one third of women are affected at some time in their life.^{3,6} Many of the published studies are restricted to estimates of the prevalence of the symptoms of heavy menstrual bleeding (HMB); when other symptoms, particularly those of irregular and intermenstrual bleeding are included, the prevalence rises to 35% or higher.⁹

Available evidence suggests that as many as half of affected women do not seek medical care, even if they have access to a healthcare

provider,^{4,5,8} a circumstance that may explain the variation in reported prevalence. The manifestations vary from modest to severe disruption of work productivity and quality of life,^{10,11} and increasing maternal morbidity and mortality for pregnant women with pre-existing AUB-related anemia.^{12,13}

In 2011, recognizing the international need created by the impact of AUB, the International Federation of Gynecology and Obstetrics (FIGO), published a pair of systems and a set of clinical recommendations with the aim of informing and aiding clinicians and investigators in the design and interpretation of investigations into AUB in the reproductive years, as well as the provision of evidence-based clinical care.¹⁴

The present manuscript was designed to provide a detailed update on the FIGO recommendations concerning terminologies, definitions, and underlying causes of AUB in the reproductive years. Revised terminologies and definitions of normal menstrual parameters, and the symptoms of AUB were initially published in 2007,^{15,16} while the seminal 2011 publication¹⁴ presented both systems—Terminology and Definitions (FIGO-AUB System 1) and Classification of Causes of AUB in the Reproductive Years, the PALM-COEIN system (FIGO-AUB System 2). From the beginning, it was determined that these recommendations should be flexible and subject to ongoing regular review to incorporate results of new research and analysis. These review periods were intended to broadly coincide with the triennial FIGO World Congresses.

The first key recommendations, published simultaneously in 2007 in *Fertility Sterility and Human Reproduction*,^{15,16} recommended a substantial revision of existing terminologies and definitions for the description of AUB features and, by doing so, redefined the normal parameters of menstrual bleeding. Recommended was the abolition of terms (largely of Latin and Greek origin) such as menorrhagia, metrorrhagia, and dysfunctional uterine bleeding, which were poorly defined, used internationally in a disparate manner, and had no consistent meaning for the general and academic communities.¹⁵⁻¹⁷

The second key publication¹⁴ presented a novel and pragmatic approach to classification of the underlying causes of AUB in non-pregnant women. No such systematic classification of underlying causes existed at that time. This 2011 manuscript introduced the PALM-COEIN classification based on clinical- and imaging-based stratification of causes into “structural” pathologies that can be “imaged” and/or defined histopathologically (Polyps, Adenomyosis, Leiomyomas and Malignancy or atypical endometrial hyperplasia; PALM). The remaining causes were categorized as “non-structural”, in that they cannot be imaged, but clinical assessment with detailed history and appropriate physical examination, sometimes supported by laboratory testing, can largely imply or make a diagnosis of cause (Coagulopathies, Ovulatory disorders, primary Endometrial disorders, iatrogenic and Not otherwise classified; COEIN).

It rapidly became clear that each of these individual causes could require division into subclassifications of cause and phenotype to optimize clinical management and support the broad spectrum of research needed. The subclassification of leiomyomas was an obvious starting point.¹⁴ Three key publications¹⁴⁻¹⁷ formed the foundation of a simple, flexible, and educationally sound pair of descriptive systems that were designed to provide a quick initial clinical direction of diagnosis

and management, but also to be flexible enough to provide effective linkages with laboratory and research aspects.

The present report updates the FIGO recommendations for both FIGO-AUB Systems 1 and 2, including clarifications on terminologies and definitions, as well as modifications in the PALM-COEIN system that include reassignment of some entities, and guidance for subclassification of leiomyomas, much of which has been preliminarily published.¹⁸⁻²⁰ These changes represent structured deliberative processes that include use of a modified RAND Delphi process applied to the attendees of a series of FIGO Menstrual Disorders Committee (MDC) sponsored expert meetings. To allow this report to function independently, and to provide context, there exists substantial but necessary overlap with the original publication,¹⁴ and with other subsequent and related publications produced by the MDC since 2011.¹⁸⁻²⁴

The FIGO MDC is currently working on subclassification systems for adenomyosis and endometrial polyps. The adenomyosis subclassification system is the most advanced and will be published soon in preliminary form with planned validation studies to follow. The polyp system is being developed but a release date has not yet been determined. There is consideration for subclassification systems for AUB-C, -O, -E, and -I, but these initiatives are still in the very early stages of development.

It is important that clinicians recognize that these FIGO systems relate solely to assessment and management of nongestational AUB. There are other causes of genital tract bleeding and urinary tract or gastrointestinal bleeding that do not come from the uterus. These can usually be identified by an appropriate case history and physical examination.

2 | ACUTE VERSUS CHRONIC NONGESTATIONAL AUB IN THE REPRODUCTIVE YEARS

In the original system,¹⁴ FIGO introduced the concept of nongestational acute AUB in the reproductive years, distinguishing it from chronic AUB—an approach endorsed by the American College of Obstetricians and Gynecologists.²⁵ These definitions remain unchanged for 2018. Chronic nongestational AUB in the reproductive years is defined as bleeding from the uterine corpus that is abnormal in duration, volume, frequency, and/or regularity, and has been present for the majority of the preceding 6 months. Acute AUB, on the other hand, is defined as an episode of heavy bleeding that, in the opinion of the clinician, is of sufficient quantity to require immediate intervention to minimize or prevent further blood loss. Acute heavy menstrual bleeding may present in the context of existing chronic AUB or can occur in the absence of such a background history.

3 | FIGO-AUB SYSTEM 1

3.1 | Revision of terminologies and definitions of symptoms of abnormal uterine bleeding

The revised FIGO-AUB System 1 is seen in Figure 1, with changes summarized in Table 1. As determined by the multinational process

Parameter	Normal	Abnormal	<input checked="" type="checkbox"/>	
Frequency	Absent (no bleeding) = amenorrhea		<input type="checkbox"/>	
	Infrequent (>38 days)		<input type="checkbox"/>	
	Normal (≥24 to ≤38 days)		<input type="checkbox"/>	
	Frequent (<24 days)		<input type="checkbox"/>	
Duration	Normal (≤8 days)		<input type="checkbox"/>	
	Prolonged (>8 days)		<input type="checkbox"/>	
Regularity	Normal or "Regular" (shortest to longest cycle variation: ≤7-9 days)*		<input type="checkbox"/>	
	Irregular (shortest to longest cycle variation: ≥8-10 days)*		<input type="checkbox"/>	
Flow Volume (patient determined)	Light		<input type="checkbox"/>	
	Normal		<input type="checkbox"/>	
	Heavy		<input type="checkbox"/>	
Intermenstrual Bleeding (IMB) Bleeding between cyclically regular onset of menses	None		<input type="checkbox"/>	
	Random		<input type="checkbox"/>	
	Cyclic (Predictable)	Early Cycle		<input type="checkbox"/>
		Mid Cycle		<input type="checkbox"/>
Late Cycle		<input type="checkbox"/>		
Unscheduled Bleeding on Progestin ± Estrogen Gonadal Steroids (birth control pills, rings, patches or injections)	Not Applicable (not on gonadal steroid medication)		<input type="checkbox"/>	
	None (on gonadal steroid medication)		<input type="checkbox"/>	
	Present		<input type="checkbox"/>	

©Malcolm G. Munro MD

FIGURE 1 FIGO AUB System 1. Nomenclature and Definitions of AUB Symptoms. For 2018, intermenstrual bleeding has been added, and there is now a practical definition for irregular menstrual bleeding created by using the 75th percentile, effectively excluding the occasional long or short cycles experienced by many women. *The available evidence suggests that, using these criteria, the normal range (shortest to longest) varies with age: 18–25 y of age, ≤9 d; 26–41 y, ≤7 d; and for 42–45 y, ≤9 d Harlow et al., 2000.²⁷ For clinical purposes, the definition of HMB proposed by the UK National Institute for Health and Care Excellence has been adopted^{5,28} – “Excessive menstrual blood loss which interferes with a woman’s physical, social, emotional, and/or material quality of life”. Abbreviations: AUB, abnormal uterine bleeding; FIGO, International Federation of Gynecology and Obstetrics; HMB, heavy menstrual bleeding. [Correction added on 12 November 2018, after first online and print publication: Frequency parameter has been updated from ‘Infrequent (<24 days)’ to ‘Frequent (<24 days)’ and ‘Irregular’ modified to ‘≥8-10 days’.]

described in the original publications,^{14–16} terms such as menorrhagia, metrorrhagia, oligomenorrhea, and dysfunctional uterine bleeding have been abandoned. There is acknowledgement of the specific changes in menstrual bleeding patterns that may be encountered at each end of the reproductive spectrum (i.e. in adolescence or the peri-menopause).²⁶

Preparation of the present 2018 recommendations is the result of sequential reviews of the FIGO-AUB System 1 initially proposed in 2007 and 2009, and underwent slight modification for 2011. The current revisions represent deliberations in meetings held in 2012, 2015, and 2017. These reviews have included comment, detailed questioning, and recommendations from many clinicians from around the world but have only resulted in minor changes and refinement of definitions from the original system.

In this revision of FIGO AUB System 1, the definition of regularity has been changed from one where the shortest to longest variation is up to 20 days, to variation of 7–9 days, depending upon age

(18–25 years ≤9 days; 26–41 years ≤7 days; 42–45 years ≤9 days).²⁷ For practical purposes, this normal variation in cycle length can be alternatively expressed as ±4 days.

Formally included is the term HMB, a symptom (not a diagnosis), that has been defined (in clinical situations) by the National Institute for Health and Clinical Excellence as “excessive menstrual blood loss, which interferes with a woman’s physical, social, emotional and/or material quality of life”.^{5,28}

4 | FIGO AUB SYSTEM 2

4.1 | Revision of classification of underlying causes of AUB (PALM-COEIN)

Highlights of changes since the original publication in 2011¹⁴ are summarized in Table 2. The basic/core classification system is almost unchanged and is presented in Figure 2. There remain the nine main

TABLE 1 Summary of changes to FIGO System 1 (normal and abnormal uterine bleeding).

Parameter	Change
Frequency	Amenorrhea is now part of the frequency category
Regularity	Refined definition of regularity Normal variation (shortest to longest) 7-9 d Slight variance depends on age
Duration	Now only two categories for duration Normal: ≤8 d Prolonged: >8 d
Volume	Definition of the symptom of HMB NICE definition ^{5,28} Bleeding volume sufficient to interfere with the woman's quality of life
Intermenstrual bleeding	Definition of the symptom of inter-menstrual bleeding Spontaneous bleeding occurring between menstrual periods Can be either cyclical, or random

Abbreviations: FIGO, International Federation of Gynecology and Obstetrics; HMB, heavy menstrual bleeding; NICE, National Institute of Care Excellence.

categories, arranged according to the acronym PALM-COEIN (pronounced "palm-koin"): Polyp; Adenomyosis; Leiomyoma; Malignancy and hyperplasia; Coagulopathy; Ovulatory dysfunction; Endometrial disorders; Iatrogenic; and Not otherwise classified. Category N has undergone a change from "not yet classified" to "not otherwise classified" as we cannot be certain which, if any, of these entities will ultimately be placed in a unique category. The components of the PALM group are generally discrete (structural) entities that can be evaluated or measured visually using some combination of imaging techniques and histopathology; the COEIN group comprises entities that are not defined by imaging or histopathology (non-structural). By its nature, the "Not otherwise classified" category includes a spectrum of potential entities that may or may not be measured or defined by histopathology or imaging techniques.

The system has been constructed with the understanding that a given patient may have one or more entities that could cause or contribute to AUB symptoms and that structurally definable entities, such as adenomyosis, leiomyomas, and endocervical or endometrial polyps are often asymptomatic and, therefore, may not contribute to the presenting symptoms.

Since the original publication of the FIGO AUB systems,¹⁴ there have been advances in the diagnosis of adenomyosis, although its relationship to reproductive function and uterine bleeding is still under investigation. It has been demonstrated that two-dimensional transvaginal ultrasonography has similar sensitivity and specificity for the diagnosis of adenomyosis when compared to magnetic resonance imaging (MRI).^{29,30} There is some progress regarding the spectrum of two-dimensional ultrasonography findings associated with the

TABLE 2 Summary of changes to FIGO AUB System 2 Causes or Contributors to AUB in the Reproductive Years (PALM-COEIN).

System 2 category	Change
AUB-A	Refined sonographic diagnostic criteria
AUB-L	Inclusion of Type 3 as a submucous leiomyoma Type definitions and distinctions Distinction between Types 0 and 1; 6 and 7 Distinction between Types 2 and 3; 4 and 5
AUB-C	No longer includes AUB associated with pharmacologic agents that impair blood coagulation which are now included in AUB-I
AUB-I	Now includes AUB associated with all iatrogenic processes including the use of pharmacological agents used for anticoagulation and those thought to interfere with ovulation
AUB-O	Diagnostic threshold changes based upon the revisions of System 1, described above No longer includes ovulatory disorders associated with drugs known or suspected to interfere with ovulation
AUB-N	The name of the category has been changed from "Not Yet Classified" to Not Otherwise Classified There is a brief discussion of a potential new cause of AUB the so-called uterine "niche" or isthmocele following lower segment cesarean section

Abbreviations: AUB, abnormal uterine bleeding; FIGO, International Federation of Gynecology and Obstetrics.

diagnosis,^{31,32} but no consensus regarding how many and which of these findings are necessary before there is reasonable certainty that a diagnosis of adenomyosis is present. The eight criteria suggested by the morphological uterus sonographic assessment (MUSA) group are shown in Figure 3.³¹ The FIGO MDC is currently working on an international consensus for an imaging-based adenomyosis classification system designed to phenotype the disorder in a standardized fashion that should facilitate research, education, and clinical care. However, for diagnosis the use of the transvaginal ultrasonography-based MUSA criteria³¹ for the diagnosis of adenomyosis for the purposes of FIGO AUB System 2 is suggested.

The only subclassification system ratified so far is the leiomyoma subclassification system, essentially unchanged since the initial 2011 publication¹⁴ (Fig. 4). The only subtle difference is for Type 3 myomas, where contact with the endometrium is a feature shared by other submucous leiomyomas (Types 0, 1, and 2), whereas intramural location, without focal distortion of the endometrial cavity, is a characteristic of Types 4 and higher. The system now recognizes this area of overlap. It is also recognized that there are some difficulties in applying the leiomyoma subclassification system to the spectrum of leiomyomas that can be encountered, especially in large uteri with multiple leiomyomas.³³ There is now more detailed guidance for distinguishing amongst the leiomyoma subtypes.

Distinguishing between Type 0 and 1, and between Type 6 and 7 leiomyomas is now accomplished by comparing the stalk diameter to

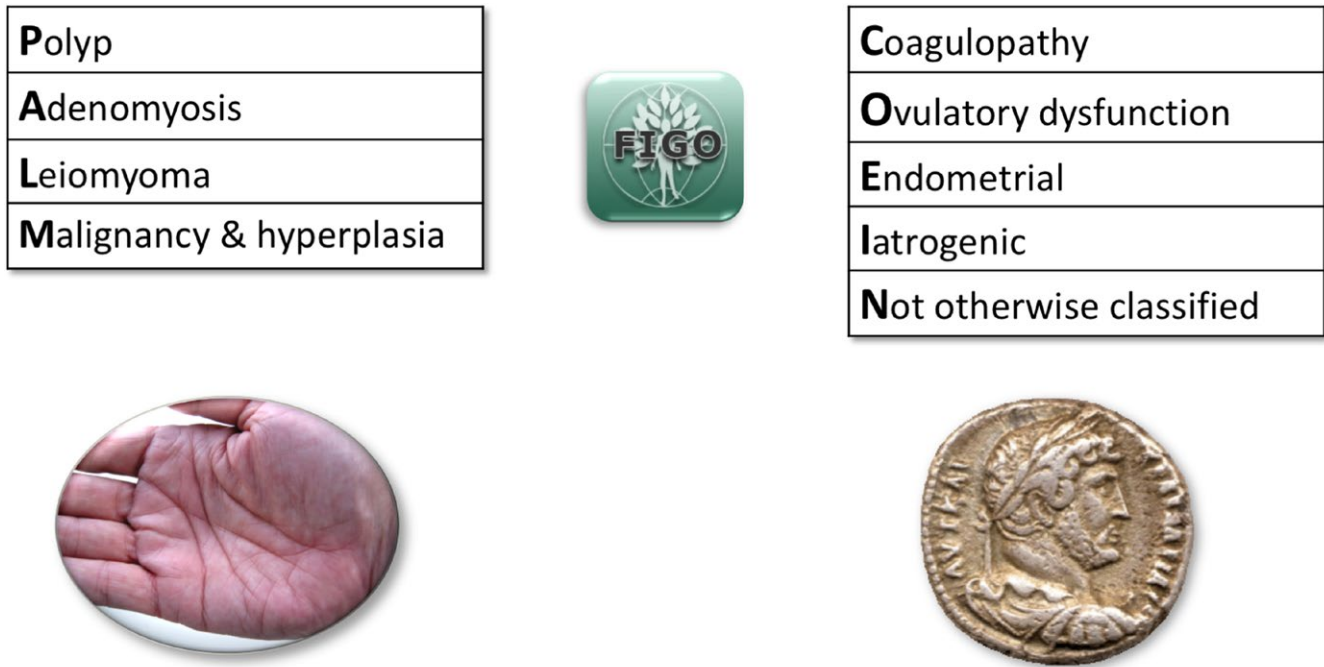


FIGURE 2 FIGO AUB System 2. PALM-COEIN System for Classification of Causes of AUB in the Reproductive Years. The basic system comprises four categories that are defined by visually objective structural criteria (PALM: Polyp; Adenomyosis; Leiomyoma; and Malignancy and hyperplasia), four that are unrelated to structural anomalies (COEI: Coagulopathy; Ovulatory dysfunction; Endometrial disorders; iatrogenic causes), and one reserved for entities categorized as “Not otherwise classified”. The leiomyoma category (L) is subdivided into patients with at least one submucous myoma (L_{SM}) and those with myomas that do not impact the endometrial cavity (L_o). Modified with permission.⁶⁷ Abbreviations: AUB, abnormal uterine bleeding; FIGO, International Federation of Gynecology and Obstetrics.

the mean diameter of the leiomyoma. Types 0 and 7 now comprise leiomyomas that have a stalk diameter that is 10% or less than the mean diameter of the leiomyoma. Hysteroscopy has now been deemed the standard for distinguishing between a Type 2 and 3 leiomyoma, with the determination based upon the lowest filling pressure that allows visualization of the endometrial cavity. Distinguishing between Type 4 and Type 5 leiomyomas should be based upon observation of distortion of the serosa (Type 5) as determined by ultrasonography or MRI.

FIGO now provides additional guidance for investigators using the FIGO subclassification system for leiomyomas. A minimal data set for describing leiomyomas should include an estimate of total uterine volume based on imaging (transabdominal or transvaginal ultrasonography or MRI), as well as an estimate of the number of leiomyomas (1, 2, 3, 4, or greater than 4). If such imaging is not available, such as may be the case in low-resource countries, the minimum data set should include an estimate of uterine size on clinical examination as equivalent

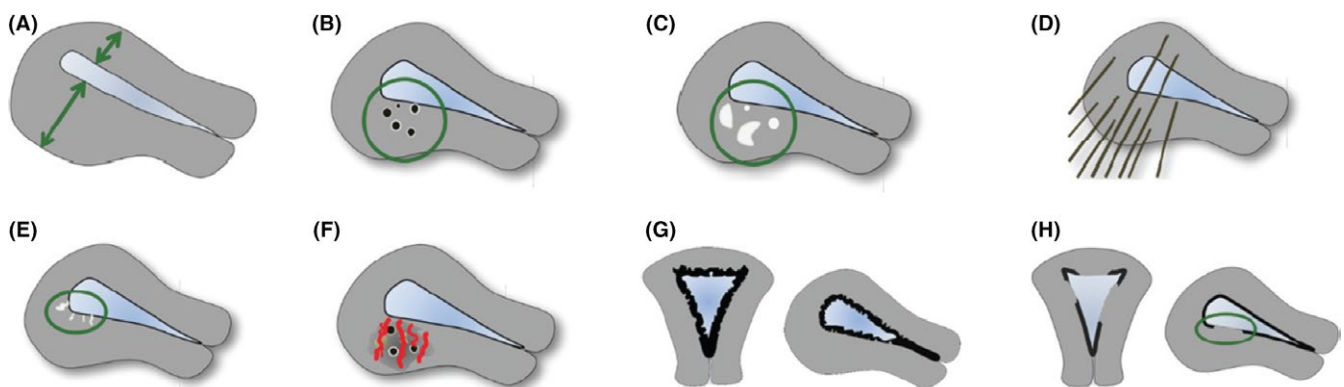
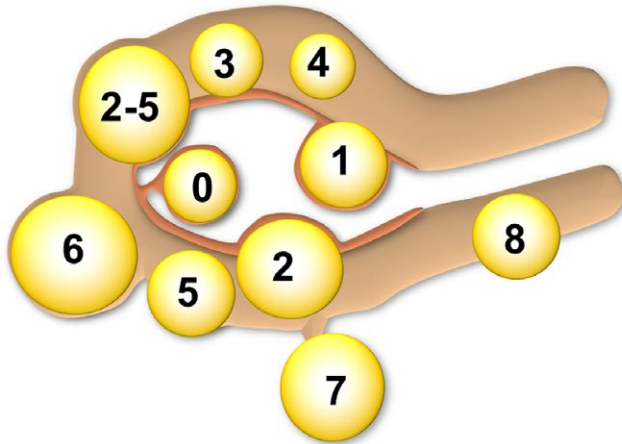


FIGURE 3 Adenomyosis diagnostic criteria. Graphical depictions of the eight TVUS criteria proposed by the MUSA group are presented. These include asymmetrical myometrial thickening (A); myometrial cysts (B); hyperechoic islands (C); fan shaped shadowing (D); echogenic subendometrial lines and buds (E); translesional vascularity (F), where present; irregular junctional zone (G); and an interrupted junctional zone (H). Identification and evaluation of the junctional zone may best be accomplished with three-dimensional ultrasonography. For the present at least, the presence of two or more of these criteria are highly associated with a diagnosis of adenomyosis. Reproduced with permission.³¹ Abbreviations: MUSA, Morphological Uterus Sonographic Assessment; TVUS, transvaginal ultrasonography.

FIGO Leiomyoma Subclassification System



Polyp	Submucous Other	Coagulopathy
Adenomyosis		Ovulatory dysfunction
Leiomyoma		Endometrial
Malignancy & hyperplasia		Iatrogenic
		Not otherwise classified

SM - Submucous	0	Pedunculated intracavitary
	1	<50% intramural
	2	≥50% intramural
	3	Contacts endometrium; 100% intramural
O - Other	4	Intramural
	5	Subserous ≥50% intramural
	6	Subserous <50% intramural
	7	Subserous pedunculated
	8	Other (specify e.g. cervical, parasitic)
Hybrid (contact both the endometrium and the serosal layer)	2-5	Submucous and subserous, each with less than half the diameter in the endometrial and peritoneal cavities, respectively.

© Malcolm G. Munro MD

FIGURE 4 FIGO leiomyoma subclassification system. System 2 classification system including the FIGO leiomyoma subclassification system. The system that includes the tertiary classification of leiomyomas categorizes the submucous group according to the original Wamsteker et al. system⁶⁸ and adds categorizations for intramural, subserosal, and transmural lesions. Intracavitary lesions are attached to the endometrium by a narrow stalk ($\leq 10\%$ or the mean of three diameters of the leiomyoma) and are classified as Type 0, whereas Types 1 and 2 require a portion of the lesion to be intramural—with Type 1 being less than 50% of the mean diameter and Type 2 at least 50%. Type 3 lesions are totally intramural but also about the endometrium. Type 3 are formally distinguished from Type 2 with hysteroscopy using the lowest possible intrauterine pressure necessary to allow visualization. Type 4 lesions are intramural leiomyomas that are entirely within the myometrium, with no extension to the endometrial surface or to the serosa. Subserous (Types 5, 6, and 7) leiomyomas represent the mirror image of the submucous leiomyomas—with Type 5 being at least 50% intramural, Type 6 being less than 50% intramural, and Type 7 being attached to the serosa by a stalk that is also $\leq 10\%$ or the mean of three diameters of the leiomyoma. Classification of lesions that are transmural are categorized by their relationship to both the endometrial and the serosal surfaces. The endometrial relationship is noted first, with the serosal relationship second (e.g. Type 2–5). An additional category, Type 8, is reserved for leiomyomas that do not relate to the myometrium at all, and would include cervical lesions (demonstrated), those that exist in the round or broad ligaments without direct attachment to the uterus, and other so-called “parasitic” lesions. Modified with permission.⁶⁷ Abbreviation: FIGO, International Federation of Gynecology and Obstetrics.

to a gravid uterus of “X” weeks. When transvaginal ultrasonography or MRI are available, the location (anterior, posterior, left, right, or center) and the estimated volume of up to four individual leiomyomas should be recorded. Additionally, the location in the vertical plane should be described; upper half, lower half, or both. When more than four are present, the volume of the largest leiomyoma should be recorded, as a minimum. If other leiomyomas are judged to be of equal or greater relevance for clinical decision making based on location, the volume of these lesions should be recorded as well. If the endometrium is visualized, then the relationship between the documented myomas and the endometrium should be described using the FIGO classification system.

Women with AUB and associated malignant or premalignant lesions of the uterus (e.g. endometrial carcinoma, leiomyosarcoma, and atypical endometrial hyperplasia sometimes, referred to as endometrial intraepithelial neoplasia or EIN^{34,35}), are categorized as having AUB-M. Their categorization is further defined using existent WHO and FIGO classification and staging systems.^{36,37}

AUB associated with the use of selected categories of systemic pharmacotherapy or intrauterine systems or devices, is classified as “iatrogenic”.³⁸ In addition to gonadal steroids such as estrogens, progestins, and androgens, and agents that directly affect their production or local function, this category now includes nonsteroidal pharmaceuticals that contribute to ovulatory disorders, such as those that affect dopamine metabolism, including phenothiazines and tricyclic antidepressants. In the original categorization, women with AUB associated with the use of anticoagulants were categorized with coagulopathies (AUB-C); in this revision, they are considered iatrogenic and classified as AUB-I. This includes the modern, non-vitamin-K antagonists such as rivaroxaban that appears to have a greater impact on the volume of menstrual bleeding than the traditional, vitamin K antagonists, typified by warfarin.^{39,40}

Category “N”, “not otherwise classified” was created in the original system to accommodate entities that are rarely encountered or are ill defined. These include, but are not limited to, entities such as arteriovenous malformations (AVMs)⁴¹ and the lower segment or upper

cervical niche or "isthmocele" frequently found in association with previous cesarean delivery and sometimes attributed to as a cause of AUB.^{42,43}

5 | NOTATION

After the patient has undergone appropriate investigation, discussed below, she could be found to have one or more potential causes of, or contributors to, the AUB symptoms. Consequently, the system has been designed to enable appropriate multi-category notation. While it is recognized that this increased level of complexity will be of most value to specialists and researchers, it should have utility for any healthcare provider.

This approach has been designed following the example of the WHO TNM staging of malignant tumors, with each component addressed for all women investigated for AUB symptoms using the two FIGO AUB Systems. For example, if an individual was suspected to have a disorder of ovulation, a type 2 leiomyoma, and no other anomalies, they would be categorized as follows in the context of a complete evaluation: AUB P₀ A₀ L_{1(SM)} M₀ - C₀ O₁ E₀ I₀ N₀. It was recognized that in clinical practice the use of such full notation might be considered cumbersome, so an option for abbreviation has been developed.

The abbreviated FIGO description of the patient previously described would be AUB-L_{SM}; -O.

FIGO now encourages clinicians and investigators to consider the use of a matrix for the evaluation of patients with AUB in the reproductive years (Fig. 5). This allows for the identification and documentation of the status of the investigation.

6 | RECOMMENDATIONS FOR CLINICAL INVESTIGATION

A woman presenting with AUB may have one or a number of factors that may contribute to the genesis of the symptoms. Using FIGO AUB System 1 to define the types of AUB symptoms present is a prerequisite to evaluation for the elements in FIGO AUB System 2. A number of pathological entities (e.g. subserous leiomyoma) may be present that are possibly or even unlikely to be a contributor to the symptoms. Consequently, the investigation of women with AUB during the reproductive years must be undertaken in as comprehensive but practicable fashion given the clinical situation and the available resources, with the findings carefully interpreted for their role in the symptoms. For example, available evidence would suggest that a single 1-cm polyp would not be the cause of the symptom of HMB.

	Y	N	?
P			
A			
L			
M			
C			
O			
E			
I			
N			

	Y	N	?
P		X	
A		X	
L_o	X		
M		X	
C			X
O		X	
E			X
I		X	
N		X	

	Y	N	?
P		X	
A		X	
L_o	X		
M		X	
C		X	
O		X	
E	X		
I		X	
N		X	

FIGURE 5 FIGO AUB System 2 diagnostic matrix. A simplified diagnostic matrix is illustrated in the left pane. Each of the primary classification system elements are listed. If a patient has not been completely evaluated for a potential cause it is listed in the “?” column, if evaluation has demonstrated no evidence of the abnormality the “N” column is checked, and if assessment is positive, an X is placed in the appropriate box. An example is shown in the panel on the right. The patient has the symptom of HMB, and interim assessment, including contrast hysterosonography documented in the left matrix has revealed a subserosal leiomyoma designated as L_o. However, the patient had a positive historical screening result for coagulopathy and hematological assessments for coagulation disorders are not yet available. Consequently, the “C” and “E” rows remain in the “?” category. The hematological assessment demonstrates that there is no evidence of coagulopathy, so the diagnosis of a primary disorder of endometrial hemostasis is made. The C row can now be assigned an “N” while the E category can be checked as “Y”. Abbreviations: AUB, abnormal uterine bleeding; FIGO, International Federation of Gynecology and Obstetrics; HMB, heavy menstrual bleeding.

A suggested approach is illustrated in Figure 6A,B, and described in brief below.

6.1 | General assessment

When evaluating a woman of reproductive age with either acute or chronic genital tract bleeding thought to be AUB, the clinician should ensure that the bleeding is not related to pregnancy, and is emanating from the cervical canal, rather than another location such as the vagina, vulva, perineum, or perianal region. Pregnancy may be reliably confirmed with a urine or serum assay for the presence of the β -subunit of human chorionic gonadotropin (hCG). It is to be noted that determination of the location or viability of a pregnancy is not considered to be within the domain of the FIGO-AUB systems. Women with both acute and chronic AUB should be evaluated for iron deficiency, if possible, with serum ferritin, and for related anemia by measuring hemoglobin and/or hematocrit (preferably a full blood count, including platelets). Once the bleeding has been confirmed, or suspected, to originate in the cervical canal or endometrial cavity, the clinician should systematically evaluate the patient for each of the components of FIGO AUB System 2, the PALM-COEIN classification.

6.2 | Determination of ovulatory status

Predictable cyclic menses every 24–38 days are usually (but not always) associated with ovulation whereas bleeding associated with ovulatory disorders is typically irregular in timing and flow, and often interspersed with episodes of amenorrhea.

If, largely based on FIGO AUB System 1, a woman is found to have AUB related to an ovulatory disorder, she is to be categorized as AUB-O. If there is uncertainty regarding ovulatory status, measurement of serum progesterone, timed to the best estimate of mid-luteal phase, may be useful for confirming ovulation in the current cycle. Whereas endometrial biopsy is not recommended as a method for determination of ovulatory status, when performed and appropriately indicated—to evaluate for the presence of premalignant or malignant endometrial change—histopathological findings reflecting secretory change may confirm that ovulation has occurred.

6.3 | Screening for systemic disorders of hemostasis

A structured history is a useful and effective screening tool. FIGO suggests a tool that has been demonstrated to have 90% sensitivity for the detection of these relatively common disorders (coagulopathies)⁴⁴ (Table 3). For those with a positive screening result, further testing is necessary, often following consultation with a physician with a special interest in disorders of coagulation, such as a hematologist. Such tests may include assays for von Willebrand factor, Ristocetin cofactor, partial thromboplastin time (PTT) and other measures.⁴⁵ If the results are positive, the woman with AUB would be being categorized as having AUB-C. Previously, by convention, individuals with AUB associated with the use of anticoagulant

therapy were categorized as AUB-C, but they now are included in the AUB-I category.

6.4 | Evaluation of the endometrium

Endometrial sampling is not required for all patients with AUB, so it is necessary to identify the women for whom endometrial biopsy is appropriate. Selection for endometrial sampling is based on a combination of risk factors for the presence of premalignant or malignant changes, comprising some combination of age, personal, and genetic risk factors, and TVUS screening for endometrial echocomplex thickness.^{5,46–49} Although some studies have indicated that age is not important as an independent variable,⁴⁷ most suggest that endometrial sampling be considered for all women over a certain age, usually 45 years.⁵ It is also evident that obesity contributes significantly to the risk of premalignant and malignant change in the endometrium, a feature that increases the risk of endometrial neoplasia even in young women in the third and fourth decades of life.⁵⁰ Women with a family history of hereditary nonpolyposis colorectal cancer syndrome, now called Lynch Syndrome, have a lifetime risk of endometrial cancer of up to 60%, with the mean age at diagnosis of 48–50 years.^{51,52} Regardless of the clinical guideline, when AUB is persistent and either unexplained or inadequately treated, endometrial sampling is necessary—if possible—in association with hysteroscopic evaluation of the uterine cavity.²⁸ Sonohysterography is likely a reasonable substitute for hysteroscopy to diagnose for polyps and submucous leiomyomas.^{53–55} There exist a number of techniques for endometrial sampling, but it is important that an adequate sample be obtained before the patient can be considered at low risk for a malignant neoplasm.⁵⁶

It is apparent that a relationship exists between chlamydial infection of the endometrium and AUB. Consequently, it may be prudent to consider evaluating for the presence of the organism in symptomatic patients.⁵⁷ Although cervical assays seem reasonable, the relationship between cervically obtained specimens and the presence of absence of endometrial infection is unclear.⁵⁸ If chronic endometritis is identified, patients should be categorized as having AUB-E.

6.5 | Evaluation of the structure of the endometrial cavity

Evaluation for structural abnormalities affecting the endometrial cavity is performed to identify pathology—including endometrial or endocervical polyps and submucous leiomyomas—that could contribute to AUB. Transvaginal ultrasonography (TVUS) is an appropriate and important screening tool and, in most instances, should be performed early in the course of the investigation. Ideally, the ultrasonography system must be of adequate quality to clearly display both myometrial and endometrial features, and the examiner should have the ability to operate the scanning device and interpret the images displayed. Regardless, TVUS is not 100% sensitive even in ideal circumstances because polyps and other small lesions may elude detection, even in the context of a normal study.^{59,60}

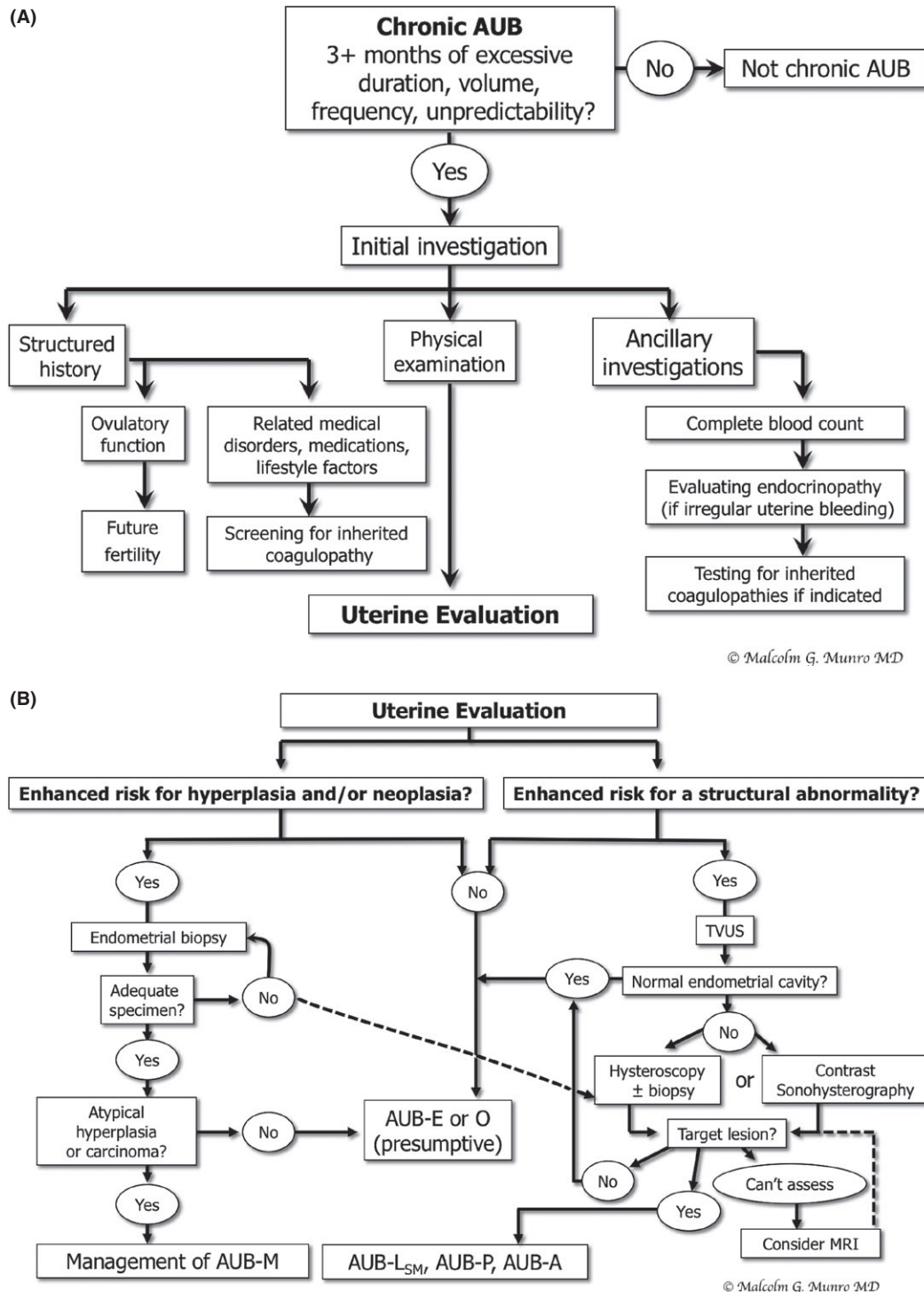


FIGURE 6 Investigative algorithms for patients with chronic AUB during the reproductive years. (A) Initial investigation comprises a structured history, physical examination, and the use of appropriate ancillary investigations, in part based upon the history and physical assessment. Evidence suggesting an ovulatory disorder prompts assessment for endocrinopathy, whereas a positive screening result for coagulopathy (Figure 7) will indicate the need for appropriate hematological assessment. A complete blood count should be performed on all women with the symptom of heavy menstrual bleeding. (B) A pragmatic guide to uterine assessment. If the initial evaluation (Figure 6A) suggests a low risk for coagulopathy, structural or malignant/premalignant change, patients may be presumed to have AUB-E or -O and offered appropriate treatment options. However, if there is an enhanced risk for endometrial hyperplasia or malignancy (left), endometrial sampling is recommended. If an adequate specimen is not obtained, hysteroscopic examination and biopsy is recommended. If there is an enhanced risk for a structural abnormality, transvaginal ultrasonography is the next step (right). If evaluation of the endometrium is suboptimal or there is a suggestion of an abnormality affecting the endometrial cavity, either hysteroscopy or contrast hysterosonography is indicated. MRI may be occasionally indicated if hysteroscopy or contrast hysterosonography are not feasible, such as in the case of virginal women. Abbreviations: AUB, abnormal uterine bleeding; MRI, magnetic resonance imaging; TVUS, transvaginal ultrasonography. Images are used courtesy of Malcolm G. Munro.

(A) System 1 (Symptoms)

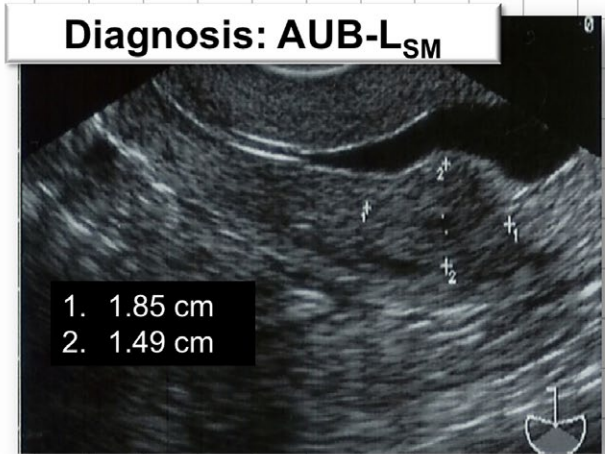
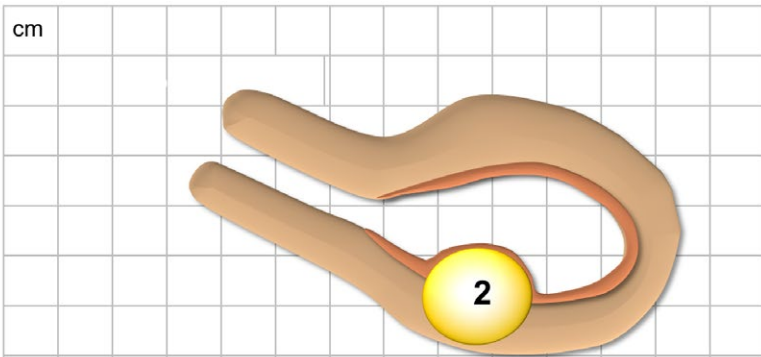
- Cycle Length: 30 days
- Regularity: ± 2 days
- Duration: 10 days
- Volume: Heavy
- Intermenstrual Bleeding: -

System 2 (PALM-COEIN)

- Leiomyoma: Type 2

	Y	N	?
P		X	
A		X	
L _{sm}	X		
M		X	

C		X	
O		X	
E		X	
I		X	
N		X	



© Malcolm G. Munro MD

(B)

System 1 (Symptoms)

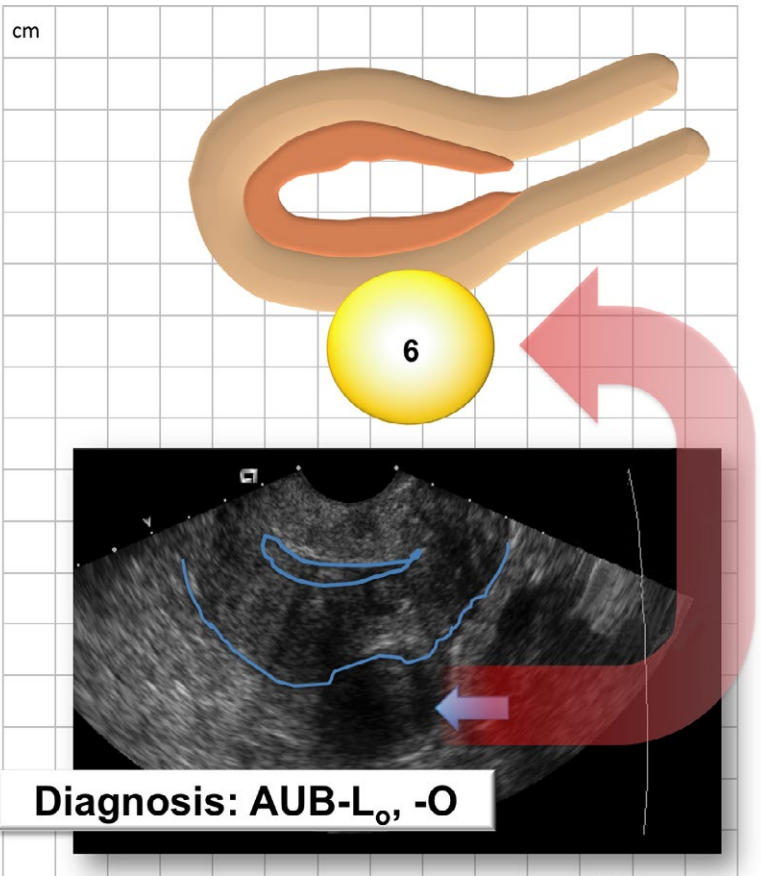
- Cycle Length: 14-60 days
- Regularity: ± 46 days
- Duration: 2-11 days
- Volume: Normal to Heavy
- Intermenstrual Bleeding

System 2 (PALM-COEIN)

- Leiomyoma: Type 6
- Ovulatory Disorder

	Y	N	?
P		X	
A		X	
L _o	X		
M		X	

C		X	
O	X		
E		X	
I		X	
N		X	



© Malcolm G. Munro MD

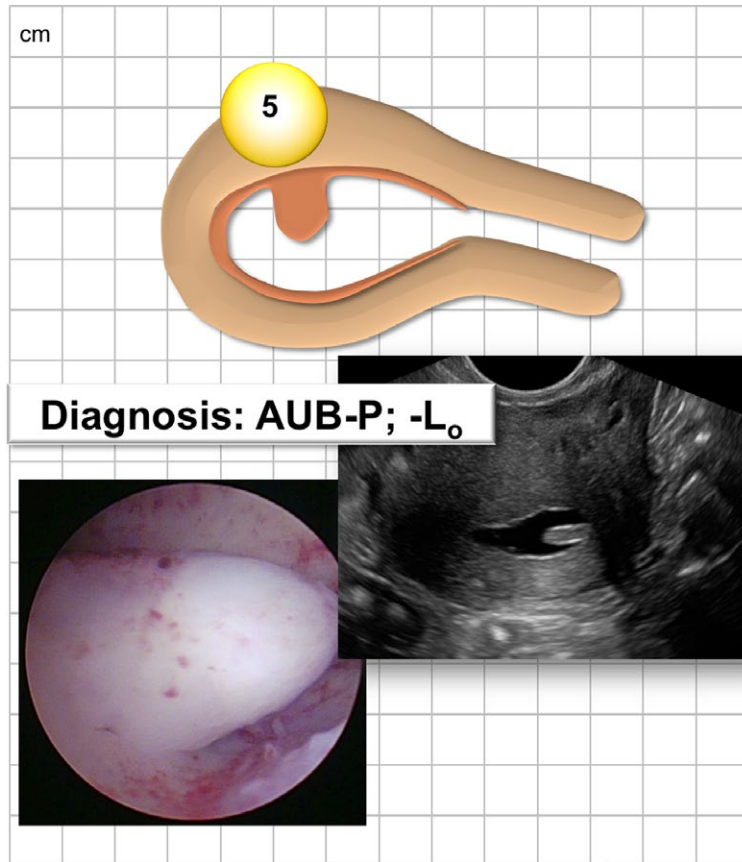
(C) System 1 (Symptoms)

- Cycle Length: 31 days
- Regularity: ±3 days
- Duration: 4 days
- Volume: Normal
- Intermenstrual Bleeding: +

System 2 (PALM-COEIN)

- Polyp: Endometrial
- Leiomyoma: Type 5

	Y	N	?
P	X		
A		X	
L _o	X		
M		X	
C		X	
O		X	
E		X	
I		X	
N		X	



© Malcolm G. Munro MD

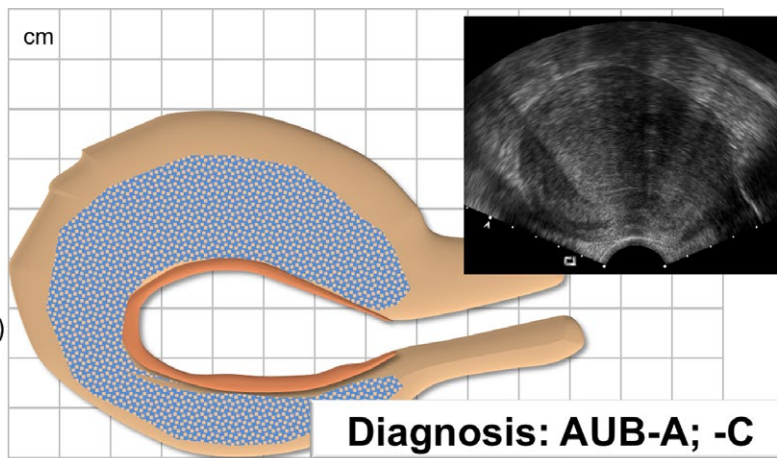
(D) System 1 (Symptoms)

- Cycle Length: 33 days
- Regularity: ±3 days
- Duration: 9 days
- Volume: Heavy
- Intermenstrual Bleeding: -

System 2 (PALM-COEIN)

- Adenomyosis
- Coagulopathy (vWD, Type 1)

	Y	N	?
P		X	
A	X		
L		X	
M		X	
C	X		X
O		X	
E		X	
I		X	
N		X	



Screen

Test	Result	Normal	Interpretation
vWF	45%	55-200%	+
Ristocetin CoF	17 IU/dL	50-200 IU/dL	+
aPTT	45 sec	28-38 sec	+
PT	17 sec	9.5 – 13.8 sec	+
Factor VIII	36	55-200%	+

© Malcolm G. Munro MD

FIGURE 7 Four examples of the use of a matrix to guide FIGO-based evaluation of patients with chronic AUB. (A) Patient with the symptom of heavy menstrual bleeding (duration of menses 10 d and perceived as affecting the patient's quality of life). Contrast sonohysterography demonstrates a posterior Type 2 leiomyoma 1.85 by 1.49 cm in diameter. All other investigations have been completed and are negative. Diagnosis: AUB-L_{SM}. (B) Here the cycle length varies from 14 to 60 d, the duration of menstrual bleeding from 2 to 11 d, and the volume ranging from light to heavy. Transvaginal sonography shows a posterior Type 6 leiomyoma. Other investigations are normal save the thyroid-stimulating hormone, which is elevated. Diagnosis: AUB-L_O; -O with the primary cause of AUB the ovulatory disorder secondary to hypothyroidism. (C) In this example the patient's menstrual parameters are normal with the exception of her complaint of intermittent intermenstrual bleeding. Contrast sonohysterography shows an endometrial polyp and a Type 5 leiomyoma (not shown). The hysteroscopic view at the time of the polypectomy is shown. Diagnosis: AUB-P; -L_O with the primary cause of the AUB the endometrial polyp. (D) This patient has the complaint of lifelong heavy menstrual bleeding that is becoming heavier, with clots, and associated with worsening dysmenorrhea that lasts the entire period. She has a history of easy bruising and frequently bleeds when brushing her teeth. Her menses are cyclically predictable with a normal cycle length of 33 d. Transvaginal ultrasonography shows a globular uterus, an asymmetrically thickened posterior myometrium, and fan-shaped shadowing. All of the coagulation parameters measured were abnormal, and consistent with vWD Type 1. Diagnosis: AUB-A, -C. Abbreviations: AUB, abnormal uterine bleeding; FIGO, International Federation of Gynecology and Obstetrics; vWD, von Willebrand disease. Images are used courtesy of Malcolm G. Munro.

If good ultrasonic images fail to show findings suggestive of endometrial polyps or submucous leiomyomas, the clinician may initially presume that the structure of the endometrial cavity is normal. However, if there are imaging features that indicate the presence of endometrial polyp(s), if there are leiomyomas that may encroach on the endometrial cavity, or if the examination is suboptimal, imaging with more sensitive techniques is recommended. These generally include hysteroscopy and/or transvaginal ultrasonography with intrauterine contrast, either gel or saline, termed sonohysterography. Which of these techniques is used will depend on the resources available to the clinician.⁵³⁻⁵⁵ In most instances, sonohysterography will be more readily available, particularly when the only available resources for hysteroscopy reside in an operating room. However, if office hysteroscopy is available, there may be additional value, particularly when polyps are suspected, as hysteroscopically directed polypectomy will be feasible in the same setting.

In some parts of the world, notably in the UK (managed by the British National Health Service), there is an emphasis on conducting investigation and management of the symptom of HMB at the first consultation ("One stop management", including key history, examination, transvaginal ultrasonography, and hysteroscopy, if indicated, at the same visit).²⁸ This type of management has been assisted by the systematic application of the two FIGO AUB Systems – clearly defining the symptoms using FIGO AUB System 1, and then, following an appropriately structured evaluation, categorization of the findings or assessments using FIGO AUB System 2, the PALM-COIN classification.

When vaginal access is difficult or impossible, a circumstance often encountered with adolescents and virginal women, TVUS, contrast sonohysterography, and office hysteroscopy may not be feasible. In such instances, there is a role for MRI. Alternatively, hysteroscopic examination with indicated biopsies, performed under appropriate anesthesia may be the best approach.

With the PALM-COIN classification, the presence of a polyp or polyps (AUB-P) is confirmed only with documentation of one or more clearly defined polyps, generally with either hysteroscopy or sonohysterography. Usually, a patient may be categorized with one or more submucous leiomyomas (AUB-L_{SM}) with either sonohysterography or hysteroscopy. When using either, the clinician should take care to infuse the distending medium with low pressure so that the natural

relationships of the leiomyoma with the endometrium and myometrium are distorted. As described above, FIGO now recommends that the distinction between Type 2 and 3 leiomyomas be based upon hysteroscopy performed using the lowest pressure necessary to evaluate these relationships. The use of sonohysterography for this purpose is considered to be a suitable and more practical substitute in a variety of clinical situations.

6.6 | Myometrial assessment

For the primary leiomyoma categorization, the myometrium is assessed primarily with a combination of TVUS and transabdominal ultrasonography to identify leiomyomas, with any such identified lesion leading to an "L" assignment. For the secondary subclassification, it is necessary to determine the relationship (contact or not) of the endometrium with the leiomyoma by performing some combination of TVUS, contrast sonohysterography, hysteroscopy, and MRI. Should one or more submucous leiomyomas be found (Types 0, 1, 2, or 3) then the woman is stated to have L_{SM}, if only Type 4, 5, 6, 7, and/or 8 are identified, the categorization is L_O.

Tertiary subclassification of leiomyoma type requires that the clinician clarify the relationship of the leiomyomas with the endometrium, endometrial cavity, myometrium, and uterine serosa. At least for those leiomyomas that do not distort the endometrial cavity (Types 3 and up), this distinction requires the use of imaging, either ultrasonography, or, more accurately MRI as described previously.

The myometrium should also be evaluated for the presence of adenomyosis or to distinguish between leiomyomas and localized collections of adenomyosis or adenomyomas.^{31,61} The sonographic and MRI criteria for the diagnosis of adenomyosis are described elsewhere in the present document. While the FIGO MDC is currently developing a system for the classification of adenomyosis, for the present, an assignment of AUB-A is best based on imaging findings consistent with TVUS as described above³¹ (Fig. 3) or, if available, using MRI.³⁰ Although promising for the diagnosis of adenomyosis, the role of both three-dimensional TVUS^{62,63} and sonographic elastography^{64,65} is still a subject of investigation.

If available, MRI may be necessary for evaluation of the myometrium to distinguish between leiomyomas and adenomyosis. MRI

TABLE 3 Screening instrument for coagulopathies in women with the symptom of heavy menstrual bleeding.^{a,b}

Initial screening for an underlying disorder of hemostasis in patients with excessive menstrual bleeding should be by a structured history. A positive screening result comprises any of the following:^c

1. Heavy menstrual bleeding since menarche
2. One of the following:
 - a Postpartum hemorrhage
 - b Surgical related bleeding
 - c Bleeding associated with dental work
3. Two or more of the following symptoms:
 - a Bruising 1–2 times per month
 - b Epistaxis 1–2 times per month
 - c Frequent gum bleeding
 - d Family history of bleeding symptoms

^aReproduced with permission.⁴⁵

^bThis structured history-based instrument is 90% sensitive for the presence of a coagulopathy in women with the symptom of heavy menstrual bleeding.

^cPatients with a positive screening result should be considered for further evaluation including consultation with a hematologist and/or testing of von Willebrand factor and Ristocetin cofactor.

imaging may also be superior to TVUS, sonohysterography, and hysteroscopy for measuring the myometrial extent of submucous leiomyomas.⁵⁹ However, reliance on MRI is currently impractical, especially for low-resource nations, because of the relative or absolute lack of access within many healthcare systems.⁶⁶

7 | DISCUSSION

AUB in women of reproductive age is a manifestation of any of a number of disorders or pathologic entities. The FIGO systems for nomenclature and symptoms (System 1), and for classification of potential causes of AUB in the reproductive years (System 2) are designed to facilitate both basic science and clinical investigation, as well as the practical, rational, and consistent application of medical and surgical therapy for affected women. The current revisions of the two FIGO-AUB systems are designed to clarify and modify, in a fashion that should improve the utility of these systems for research, education, and clinical care. Clinicians, educators, and investigators are encouraged to use the matrix concept to guide the evaluation of women afflicted with chronic AUB, as well as acute AUB once the patient is stabilized (Fig. 7).

These systems, and their continued and appropriate revision, represent a collaboration involving clinicians, investigators, and other informed participants from six continents. This participation was designed to develop an implementable System 1 and to provide input into the practicality of performing the investigations described for categorizing according to System 2, the PALM-COEIN classification. Currently, the routine characterization of structural lesions of the uterus using MRI is not feasible and its use is not included as a mandatory tool for evaluating patients with chronic AUB. This does not mean that clinicians cannot or should

not use MRI if it is deemed necessary and is available, with the results used to categorize leiomyoma type or determine the presence, absence, or location and extent of adenomyosis.

8 | CONCLUSION

The present paper reports the changes to both FIGO AUB systems based on 6 years of analysis, discussion, and debate since the original publication. The original seminal publications presented effective approaches to the terminologies and definitions around AUB (System 1), followed by development of a novel classification (PALM-COEIN) of underlying causes of abnormal uterine bleeding in the reproductive years (System 2).¹⁴ These developments and refinements are integrated into the whole FIGO-AUB model in this manuscript.

AUTHOR CONTRIBUTIONS

MGM, HODC, and ISF contributed to the development, drafting, and review of the present manuscript.

PARTICIPATING MEMBERS OF THE FIGO MENSTRUAL DISORDERS COMMITTEE, 2015–2018

Rohana Haththotuwa, MD Chair; Alka Kriplani, MD, co-Chair; Luis Bahamondes, MD, Ph.D; Hilary O.D. Critchley, MD; Ian S. Fraser, MD; Carlos Füchtner, MD; Malcolm G. Munro, MD; Rebecca Tonye, MD.

LIST OF CONTRIBUTORS TO THE PROCESS

The participants in this process have contributed substantially to the evolving debate around several aspects of the common symptoms of AUB at workshops in Washington (2005), and/or Cape Town (2009), and/or Rome (2012), and/or Vancouver (2015), and/or Singapore (2017), and in private debate. They have all approved the listing of their names in the present manuscript. The names are listed alphabetically and none of the individuals represented the views of their organizations. The following have personally participated in the development of the FIGO systems as participants in workshops, on subcommittees, in some instances representing their organization as indicated in the parentheses.

David Archer, USA; Jason Abbott, Australia (Australasian Gynaecologic Endoscopy Society [AGES]); Ahmad Abdel-Wahed, Jordan; Luis Bahamondes, Brazil; Marina Berbic, Australia; Vivian Brache, Dominican Republic; Daniel Breitkoph, USA (American College of Obstetricians and Gynecologists [ACOG]); Andrew Brill, USA (AAGL); Michael Broder, USA; Ivo Brosens, Belgium; Kristoph Chwalisz, USA; Justin Clark, UK (Royal College of Obstetricians and Gynaecologists [RCOG]); Hilary O.D. Critchley, UK; Catherine d'Arcaques, Switzerland (World Health Organization [WHO]); Margit Dueholm, Denmark; Hans Mark Emanuel, Netherlands; Cynthia Farquhar, New Zealand (Cochrane Collaboration on Menstrual

Disorders); Mario Festin, Switzerland (WHO); Yoke Fai Fong, Singapore (Society of Endometriosis and Uterine Disorders [SEUD]); Ian S. Fraser, Australia (Royal Australian and New Zealand College of Obstetricians and Gynaecologists [RANZCOG]); Marc Fritz, USA; Carlos Fuchner, Bolivia (International Federation of Gynecology and Obstetrics [FIGO]); Sun-Wei Guo, China (Society of Endometriosis and Uterine Disorders [SEUD]); Stephan Gordts, Belgium (European Society of Human Reproduction and Embryology [ESHRE]); Grigoris Grizimis, Greece (European Society of Gynecologic Endoscopy [ESGE]); Sioban Harlow, USA; Rohana Hathtootuwa, Sri Lanka (FIGO); Oskari Heikinheimo, Finland; Martha Hickey, Australia; Jennifer Higham, UK; William Hurd, USA (Fertility Sterility); Keith Isaacson, USA (American Society of Reproductive Medicine [ASRM]); Julia Johnson, USA (ACOG); Alka Kriplani, India; Ricardo Lasmar, Brazil; Lee Learman, USA; Charles Lockwood, USA; Andrea Lukes, USA; Diana Mansur, UK; Kristen Matteson, USA; Malcolm G. Munro, USA; Scott Monroe, USA (Food and Drug Administration [FDA]); Ian Milsom, Sweden; Andrew Mok, Canada (Society of Obstetricians and Gynecologists of Canada [SOGC]); Evan Myers, USA; Anita Nelson, USA; Shaughn O'Brien, UK (RCOG); David Olive, USA; Colin Pollard, USA (FDA); Rachel Pope, Israel; Oskari Heikinheimo, Finland; Elisabeth Persson, Sweden; Robert Rebar, USA (ASRM); Dorothy Shaw, Canada (FIGO); Shirish Sheth, India (FIGO); Sukbir (Sony) Singh, Canada (SOGC); Robert Schenken, USA; James Spies, USA; Elizabeth Stewart, USA; Delphin Tan, Philippines; David Taub, USA; Rebecca Tonye, Cameroon; Zephne van der Spuy, South Africa; Paolo Vercellini, Italy (ESHRE); Kirsten Vogelsong, Switzerland (WHO); Pamela Warner, UK.

CONFLICTS OF INTEREST

Each author has received royalties from Up-to-Date. MGM and ISF have acted as consultants for, and/or given lectures for, and received honoraria from Bayer AG (Berlin), Bayer Women's Health, and Vifor Pharma, which has partly funded this initiative (as outlined in the relevant publications). ISF has acted as a consultant for Merk. MGM has functioned as a consultant to Abbvie, Datchi Sankyo, Myovant Sciences, and Hologic, the latter a contributor to funding to the FIGO Menstrual Disorders Committee. HODC has acted as a consultant (no personal honoraria received) for Bayer AG, PregLem SA, Gedeon Richter, Vifor Pharma UK, AbbVie, and Myovant Sciences. Many other organizations and companies have contributed in direct or indirect ways to the development of this process. The process has been approved by FIGO and the FIGO Menstrual Disorders Committee.

REFERENCES

1. Khatri R, Gupta AN. Effect of childbirth on menstrual pattern. *Indian J Med Res.* 1978;67:66–72.
2. Gao J, Zeng S, Sun BL, Fan HM, Han LH. Menstrual blood loss and hematologic indices in healthy Chinese women. *J Reprod Med.* 1987;32:822–826.
3. Oehler MK, Rees MC. Menorrhagia: An update. *Acta Obstet Gynecol Scand.* 2003;82:405–422.
4. Harlow SD, Campbell OM. Epidemiology of menstrual disorders in developing countries: A systematic review. *BJOG.* 2004;111:6–16.
5. *Heavy Menstrual Bleeding.* Excellence NfHaC, editor. United Kingdom: National Institute for Health and Clinical Excellence; 2007.
6. Liu Z, Doan QV, Blumenthal P, Dubois RW. A systematic review evaluating health-related quality of life, work impairment, and health-care costs and utilization in abnormal uterine bleeding. *Value Health.* 2007;10:183–194.
7. Matteson KA, Raker CA, Clark MA, Frick KD. Abnormal uterine bleeding, health status, and usual source of medical care: Analyses using the Medical Expenditures Panel Survey. *J Womens Health (Larchmt).* 2013;22:959–965.
8. Fraser IS, Mansour D, Breyman C, Hoffman C, Mezzacasa A, Petraglia F. Prevalence of heavy menstrual bleeding and experiences of affected women in a European patient survey. *Int J Gynecol Obstet.* 2015;128:196–200.
9. Kazemijalish H, Ramezani Tehrani F, Behboudi-Gandevani S, Khalili D, Hosseinpah F, Azizi F. A population-based study of the prevalence of abnormal uterine bleeding and its related factors among Iranian reproductive-age women: An updated data. *Arch Iran Med.* 2017;20:558–563.
10. Cote I, Jacobs P, Cumming DC. Use of health services associated with increased menstrual loss in the United States. *Am J Obstet Gynecol.* 2003;188:343–348.
11. Frick KD, Clark MA, Steinwachs DM, et al. Financial and quality-of-life burden of dysfunctional uterine bleeding among women agreeing to obtain surgical treatment. *Women's Health Issues.* 2009;19:70–78.
12. Khaskheli MN, Baloch S, Sheeba A, Baloch S, Khaskheli FK. Iron deficiency anaemia is still a major killer of pregnant women. *Pak J Med Sci.* 2016;32:630–634.
13. Maswime S, Buchmann E. Causes and avoidable factors in maternal death due to cesarean-related hemorrhage in South Africa. *Int J Gynecol Obstet.* 2016;134:320–323.
14. Munro MG, Critchley HO, Broder MS, Fraser IS; FIGO Working Group on Menstrual Disorders. FIGO classification system (PALM-COEIN) for causes of abnormal uterine bleeding in nongravid women of reproductive age. *Int J Gynecol Obstet.* 2011;113:3–13.
15. Fraser IS, Critchley HO, Munro MG, Broder M. A process designed to lead to international agreement on terminologies and definitions used to describe abnormalities of menstrual bleeding. *Fertil Steril.* 2007;87:466–476.
16. Fraser IS, Critchley HO, Munro MG, Broder M. Can we achieve international agreement on terminologies and definitions used to describe abnormalities of menstrual bleeding? *Hum Reprod.* 2007;22:635–643.
17. Woolcock JG, Critchley HO, Munro MG, Broder MS, Fraser IS. Review of the confusion in current and historical terminology and definitions for disturbances of menstrual bleeding. *Fertil Steril.* 2008;90:2269–2280.
18. Fraser IS, Munro MG, Critchley HOD. Abnormal uterine bleeding in reproductive-age women: Terminology and PALM-COEIN etiology classification. Published 2017. <https://www.uptodate.com/contents/abnormal-uterine-bleeding-in-reproductive-age-women-terminology-and-palm-coein-etiology-classification>. Accessed March 20, 2018.
19. Munro MG, Critchley H, Fraser IS. Research and clinical management for women with abnormal uterine bleeding in the reproductive years: More than PALM-COEIN. *BJOG.* 2017;124:185–189.
20. Munro MG. Practical aspects of the two FIGO systems for management of abnormal uterine bleeding in the reproductive years. *Best Pract Res Clin Obstet Gynaecol.* 2017;40:3–22.
21. Munro MG, Critchley HO, Fraser IS. The FIGO classification of causes of abnormal uterine bleeding in the reproductive years. *Fertil Steril.* 2011;95:2204–2208, 8.e1-3.

22. Critchley HO, Munro MG, Broder M, Fraser IS. A five-year international review process concerning terminologies, definitions, and related issues around abnormal uterine bleeding. *Semin Reprod Med.* 2011;29:377–382.
23. Fraser IS, Critchley HO, Broder M, Munro MG. The FIGO recommendations on terminologies and definitions for normal and abnormal uterine bleeding. *Semin Reprod Med.* 2011;29:383–390.
24. Munro MG, Critchley HO, Fraser IS. The flexible FIGO classification concept for underlying causes of abnormal uterine bleeding. *Semin Reprod Med.* 2011;29:391–399.
25. American College of Obstetricians and Gynecologists. ACOG committee opinion no 557: Management of acute abnormal uterine bleeding in nonpregnant reproductive-aged women. *Obstet Gynecol.* 2013;121:891–896.
26. Harlow SD, Gass M, Hall JE, et al. Executive summary of the Stages of Reproductive Aging Workshop + 10: Addressing the unfinished agenda of staging reproductive aging. *Fertil Steril.* 2012; 97:843–851.
27. Harlow SD, Lin X, Ho MJ. Analysis of menstrual diary data across the reproductive life span applicability of the bipartite model approach and the importance of within-woman variance. *J Clin Epidemiol.* 2000;53:722–733.
28. Heavy menstrual bleeding: Assessment and management (NG88). London; 2018.
29. Champaneria R, Abedin P, Daniels J, Balogun M, Khan KS. Ultrasound scan and magnetic resonance imaging for the diagnosis of adenomyosis: Systematic review comparing test accuracy. *Acta Obstet Gynecol Scand.* 2010;89:1374–1384.
30. Bazot M, Darai E. Role of transvaginal sonography and magnetic resonance imaging in the diagnosis of uterine adenomyosis. *Fertil Steril.* 2018;109:389–397.
31. Van den Bosch T, Dueholm M, Leone FP, et al. Terms, definitions and measurements to describe sonographic features of myometrium and uterine masses: A consensus opinion from the Morphological Uterus Sonographic Assessment (MUSA) group. *Ultrasound Obstet Gynecol.* 2015;46:284–298.
32. Andres MP, Borrelli GM, Ribeiro J, Baracat EC, Abrao MS, Kho RM. Transvaginal ultrasound for the diagnosis of adenomyosis: Systematic review and meta-analysis. *J Minim Invasive Gynecol.* 2018;25: 257–264.
33. Laughlin-Tommaso SK, Hesley GK, Hopkins MR, Brandt KR, Zhu Y, Stewart EA. Clinical limitations of the International Federation of Gynecology and Obstetrics (FIGO) classification of uterine fibroids. *Int J Gynecol Obstet.* 2017;139:143–148.
34. Mutter GL. Endometrial intraepithelial neoplasia (EIN): Will it bring order to chaos? The Endometrial Collaborative Group. *Gynecol Oncol.* 2000;76:287–290.
35. Jarboe EA, Mutter GL. Endometrial intraepithelial neoplasia. *Semin Diagn Pathol.* 2010;27:215–225.
36. Creasman W. Revised FIGO staging for carcinoma of the endometrium. *Int J Gynecol Obstet.* 2009;105:109.
37. Emons G, Beckmann MW, Schmidt D, Mallmann P; Uterus commission of the Gynecological Oncology Working G. New WHO Classification of Endometrial Hyperplasias. *Geburtshilfe Frauenheilkd.* 2015;75:135–136.
38. Fraser IS. Bleeding arising from use of exogenous steroids. *Baillieres Best Pract Res Clin Obstet Gynaecol.* 1999;13:203–222.
39. De Crem N, Peerlinck K, Vanassche T, et al. Abnormal uterine bleeding in VTE patients treated with rivaroxaban compared to vitamin K antagonists. *Thromb Res.* 2015;136:749–753.
40. Bryk AH, Pirog M, Plens K, Undas A. Heavy menstrual bleeding in women treated with rivaroxaban and vitamin K antagonists and the risk of recurrent venous thromboembolism. *Vascul Pharmacol.* 2016;87:242–247.
41. Yoon DJ, Jones M, Taani JA, Buhimschi C, Dowell JD. A systematic review of acquired uterine arteriovenous malformations: Pathophysiology, diagnosis, and transcatheter treatment. *AJP Rep.* 2016;6:e6–e14.
42. Bij dVA, van der Voet LF, Naji O, et al. Prevalence, potential risk factors for development and symptoms related to the presence of uterine niches following Cesarean section: Systematic review. *Ultrasound Obstet Gynecol.* 2014;43:372–382.
43. Tulandi T, Cohen A. Emerging manifestations of cesarean scar defect in reproductive-aged women. *J Minim Invasive Gynecol.* 2016;23:893–902.
44. Kadir RA, Economides DL, Sabin CA, Owens D, Lee CA. Frequency of inherited bleeding disorders in women with menorrhagia. *Lancet.* 1998;351:485–489.
45. Kouides PA, Conard J, Peyvandi F, Lukes A, Kadir R. Hemostasis and menstruation: Appropriate investigation for underlying disorders of hemostasis in women with excessive menstrual bleeding. *Fertil Steril.* 2005;84:1345–1351.
46. Farquhar CM, Lethaby A, Sowter M, Verry J, Baranyai J. An evaluation of risk factors for endometrial hyperplasia in premenopausal women with abnormal menstrual bleeding. *Am J Obstet Gynecol.* 1999;181:525–529.
47. Ash SJ, Farrell SA, Flowerdew G. Endometrial biopsy in DUB. *J Reprod Med.* 1996;41:892–896.
48. An evidence-based guideline for the management of heavy menstrual bleeding. Working Party for Guidelines for the Management of Heavy Menstrual Bleeding. *N Z Med J.* 1999;112:174–177.
49. Guidelines for the management of abnormal uterine bleeding. *J Obstet Gynaecol Can.* 2001;104:1–6.
50. Wise MR, Jordan V, Lagas A, et al. Obesity and endometrial hyperplasia and cancer in premenopausal women: A systematic review. *Am J Obstet Gynecol.* 2016;214(689):e1–e17.
51. Lu KH, Broaddus RR. Gynecological tumors in hereditary nonpolyposis colorectal cancer: We know they are common—now what? *Gynecol Oncol.* 2001;82:221–222.
52. Lu KH, Dinh M, Kohlmann W, et al. Gynecologic cancer as a “sentinel cancer” for women with hereditary nonpolyposis colorectal cancer syndrome. *Obstet Gynecol.* 2005;105:569–574.
53. Leone FP, Lanzani C, Ferrazzi E. Use of strict sonohysterographic methods for preoperative assessment of submucous myomas. *Fertil Steril.* 2003;79:998–1002.
54. Maheux-Lacroix S, Li F, Laberge PY, Abbott J. Imaging for polyps and leiomyomas in women with abnormal uterine bleeding: A systematic review. *Obstet Gynecol.* 2016;128:1425–1436.
55. Bittencourt CA, Dos Santos Simoes R, Bernardo WM, et al. Accuracy of saline contrast sonohysterography in detection of endometrial polyps and submucosal leiomyomas in women of reproductive age with abnormal uterine bleeding: Systematic review and meta-analysis. *Ultrasound Obstet Gynecol.* 2017;50:32–39.
56. Critchley HO, Warner P, Lee AJ, Brechin S, Guise J, Graham B. Evaluation of abnormal uterine bleeding: Comparison of three outpatient procedures within cohorts defined by age and menopausal status. *Health Technol Assess.* 2004;8:iii–iv, 1–139.
57. Toth M, Patton DL, Esquenazi B, Shevchuk M, Thaler H, Divon M. Association between Chlamydia trachomatis and abnormal uterine bleeding. *Am J Reprod Immunol.* 2007;57:361–366.
58. Villagrana Zesati JR, Lopez Hurtado M, Flores Salazar VR, de Haro Cruz MJ, Escobedo Guerra MR, Guerra Infante FM. Persistence of *Chlamydia trachomatis* in endometrium and peritoneal fluid of infertile patients with negative cervical culture. *Ginecol Obstet Mex.* 2013;81:23–28.
59. Dueholm M, Lundorf E, Hansen ES, Ledertoug S, Olesen F. Evaluation of the uterine cavity with magnetic resonance imaging, transvaginal sonography, hysterosonographic examination, and diagnostic hysteroscopy. *Fertil Steril.* 2001;76:350–357.
60. Breitkopf DM, Frederickson RA, Snyder RR. Detection of benign endometrial masses by endometrial stripe measurement in premenopausal women. *Obstet Gynecol.* 2004;104:120–125.

61. Togashi K, Nishimura K, Itoh K, et al. Adenomyosis: Diagnosis with MR imaging. *Radiology*. 1988;166(1 Pt 1):111–114.
62. Exacoustos C, Brienza L, Di Giovanni A, et al. Adenomyosis: Three-dimensional sonographic findings of the junctional zone and correlation with histology. *Ultrasound Obstet Gynecol*. 2011;37:471–479.
63. Luciano DE, Exacoustos C, Albrecht L, et al. Three-dimensional ultrasound in diagnosis of adenomyosis: Histologic correlation with ultrasound targeted biopsies of the uterus. *J Minim Invasive Gynecol*. 2013;20:803–810.
64. Frank ML, Schafer SD, Mollers M, et al. Importance of transvaginal elastography in the diagnosis of uterine fibroids and adenomyosis. *Ultraschall Med*. 2016;37:373–378.
65. Liu X, Ding D, Ren Y, Guo SW. Transvaginal elastosonography as an imaging technique for diagnosing adenomyosis. *Reprod Sci*. 2018;25:498–514.
66. Mark AS, Hricak H, Heinrichs LW, et al. Adenomyosis and leiomyoma: Differential diagnosis with MR imaging. *Radiology*. 1987;163:527–529.
67. Munro MG. *Abnormal Uterine Bleeding*. Cambridge: Cambridge University Press; 2010:251.
68. Wamsteker K, Emanuel MH, de Kruif JH. Transcervical hysteroscopic resection of submucous fibroids for abnormal uterine bleeding: Results regarding the degree of intramural extension. *Obstet Gynecol*. 1993;82:736–740.