

THE ANGIOCARDIOGRAPHIC DIAGNOSIS OF A PERSISTENT TRUNCUS ARTERIOSUS IN A FOAL

P. F. STEYN*, PATRICIA HOLLAND** and J. HOFFMAN***

ABSTRACT

Persistent truncus arteriosus is a relatively rare cardiac anomaly which is associated with a single large artery arising from the ventricles. An interventricular septal defect is invariably present. The vessel gives origin to the pulmonary trunk, aorta and coronary arteries. A description of the angiocardio-graphic diagnosis of this condition is given as well as a general review of the relative developmental anatomy.

Key words: Foal, persistent truncus arteriosus, angiocardio-graphy, embryology, radiography, cardiac anomaly

Steyn P. F.; Holland P.; Hoffman J. **The angiocardio-graphic diagnosis of a persistent truncus arteriosus in a foal.** *Journal of the South African Veterinary Association* (1989) 60 No. 2, 106-108 (En.) Department of Radiology, Texas Veterinary Medical Center, Texas A&M University, College Station, Texas, 77843, United States of America

INTRODUCTION

In truncus arteriosus a single vessel arises from the ventricles above a ventricular septal defect and gives origin to systemic, coronary and pulmonary arteries⁵. The pulmonary arteries can originate at different levels: with a separate pulmonary trunk, with common origin of pulmonary arteries (but no pulmonary trunk) or with separate origin of the pulmonary arteries³. Both ventricles act as a common pumping chamber and eject blood at systemic pressure into the truncus where mixing of the venous and arterial blood occurs. Truncus arteriosus has been diagnosed in equines on post mortem examination^{2, 4}. Sojka⁶ discussed a case report of a foal with a persistent truncus arteriosus.

This report describes the ante mortem angiocardio-graphic diagnosis in a foal with a persistent truncus arteriosus with a pulmonary trunk arising separately from it.

CASE HISTORY

A quarter horse filly was presented immediately after birth to the Texas Veterinary Medical Center with dyspnoea and extreme exercise intolerance. On physical examination, a severe grade 5/6 holosystolic murmur was noted on both sides of the thorax. Tachypnoea and cyanosis were evident after ex-

ercise. On auscultation the lung fields were clear, the rectal temperature was 38,5°C, the pulse was 140 - 160 min⁻¹ and the respiration rate 60 - 80 min⁻¹.

Echocardiography demonstrated a high ventricular septal defect with dextro-positioning of the aorta. Right ventricular hypertrophy was suggested on the short axis view. The pulmonary trunk could not be identified.

When the filly was 3 weeks old a cardiac catheterisation and an angiocardio-graph were performed to aid in the diagnosis of the suspected cardiac anomaly. Anaesthesia was induced with 5% and maintained on 2,5 to 3,5% Isoflurane and oxygen. Survey lateral thoracic radiographs were taken to establish the radiographic exposure technique. Cardiac catheterisation with a size 7 cardiac catheter (Cordis GJ 7 French 80cm Cardiac Catheter Cordis Corporation, Miami, FL) was achieved via the right jugular vein. The tip of the catheter was guided into the right atrium per fluoroscopy (Picker P-600 Retro Fluoroscope, Bay Shore, NY) and was then passed through the ventricular septal defect into the left ventricle. Fifty-eight ml of contrast medium (Renografin-76, Squibb, Princeton, NJ) were injected through the catheter using an angiographic injector (Medrad Mark VI Angiographic Injector, Pittsburg, PA) at 24 ml sec⁻¹ at 32 kg cm⁻² with a delay time of 1 s. Rapid serial radiography was achieved by means of a Puck Rapid Film Changer (Elima-Schonander, Stockholm, Sweden). Opacification of the aorta was visible, as well as a blood vessel in the position where a patent ductus arteriosus would be expected (Fig 1). The catheter was then withdrawn and introduced into the right atrium where contrast material was injected with the rapid injector. Immediate opacification of the aorta and the patent ductus arteriosus-like vessel was observed; the same

angiocardio-graphic image of the major vessels leaving the heart was visible whether the contrast agent was injected into the left ventricle or the right atrium (Fig.2). The ascending aorta was noted with the dextroangiocardio-graph, and positive contrast agent was seen to shunt from the right atrium to the left atrium through an atrial septal defect. At no time was a pulmonary trunk seen to exit the right ventricle. Blood gasses and pressures were obtained (Table 1). The pressures in the right and left ventricles were essentially the same. The pO₂ concentration was highest in the left ventricle and higher in the aorta than in the right ventricle.

Angiocardio-graphic findings included a high ventricular septal defect, a functional patent foramen ovale and a common truncus arteriosus originating from the right ventricle and giving origin to the pulmonary trunk, aorta and the coronary arteries. Both ventricular free walls were of essentially the same thickness. At this stage, the diagnosis of a persistent truncus arteriosus was made. The foal was euthanased and a necropsy was performed. The right ventricle was moderately dilated and the right ventricular free wall was hypertrophied, measuring 19mm in thickness as compared to 16mm for the left ventricular free wall. A 14 x 31mm interventricular septal defect was located high in the muscular septum just adjacent to the atria and resulted in communication between the left and right ventricles. A single major arterial trunk left the heart, arising predominantly from the right ventricle, but slightly overriding the interventricular septum. This vessel had a functional valve with 3 well-developed leaflets. Coronary arteries branched from the truncus arteriosus near its origin in the vicinity of the valve. The pulmonary trunk branched from the truncus arteriosus approximately 70 mm from the base of the heart and gave rise to the left and right pulmonary arteries (Fig. 3). The brachio-cephalic trunk branched from the truncus arteriosus at about the same level as and opposite to the pulmonary trunk. A patent foramen ovale was also noted (Fig 4).

DISCUSSIONS

Embryologically the aorta and the pulmonary artery originate from the same structures: the bulbus and the truncus. Two prominent longitudinal thickenings (the bulbar ridges) arise from the endocardial lining during the early developmental stages in the heart. The bulbar ridges then meet and fuse, creating a septum that divides the truncus and the unabsorbed portion of the bulbus into an aorta and a pulmonary trunk. The ventricular septum develops from the base of the common ventricle and increases in height, thereby creating 2 ventricles. For a short time the septum is incomplete proximally where the interventricular foramen is situated. The proximal portion of the interventricular

* Department of Radiology, Texas Veterinary Medical Center, Texas A&M University, College Station, 77843 Texas, United States of America

** Department of Large Animal Medicine and Surgery

*** Department of Pathology

Received: August 1988 Accepted: December 1988

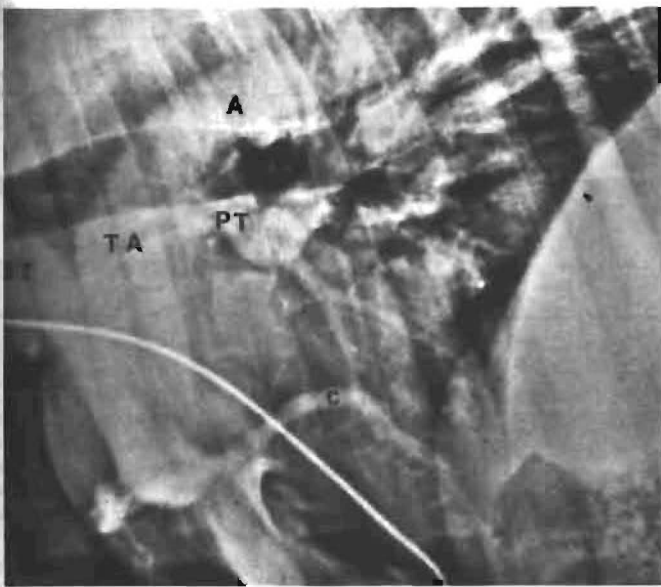


Fig. 1: Laevo-angiogram: the catheter tip is situated in the left ventricle. Note the opacification of the truncus arteriosus (TA), the coronary arteries (c), the pulmonary trunk (PT), the aorta (A), and the brachiocephalic trunk (BT)

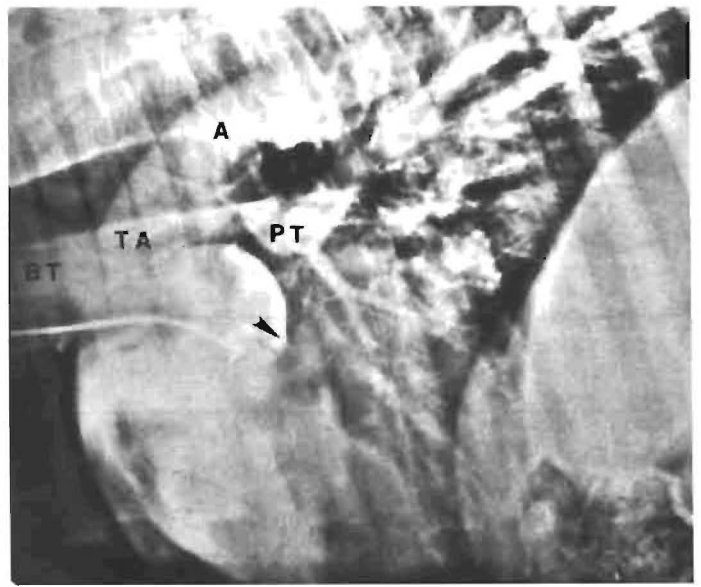


Fig. 2 Dextro-angiogram: the catheter tip is in the right atrium. Note the opacification of the right atrium, right ventricle, truncus arteriosus (TA), pulmonary trunk (PT), brachiocephalic trunk (BT), aorta (A) and the patent foramen ovale (arrow head). Compare this with Fig. 1 and note the resemblance. At no stage is a pulmonary trunk seen to originate from the right ventricle

Fig. 3: Necropsy specimen; the right ventricle has been opened. The forceps are situated in the pulmonary trunk originating from the truncus arteriosus (TA) and the scissors indicate the high ventricular septal defect. The origin of the brachiocephalic trunk (arrow head) and the aorta (A) are marked

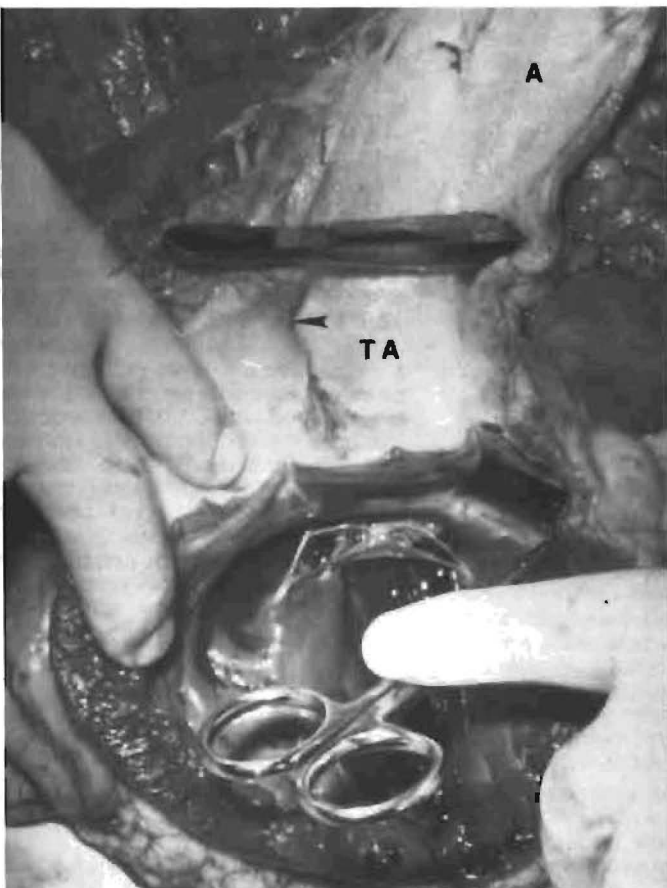


Fig 4 Necropsy specimen: the left ventricle (LV) has been opened. The scissors are located in the high ventricular septal defect and the probe (arrow) indicates the patent foramen ovale opening into the left atrium (LA). Note the absence of an ascending aorta originating from the left ventricle

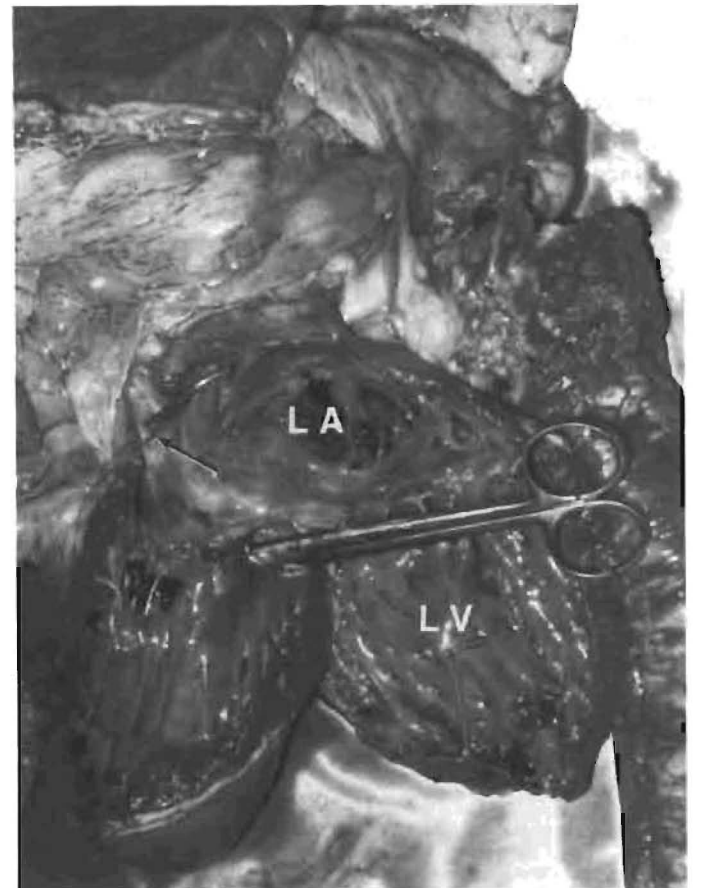


Table 1: Partial gas pressures, pH of the blood and systolic/diastolic pressures in the right ventricle, right atrium, aorta and left ventricle in a foal with persistent truncus arteriosus

	Right atrium	Right ventricle	Aorta	Left ventricle
pO ₂ mm Hg	39,8	39,9	52,9	60,8
pCO ₂ mm Hg	56,8	57,1	53,1	58,5
HCO ₃ mmol l ⁻¹	27,0	25,7	26,1	27,4
pH	7,285	7,262	7,301	7,280
Pressure mm Hg systolic/diastolic	15/10	90/9	70/5	91/10

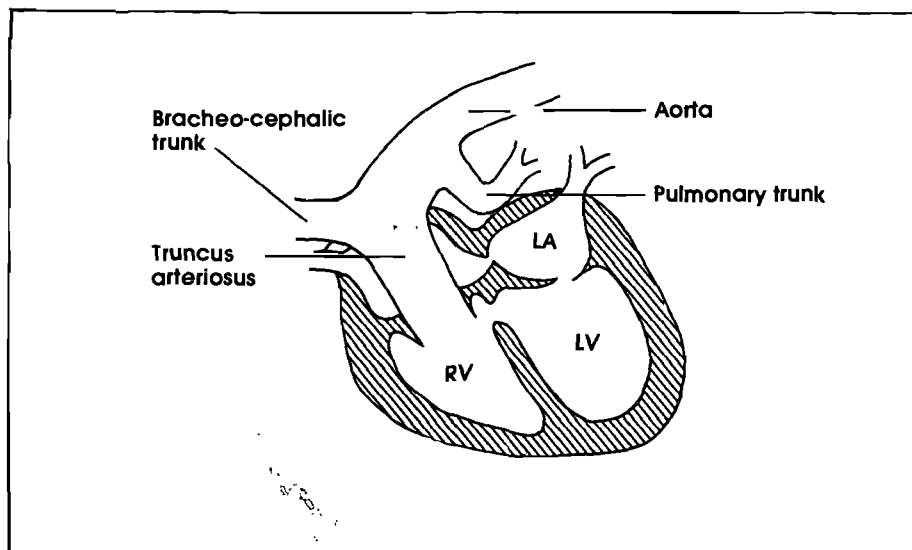


Fig. 5: Schematic drawing of the heart of a three-week-old foal with a persistent truncus arteriosus arising predominantly from the right ventricle (RV.) The high ventricular septal defect and atrial septal defect (patent foramen ovale) are not annotated. Left atrium (LA) and left ventricle (LV).

foramen later fuses with the proximal bulbar septum. The proximal part of the bulbus (which forms part of the pulmonary trunk) is incorporated into the right ventricle¹.

In this foal, apparent incomplete division of the proximal portion of the truncus and the bulbus resulted in a persistent truncus arteriosus overriding the ventricles, but situated predominantly over

the right ventricle (Fig 5). Because the bulbus was involved in this anomaly, the interventricular septum did not close; this resulted in the high ventricular septal defect.

The pO₂ of the aorta was higher than the pO₂ of the right ventricle because the oxygenated blood from the left ventricle followed the path of least resistance, i.e. up the truncus arteriosus and not into the

right ventricle per se because the pressures of these two chambers were equal. The high pressure in the right side of the heart was presumably responsible for the nonclosure of the foramen ovale in the atrial septum.

The ante mortem diagnosis of a persistent truncus arteriosus is most reliably made by angiocardiography. Echocardiography is often not rewarding in this condition⁷ and therefore it is important that angiocardiographic findings be well described and documented.

ACKNOWLEDGEMENT

The authors wish to thank Ms. Joni Elslander for her technical assistance.

REFERENCES

1. Arey L B 1966 Developmental Anatomy A Textbook and laboratory manual of embryology 7th edn W B Saunders Company, Philadelphia: 379-387
2. Bayly W M, Reed S M, Leathers C W, Brown C M, Traub J L, Paradis M R, Palmer G H 1982 Multiple congenital heart anomalies in five Arabian foals. *Journal of the American Veterinary Medical Association* 181: 684-689
3. Collet R W, Edwards J E 1949 Persistent truncus arteriosus: a classification according to anatomic types. *Surgical Clinics of North America*, 29: 1245
4. Greene H J, Wray D D, Greenway J A 1975 Two equine congenital cardiac anomalies. *Irish Veterinary Journal* 29: 115-117
5. Jefferson K, Rees S 1980 *Clinical Cardiac Radiology* 2nd edn Butterworths, London: 211-212
6. Sojka J E 1987 Persistent truncus arteriosus in a foal. *Equine Practice* 9: 19-26
7. Reef V B 1985 *Cardiovascular Disease in the neonate*. *Veterinary clinics of North America: Equine Practice* 1: 117-129