

Murine Model of Infection by *Tropheryma whipplei*

Séverine Genot,¹ Andreas Stein,¹ Hubert Lepidi,¹ Melanie Ihrig,²
Didier Raoult,¹ and Jean-Louis Mege^{1*}

Unité des Rickettsies, CNRS UMR 6020, Faculté de Médecine, Université de la Méditerranée, Marseille, France,¹ and
Department of Veterinary Pathology, College of Veterinary Medicine, Texas A&M University, College Station, Texas 77843²

Received 21 February 2006/Returned for modification 10 April 2006/Accepted 25 May 2006

We developed an animal model reproducing several aspects of Whipple's disease. Immunocompetent mice were persistently infected with *Tropheryma whipplei*, its etiological agent, and developed liver granulomas. SCID mice were infected similarly but did not develop tissue lesions. The delayed clearance of *T. whipplei* suggests a protective role for innate immunity.

Whipple's disease (WD) is a systemic bacterial infection characterized by fever, polyarthritides, lymphadenopathy, intestinal manifestations, and, occasionally, cardiac or ocular manifestations. Its diagnosis is based on the identification of infiltrating large foamy macrophages in duodenal biopsy specimens (10). In 2000, our group successfully cultured the agent of WD, officially named *Tropheryma whipplei* (11), and two strains were sequenced in 2003 (1, 12). WD is related to a defective host defense. Indeed, reduced secretion of interleukin-12 (IL-12) is observed in WD patients (9); it likely leads to diminished gamma interferon (IFN- γ) production by T cells and defective macrophage activation. In human macrophages, *T. whipplei* replication depends on IL-16 and requires down-modulation of the IL-12 pathway (5). This is emphasized in intestinal WD in which infiltrating macrophages exhibit an alternative transcription activation phenotype (4). The purpose of our study was to develop a murine model that would emulate human infection. For the first time, we describe *T. whipplei* infection in mice with bacterial persistence and tissue lesions. Such animal models will facilitate the investigation of WD pathogenesis.

T. whipplei organisms (strain Twist-Marseille) were cultured on MRC5 cell monolayers as described previously (5). Female 6-week-old immunocompetent mice (BALB/c mice) and CB-17 mice with severe combined immunodeficiency (SCID mice) were obtained from Charles River Labs (L'Arbresle, France). Mice were infected intravenously with 3×10^5 organisms or phosphate-buffered saline as a control. Animals were examined daily. Five infected mice and one control mouse of each group were sacrificed 4, 10, 20, 50, and 70 days after inoculation. Spleens, livers, hearts, brains, and gastrointestinal tracts were excised, and a part of each organ was stored at -80°C . The other part was fixed in Bouin's solution and embedded in paraffin. Sections of paraffin-embedded tissues (5 μm) were stained with hematoxylin-eosin. Granulomas were defined as a compact aggregate of at least five macrophages. For immunohistologic detection of *T. whipplei*, paraffin-embedded tissue sections were deparaffinized in xylene and rehy-

drated in graded alcohol. Each tissue section was incubated with rabbit antibodies to *T. whipplei* (diluted at 1:2,000). Bacteria were revealed using the Immunostain-Plus kit (Zymed, ClinSciencs, Montrouge, France) according to the manufacturer's instructions. The whole tissue area was examined, and infection was quantified using the image analyzer SAMBA 2005 (Alcatel, Grenoble, France) as previously described (7). The results are expressed as the number of bacteria found per mm^3 of tissue. Results were expressed as the means \pm standard deviations.

We demonstrated in this study that BALB/c mice can be infected with *T. whipplei*. The organisms were detected in liver and spleen, which is consistent with the sites of *T. whipplei* infection reported for WD patients (14). Moreover, hepatomegaly and/or splenomegaly has been observed in WD patients (6). Infected cells were randomly distributed throughout the hepatic parenchyma. Bacteria were detected at day 4 postinfection (about 50 organisms per mm^3 tissue) and were localized in both macrophages and sinusoidal cells, which were presumably Kupffer cells (Fig. 1A). Mice progressively cleared the organisms, which were undetectable in the liver at 70 days postinfection (Fig. 1B). Infection of the spleen remained minimal throughout the duration of the experiment (about 0.2 organism per mm^3 tissue), confirming the differences previously reported for hepatic and splenic immune responses to infection (2). Gastrointestinal tracts of BALB/c mice were not infected with *T. whipplei*, whereas small intestine containing lamina propria macrophages was the most dominant presentation of WD in humans. Morbidity and mortality of BALB/c mice were not observed up to 70 days postinfection. Note that organisms were not found in brain and their usual locations, such as the gastrointestinal tract and heart. No large foamy macrophages were seen in BALB/c mice in contrast to that seen in humans. The inoculation route did not account for such findings because intraperitoneal injection of *T. whipplei* induced a pattern of tissue infection similar to that induced by intravenous injection (data not shown). Small multifocal granulomas consisting mainly of macrophages and epithelioid cells were found in the liver of infected mice (Fig. 1C). Their number was low throughout the experiment (about four granulomas per mm^3 tissue). The spleen, gastrointestinal tract, heart, and brain did not exhibit any lesions, which may be related to the minimal, or lack of, colonization. In WD patients, besides

* Corresponding author. Mailing address: Unité des Rickettsies, Faculté de Médecine, Univ. de la Méditerranée, 27 Bld. Jean Moulin, 13385 Marseille Cedex 05, France. Phone: (33) 4 91 32 43 75. Fax: (33) 4 91 38 77 72. E-mail: Jean-Louis.Mege@medecine.univ-mrs.fr.

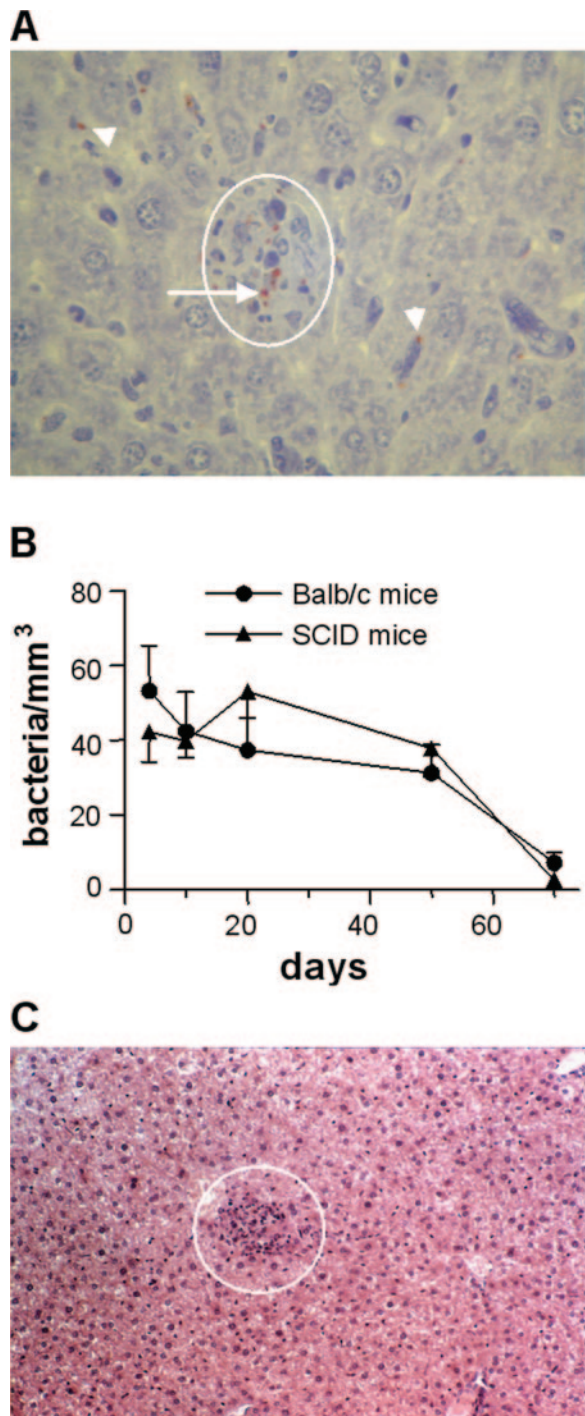


FIG. 1. *T. whipplei* burden and granuloma formation. (A) Infected BALB/c mice were killed at day 4. *T. whipplei* organisms were detected both in macrophages, which composed the granuloma (white circle) in liver parenchyma (arrowhead), and in spindle lining the hepatic sinusoids (arrows), which are presumably Kupffer cells. Magnification, $\times 250$. (B) Infected BALB/c mice and SCID mice were killed at different times. The infection of liver was determined by immunohistologic determination, and the results are the means \pm standard deviations for five mice per time point. (C) An inflammatory granuloma (white circle) in the liver of a mouse infected with *T. whipplei* is shown (hematoxylin-eosin). Magnification, $\times 250$.

the classical aggregation of foamy macrophages in intestinal tissue, the liver, lymph nodes, and spleen exhibit noncaseating, epithelioid cell granulomas. Diffuse granulomatous disease may characterize WD without obvious enteric symptoms or signs of disease (13, 15). The granulomatous lesions observed in our study were similar to the histologic lesions observed in sarcoidosis-like forms of WD (3). This is likely related to the early evolution of *T. whipplei* infection. Indeed, sarcoid-like reaction is an early manifestation of WD, and in mice, hepatic granulomas were observed 4 days after infection.

Surprisingly, SCID mice controlled *T. whipplei* infection as did BALB/c mice. We did not observe morbidity or mortality throughout the study. *T. whipplei* organisms were detected in the liver but not in the spleen, heart, brain, or intestinal tract. The bacterial burden was similar to that found in BALB/c mice at day 4; it decreased thereafter and was undetectable at day 70 (Fig. 1B), demonstrating that SCID mice are able to eliminate *T. whipplei* in a time frame similar to that for BALB/c mice. The infection of SCID mice was not associated with granulomas in the liver. That SCID mice and immunocompetent mice clear *T. whipplei* infection in similar ways suggests that *T. whipplei* does not behave as an opportunistic infectious agent. Because WD is characterized by a deficient IL-12/IFN- γ pathway (5, 8), one would expect that the T-cell deficiency of SCID mice and the concomitant impaired Th1 immune response would result in an increased susceptibility to *T. whipplei* infection. Yet, that is not what we observed in this study. It is possible that the low pathogenicity of *T. whipplei* accounts for its ability to control infection in the absence of adaptive immunity. Our findings also suggest, however, that IFN- γ produced by NK cells may be sufficient to control *T. whipplei* infection in mice.

In conclusion, the mouse model of *T. whipplei* infection reproduces several features of the human disease, including bacterial persistence and granulomatous lesions. The key differences are the self-limited nature of the infection, the granulomatous response and anatomical distribution of lesions, and the overall bacterial burden per granulomatous lesion. However, this model will enable more-comprehensive investigations of the pathophysiology of WD.

REFERENCES

- Bentley, S. D., M. Maiwald, L. D. Murphy, M. J. Pallen, C. A. Yeats, L. G. Dover, H. T. Norbertczak, G. S. Besra, M. A. Quail, D. E. Harris, A. von Herbay, A. Goble, S. Rutter, R. Squares, S. Squares, B. G. Barrell, J. Parkhill, and D. A. Relman. 2003. Sequencing and analysis of the genome of the Whipple's disease bacterium *Tropheryma whipplei*. *Lancet* **361**:637–644.
- Bowen, D. G., G. W. McCaughan, and P. Bertolino. 2005. Intrahepatic immunity: a tale of two sites? *Trends Immunol.* **26**:512–517.
- Cho, C., W. G. Linscheer, M. A. Hirschhorn, and K. Ashutosh. 1984. Sarcoidlike granulomas as an early manifestation of Whipple disease. *Gastroenterology* **87**:941–947.
- Desnues, B., H. Lepidi, D. Raoult, and J. L. Mege. 2005. Whipple disease: intestinal infiltrating cells exhibit a transcriptional pattern of M2/alternatively activated macrophages. *J. Infect. Dis.* **192**:1642–1646.
- Desnues, B., D. Raoult, and J. L. Mege. 2005. IL-16 is critical for *Tropheryma whipplei* replication in Whipple's disease. *J. Immunol.* **175**:4575–4582.
- Dutly, F., and M. Altwegg. 2001. Whipple's disease and "*Tropheryma whipplei*." *Clin. Microbiol. Rev.* **14**:561–583.
- Lepidi, H., F. Fenollar, R. Gerolami, J. L. Mege, M. F. Bonzi, M. Chappuis, J. Sahel, and D. Raoult. 2003. Whipple's disease: immunospecific and quantitative immunohistochemical study of intestinal biopsy specimens. *Hum. Pathol.* **34**:589–596.
- Marth, T., N. Kleen, A. Stallmach, S. Ring, S. Aziz, C. Schmidt, W. Strober, M. Zeitz, and T. Schneider. 2002. Dysregulated peripheral and mucosal Th1/Th2 response in Whipple's disease. *Gastroenterology* **123**:1468–1477.
- Marth, T., M. Neurath, B. A. Cuccherini, and W. Strober. 1997. Defects of

- monocyte interleukin-12 production and humoral immunity in Whipple's disease. *Gastroenterology* **113**:442–448.
10. **Marth, T., and D. Raoult.** 2003. Whipple's disease. *Lancet* **361**:239–246.
 11. **Raoult, D., M. L. Birg, B. La Scola, P. E. Fournier, M. Enea, H. Lepidi, V. Roux, J. C. Piette, F. Vandenesch, D. Vital-Durand, and T. J. Marrie.** 2000. Cultivation of the bacillus of Whipple's disease. *N. Engl. J. Med.* **342**:620–625.
 12. **Raoult, D., H. Ogata, S. Audic, C. Robert, K. Suhre, M. Drancourt, and J. M. Claverie.** 2003. *Tropheryma whippelii* Twist: a human pathogenic Actinobacteria with a reduced genome. *Genome Res.* **13**:1800–1809.
 13. **Rodarte, J. R., C. O. Garrison, K. E. Holley, and R. S. Fontana.** 1972. Whipple's disease simulating sarcoidosis. A case with unique clinical and histologic features. *Arch. Intern. Med.* **129**:479–482.
 14. **Rouillon, A., C. J. Menkes, J. C. Gerster, I. Perez-Sawka, and M. Forest.** 1993. Sarcoid-like forms of Whipple's disease. Report of 2 cases. *J. Rheumatol.* **20**: 1070–1072.
 15. **Southern, J. F., R. A. Moscicki, C. Magro, G. R. Dickersin, J. T. Fallon, and K. J. Bloch.** 1989. Lymphedema, lymphocytic myocarditis, and sarcoidlike granulomatosis. Manifestations of Whipple's disease. *JAMA* **261**: 1467–1470.

Editor: J. L. Flynn