



THE AGA KHAN UNIVERSITY

eCommons@AKU

Department of Anaesthesia

Medical College, Pakistan

June 2018

Pre-anaesthetic assessment of intracranial pressure using optic nerve sheath diameter in patients scheduled for elective tumour craniotomy

Faraz Shafiq

Aga Khan University, faraz.shafiq@aku.edu

Muhammad Asghar Ali

Aga Khan University

Fauzia Khan

Aga Khan University, fauzia.khan@aku.edu

Follow this and additional works at: https://ecommons.aku.edu/pakistan_fhs_mc_anaesth



Part of the [Anesthesiology Commons](#)

Recommended Citation

Shafiq, F., Ali, M. A., Khan, F. (2018). Pre-anaesthetic assessment of intracranial pressure using optic nerve sheath diameter in patients scheduled for elective tumour craniotomy. *Journal of Ayub Medical College*, 30(2), 151-154.

Available at: https://ecommons.aku.edu/pakistan_fhs_mc_anaesth/343

ORIGINAL ARTICLE

PRE-ANAESTHETIC ASSESSMENT OF INTRACRANIAL PRESSURE USING OPTIC NERVE SHEATH DIAMETER IN PATIENTS SCHEDULED FOR ELECTIVE TUMOUR CRANIOTOMY

Faraz Shafiq, Muhammad Asghar Ali, Fauzia Anis Khan

Department of Anaesthesiology, Aga Khan University, Karachi-Pakistan

Background: The objective of study was to determine the pre-anaesthetic status of intracranial pressure (ICP), using ultrasonographic measurement of optic nerve sheath diameter (ONSD) in patient scheduled for elective tumour craniotomy. The secondary objective was to compare the diagnostic accuracy of ONSD guided rise in ICP with clinical and radiographic parameters. This is prospective observational study, conducted at single neurosurgical theatre of The Aga Khan University over a period of one year. **Methods:** After getting ethical approval and informed consent patient fulfilling inclusion criteria and planned for elective tumour craniotomy were enrolled in study. The clinical and radiographic signs predicting the status of ICP were recorded. The ultrasonographic measurement of ONSD was done using liner array probe. Value more than 5 mm was considered as abnormal. **Results:** Total 26 cases were enrolled. Seventy percent patients showed rise in ICP based on clinical parameters, while 65% diagnosed to have raised ICP on the basis of radiographic findings. The ultrasonographic measurement of ONSD predicted this rise in 61% of cases. The diagnostic accuracy of ONSD in detecting raised ICP in comparison to clinical and radiographic evidence was 87.5% respectively. **Conclusion:** The ultrasonographic-guided ONSD was used successfully for predicting the status of ICP in pre-induction phase of anaesthesia. It also showed good correlation in diagnosing rise in ICP as compared to clinical and radiographic parameters, which indicates that test can be used reliably in preoperative period for patients planned for tumour craniotomy.

Keywords: Craniotomy; Intracranial pressure; Optic nerve

Citation: Shafiq F, Ali MA, Khan FA. Pre-anaesthetic assessment of intracranial pressure using optic nerve sheath diameter (ONSD) in patients scheduled for elective tumour craniotomy (An observational study). *J Ayub Med Coll Abbottabad* 2018; 30(2):151-4

INTRODUCTION

Raised intracranial pressure (ICP) is a frequent problem in neurological patients presenting with mass-occupying lesion, management of which is directly related to outcome.¹ The aetiology behind this rise is either a direct compressing effect of lesion or due to obstructive hydrocephalus. It is difficult to predict the exact status of ICP in immediate preoperative period, and anaesthetists have to rely on clinical correlates like headache, nausea and vomiting or visual disturbances. Though these parameters are helpful at times but their consistency with severity of disease is questionable.² The significance of routinely performed CT/MRI scans is also reported to be compromised because of the fact that they only give us a snap shot information.³

The optic nerve sheath diameter (ONSD) as measured by ultrasound has shown good correlation clinically as well as with laboratory evidence of raised ICP.⁴ The test being non-invasive, simple and safe and can be repeated at bedside.⁵ We hypothesized that ultrasonographic measurement of ONSD preoperatively, is a simple and safe tool to predict the exact status of ICP. The primary objective of our study was to determine the pre-anaesthetic status of ICP using ultrasonographic measurement of ONSD in patients

scheduled for elective tumour craniotomy. The secondary objective was to compare the diagnostic accuracy of ONSD guided rise in ICP with clinical and radiographic parameters in these patients.

MATERIAL AND METHODS

After taking institutional ethical approval and informed consent from patients we conducted this observational study over a period of one year in single neurosurgical operating room of The Aga Khan University Hospital, Pakistan. Three consultants regularly involved in provision of neuro-anaesthesia services participated in study. The group underwent two simulated sessions on ultrasonographic measurement of ONSD. The duration of simulated session was of thirty minute each, which was done on healthy volunteers supervised by a consultant radiologist. Sampling technique was convenient. Patients scheduled for elective craniotomy for excision of mass occupying lesion were enrolled. While patients having any ophthalmic condition or preoperative Glasgow Coma Scale (GCS) of less than 8 were excluded.

On arrival of patient in operating room, routine American Society of Anaesthesiologists (ASA) specified monitoring (non-invasive blood pressure,

electrocardiography (ECG) and oxygen saturation) was instituted. The patient's demographics as well as relevant clinical information about tumour location were also recorded. Symptoms of headache, nausea/vomiting, visual disturbances or lethargy were recorded to predict the status of ICP. The perioperative CT/MRI that were done in last 24-48 hours were also reviewed and discussed with the surgical team to judge the status of ICP. The final recommendations of whether it raised or not was at the discretion of consultant, as judged by history, clinical and radiographic finding. This was documented on the data collection form.

The standard recommendations were followed for the measurement of ONSD.⁶ A Mindray ultrasound machine (Mindray, Diagnostic Ultrasound System, Model M 7, China 2012) with a 7.5 MHz linear array probe was used for measurement. The patients were asked to close their eyes, and a water-based non-irritant gel was applied to the upper eyelid. The OPNS diameter was measured 3 mm posterior to the globe. Value range more than 5.0 mm was considered as abnormal.⁵ Two observations from each eye were taken and the final value was calculated as a mean.

Data was recorded and analysed using SPSS Inc., Chicago, IL and OpenEpi (version 3.01) [http://www.openepi.com]. Demographic data was summarized as mean ± standard deviation for numeric data and frequency and percentages were computed for categorical data. Sensitivity, specificity, positive predictive value (PPV), negative predictive value (NPV) and diagnostic accuracy for ultrasonographic measurement of ONSD in detection of raised ICP against radiological investigations and clinical parameter were estimated with 95% confidence interval. The chance corrected level of agreement between ONSD with radiological investigations and clinical parameter were assessed using an inter agreement Kappa Statistics (Cohen, 1960) with 95% confidence interval.

RESULTS

Total of 26 cases were included in the study. The average age of the patients was 41.04 (SD±15.66) years (range 15-74). The tumour was supra tentorial in 88.5% of patients. In only 3 cases (12%) tumour was infra tentorial. Headache was the frequent complaint at the time of arrival to operating suite. Seventy six percent patients were taking dexamethasone and 61% of patients were being administered mannitol (Table-1). The assessment of ICP was done subjectively using clinical parameters and radiographic evidence while ultrasound guided OPNS diameter was used as an objective evidence of rise in ICP. Seventy percent of patients showed a rise in ICP based on clinical

parameters. While in 65% of patients ICP was said to be raised on the basis of radiographic evidence. The ultrasonographic measurement of ONSD predicted this rise in 61% of cases (Figure-1).

The diagnostic accuracy of ONSD guided prediction of raised ICP was 87.5%. This is in comparison to both radiographic as well as clinical parameters. The sensitivity, positive and negative predictive values of ONSD were above 80% when we compared it to radiographic evidence, while specificity was low (66.67%). Kappa statistics (k=0.71, 95% CI: 0.33-1.09) showed high agreement between OPNS and radiographic evidence (Table-2).

The comparison of ONSD with clinical parameters revealed sensitivity, specificity and positive predictive values more than 80%. The negative predictive value was low 66.67%. The kappa statistics [k=0.64, 95% CI: 0.25 to 1.04] showed moderate agreement between ONSD and clinical parameters (Table-2).

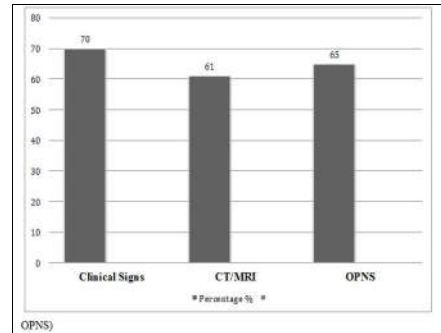


Figure-1 Rise in ICP as diagnosed by three different modalities (clinical signs, CT/MRI)

Table-1: Demographic, symptoms and medications (n=26)

Age (Years), mean (SD)	41.04 (15.66)	
Gender	n	%
Male	13	(50)
Female	13	(50)
Type of Tumor		
Supratentorial	23	(88.5)
Infratentorial	3	(11.5)
Symptoms		
Headache	19	(73.1)
Nausea	8	(30.8)
Vomiting	7	(26.9)
Visual Disturbances	6	(23.1)
Lethargy	5	(19.2)
Medication		
Mannitol	16	(61.50)
Dexamethasone	20	(76.90)

Data presented as mean and n (%)

Table-2: Comparison of ONSD guided diagnosis of rise in ICP compared with diagnosis by radiological investigation investigations and clinical parameters

Statistics	Rise in Intracranial pressure (ICP)			
	OPNS versus CT/MRI Finding		OPNS versus Clinical Parameters	
	Estimate	95% CIs	Estimate	95% CIs
Sensitivity	100%	(79.61, 100)	89.47%	(68.61, 97.06)
Specificity	66.67%	(35.42, 87.94)	80%	(37.55, 96.38)
Positive Predictive Value	83.33%	(60.78, 94.16)	94.44%	(74.24, 99.01)
Negative Predictive Value	100%	(60.97, 100)	66.67%	(30, 90.32)
Diagnostic Accuracy	87.5%	(69, 95.66)	87.50%	(69, 95.66)
Cohen's kappa	0.71	(0.33-1.09)	0.64	(0.25-1.04)
Diagnostic Odd ratio	NA		34	(2.436-474.6)
Bias Index	12.5%		-4.2%	

DISCUSSION

With the implementation of ultrasonography in anaesthetic practice, things are now moving towards anatomical description rather than landmark technique. The ONSD diameter measurement is one such technique, where the status of intracranial pressure can be judged non-invasively and repeatedly. Patients planned for tumour craniotomy needs to be assessed critically at induction of anaesthesia for status of their ICP. The test can be done easily with reasonable reliability at the bedside in spontaneously breathing patients.⁷ Though the results of our study showed good correlation between clinical and radiographic evidence of rise in ICP using ONSD, however as mentioned clinical signs may be unreliable or difficult to assess especially in patients with low GCS. The radiological investigations show the status in retrospect that is when taken.

The advantage of ONSD measurement over other techniques is easy to perform and can be done immediately at induction of anaesthesia. Similarly, the technique can be employed for assessment in scenarios where patient present with low GCS.⁸ Several studies have mentioned the promising impact of this measurement tool during perioperative period. Dubost *et al* used ONSD to assess the cranial involvement in pre-eclamptic patients.⁹ Similarly the technique has shown to be beneficial where immediate status of intracranial pressure needs to be determined. In the study conducted by Chin *et al*, ONSD was used to predict ICP, where patients were positioned head down during radical prostatectomy.¹⁰ After finding good correlation, they recommended it for this clinical setting.

In our study, most of patients were on anti-oedema prescription. Despite this almost 61% were found to have raised ICP. It means that the conventional approach of evaluating these patients preoperatively was questionable. The diagnostic accuracy of ONSD in comparison to radiographic evidence in our study is consistent with the results of

Tayal VS *et al*.¹¹ This study was conducted in head injury patients admitted to emergency room. Patients were assessed clinically while immediate CT scan of head, were also ordered to evaluate the status of ICP. The ultrasonographic measurement of ONSD was 100% sensitive while 65% specific in detecting rise in ICP. The good correlation with the radiographic evidence in our study may be due to the fact that in our institution it is routine to have immediate perioperative MRI before tumour craniotomy. However, Golshani *et al*¹² reported that ONSD was 100% sensitive and 31.9% specific in determining the status of ICP. This could be due to the difference in their patient population from ours as they have included neuro-trauma patients only. The meta-analysis conducted by Dubuorg *et al*,¹³ which included six studies and 261 patients also showed convincing results in terms of diagnostic accuracy (sensitivity 90%, specificity 80%) and decision making by using ONSD.

In recent studies, the researchers are finding further role of this technique in term of patients' outcome and risk stratification. In a study conducted by Chelly *et al*, ONSD was successful in determining the mortality outcome in post cardiac arrest patients his again reinforces the significance of this tool in acute clinical scenarios.¹⁴ Similarly Dobust C *et al* monitored the success of epidural blood patch through raised in ICP as monitored by ONSD.¹⁵

An important role of this technique in resource-limited setups.¹⁶ Advanced radiological facilities like MRI may not be available in many of our district hospitals however, ultrasound equipment is. With the help of ONSD measurement the status of ICP can easily be judged in the immediate preoperative period and anaesthetic techniques can hence be modified. Furthermore, ONSD measurement can be incorporated as a part of pre-induction checklist for patients scheduled for tumour craniotomy.

A major limitation of our study was the absence of blinding which may have added a bias to results. We suggest further randomized controlled

trial in perioperative setting to come up with further evidence. The future studies should see the extended role of this technique throughout the perioperative period including the risk stratification and outcome benefits.

CONCLUSION

The ultrasound guided ONSD was used successfully for the prediction of ICP in pre-induction phase of anaesthesia. It showed good correlation in diagnosing rise in ICP as compared to clinical and radiological parameters. The diagnostic accuracy in both the clinical versus radiological scenarios was more than 87 %. It indicates that this test can be used with significant reliability in immediate preoperative period for patients scheduled for tumour craniotomy.

AUTHORS' CONTRIBUTION

FS: Basic concept, Study designing and write-up.
 MAA: Data collection, Proof reading and submission.
 FAK: Study designing, write-up.

REFERENCES

1. Vahedi K, Hofmeijer J, Juettler E, Vicaut E, George B, Algra A, *et al.* Early decompressive surgery in malignant infarction of the middle cerebral artery: a pooled analysis of three randomised controlled trials. *Lancet Neurol* 2007;6(3):215–22.
2. Dunn LT. Raised intracranial pressure. *J Neurol Neurosurg Psychiatry* 2002;73(Suppl 1):i23–7.
3. Hiler M, Czosnyka M, Hutchinson P, Balestreri M, Smielewski P, Matta B, *et al.* Predictive value of initial computerized tomography scan, intracranial pressure, and state of autoregulation in patients with traumatic brain injury. *J Neurosurg* 2006;104(5):731–7.
4. Moretti R, Pizzi B. Ultrasonography of the optic nerve in neurocritically ill patients. *Acta Anaesthesiol Scand* 2011;55(6):644–52.
5. Roque PJ, Wu TS, Barth L, Drachman D, Khor KN, Lovecchio F, *et al.* Optic nerve ultrasound for the detection of elevated intracranial pressure in the hypertensive patient. *Am J Emerg Med* 2012;30(8):1357–63.

6. Tintinalli JE, Stapczynski JS, Ma OJ, Cline DM, Cydulka RK, Meckler GD. *Tintinalli's Emergency Medicine: A Comprehensive Study Guide*, 7th ed. New York: McGraw Hill; 2011.
7. Weidner N, Bomberg H, Antes S, Meiser A, Volk T, Groesdonk HV. Real-time evaluation of optic nerve sheath diameter (ONSD) in awake neurosurgical patients. *Intensive Care Med Exp* 2015;3(51):A608.
8. Amini A, Eghtesadi R, Feizi AM, Mansouri B, Kariman H, Dolatabadi AA *et al.* Sonographic Optic Nerve Sheath Diameter as a Screening Tool for Detection of Elevated Intracranial Pressure. *Emerg (Tehran)* 2013;1(1):15–9.
9. Dubost C, Le Gouez A, Jouffroy V, Roger-Christoph S, Benhamou D, Mercier FJ, *et al.* Optic nerve sheath diameter used as ultrasonographic assessment of the incidence of raised intracranial pressure in preeclampsia: a pilot study. *Anesthesiology* 2012;116(5):1066–71.
10. Verdonck P, Kalmar AF, Suy K, Geeraerts T, Vercauteren M, Mottrie A, *et al.* Optic nerve sheath diameter remain constant during robot assisted laparoscopic radical prostatectomy. *PLoS One* 2014;9(11):e111916.
11. Tayal VS, Neulander M, Norton HJ, Foster T, Saunders T, Blaivas M. Emergency department sonographic measurement of optic nerve sheath diameter to detect findings of increased intracranial pressure in adult head injury patient. *Ann Emerg Med* 2007;49(4):508–14.
12. Golshani K, Ebrahim ZM, Farajzegan Z, Khorvash F. Diagnostic Accuracy of OpticNerve Ultrasonography and Op hthalmoscopy in Prediction of Elevated Intracranial Pressure. *Emerg (Tehran)* 2015;3(2):54–8.
13. Dubourg J, Javouhey E, Geeraerts T, Messerer M, Kassai B. Ultrasonography of optic nerve sheath diameter for detection of raised intracranial pressure: a systematic review and meta-analysis. *Intensive Care Med* 2011;37(7):1059–68.
14. Chelly J, Deye N, Guichard JP, Vodovar D, Vong L, Jochmans S, *et al.* The optic nerve sheath diameter as useful tool for early prediction of outcome after cardiac arrest. A prospective pilot study. *Resuscitation* 2016;103:7–13.
15. Dubost C, Le Gouez A, Zetlaoui PJ, Benhamou D, Mercier FJ, Geeraerts T. Increase in optic nerve sheath diameter induced by epidural blood patch: a preliminary report. *Br J Anaesth* 2011;107(4):627–30.
16. Sippel S, Muruganandan K, Levine A, Shah S. Review article: Use of ultrasound in the developing world. *Int J Emerg Med* 2011;4:72.

Received: 23 February, 2017

Revised: --

Accepted: 9 March, 2018

Address for Correspondence:

Faraz Shafiq, Department of Anaesthesiology, Aga Khan University, Stadium road, Karachi-Pakistan

Email: faraz.shafiq@aku.edu