



THE AGA KHAN UNIVERSITY

eCommons@AKU

Section of Otolaryngology, Head & Neck Surgery

Department of Surgery

July 2019

The association between morphological characteristics of palatal rugae and sagittal skeletal patterns.

Farheen Fatima

Mubassar Fida

Follow this and additional works at: https://ecommons.aku.edu/pakistan_fhs_mc_surg_otolaryngol_head_neck

The Association between Morphological Characteristics of Palatal Rugae and Sagittal Skeletal Patterns

Farheen Fatima, Mubassar Fida

Abstract

Introduction: To find the association between the morphological characteristics of palatal rugae and sagittal skeletal patterns.

Methods: The retrospective charts review was conducted at the Aga Khan University Hospital from April to June 2016, and comprised data obtained from the pretreatment dental cast of orthodontic patients visiting the dental clinics over 5 years from 2011 to 2015. The sample was divided equally in three malocclusion groups based on sagittal skeletal relationship Class I, Class II and Class III. The number of palatal rugae was recorded for both right and left sides. Morphological features of the three anterior most primary rugae were recorded for the length, pattern and orientation bilaterally. SPSS 20 was used to compare the number and lengths as well as the pattern and orientation of palatal rugae among the groups.

Results: Of the 165 subjects, there were 55(33.3%) in each of the three groups. Significant differences were recorded in rugae lengths among the groups at ruga 1 on both sides and rugae 2 and 3 on the left side ($p < 0.05$ each). There were significant differences in the palatal rugae patterns among the groups ($p < 0.05$) except at rugae 2 and 3 on the left side ($p > 0.05$). Orientation showed significant differences at ruga 2 on the right side ($p = 0.02$).

Conclusions: No specific pattern was associated with any skeletal pattern. Further studies are required to evaluate three-dimensional characteristics of rugae to assess the association between palatal rugae and sagittal skeletal patterns.

Keywords: Palatal rugae, Dental cast, Sagittal skeletal pattern. (JPMA 69: 939 2019)

Introduction

Palatal rugae are small projections of variable pattern on the anterior part of palatal mucosa behind the incisive papilla on each side of median palatal raphe.¹ They are relatively prominent, symmetric and occupy most of the length of palatal shelves during the embryonic stage of development. They are five to seven in number, and the anterior rugae begin near the median palatal raphe whereas the posterior ones lie more laterally.² Their formation occurs via complex epithelial-mesenchymal interactions with the expression of specific extracellular matrix molecules in the spatiotemporal manner. By the end of intrauterine life, the prominence reduces and the patterns turn into less regular and asymmetric in form.

Histologically, they are formed by connective tissue base and surface layer of parakeratinised squamous epithelium.³

The palatal rugae assist during oral swallowing, speech and suction in children. They improve contact between food and taste receptors located on the dorsal surface of the tongue, resulting in better sensibility of taste.^{4,5} In recent years, several studies have been conducted related to the molecular basis of the formation of palatal rugae.^{6,7,8} The pattern may vary from simple to complex and is largely governed by the genetic factors. Variable results have been observed in the studies of their inheritance pattern.^{9,10} Twin and familial studies of palatal rugae suggested a substantial hereditary component, but this varies to different extents in various investigations.⁹⁻¹² Due to their protected location in the oral cavity, they are least likely to be affected by trauma, chemicals and heat; even if they are wounded they are repaired on the same

.....
The Aga Khan University Hospital, Karachi, Pakistan.

Correspondence: Farheen Fatima. e-mail: farheen_fatimas@hotmail.com

site. After mass calamities, traffic accidents or terrorism activities, the identification of an individual is facilitated by the identification of palatal rugae that is as reliable as the fingerprints.¹³ The rugae serve as a stable reference landmark to quantify the incisor retraction after orthodontic treatment on the dental cast.¹³ The eruption or loss of teeth and orthodontic treatment has little effect on the pattern and the orientation of the ridges. Strong genetic contribution has been reported for dental and skeletal malocclusion susceptibility as well.^{14,15}

The sagittal skeletal relationship is established during adolescence at which time usually the growth spurt is near to its end, especially in females in whom growth completion occurs earlier compared to the males. It would be of great benefit if the sagittal pattern of the patient can be anticipated at an earlier time when the growth could be facilitated in a favourable direction using growth modification appliances. Early treatment provides maximum skeletal effects compared to the treatment which is started later once the sagittal pattern has already been established. Once the growth spurt completes, the functional appliance therapy usually results in dental changes camouflaging the actual skeletal discrepancy whereas patients with severe discrepancies may require surgical intervention. Early diagnosis could be facilitated by finding its association with the structures that are established during the early growth period. The early establishment and stability of rugae have been extensively evaluated in the past, but only one study has been conducted to evaluate its association with sagittal skeletal pattern.¹⁷ Due to the ethnic variation in the palatal rugae pattern, the current study was planned to evaluate the association of morphological characteristics of rugae in different sagittal skeletal patterns in the local population.

Materials and Methods

The retrospective charts review was conducted at the Aga Khan University Hospital from April to June 2016, and comprised data obtained from the pretreatment dental cast of orthodontic patients visiting the dental clinics over 5 years from 2011 to 2015. Approval was obtained from the ethical review committee of Aga Khan University Hospital, Karachi. The sample size was calculated based on the findings of a study¹⁷ which reported the mean number of primary palatal rugae on the left side to be 3.63 ± 0.70 , 3.57 ± 0.85 and 3.46 ± 0.89 in skeletal Class I, II and III, respectively. The power and alpha were kept as

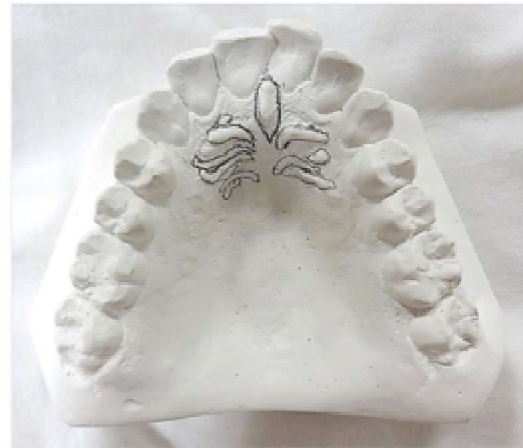

Figure-1: Palatal rugae.

80% and 0.05, respectively. Data were obtained from the pretreatment dental cast (white orthodontic stone, International Organisation for Standardisation [ISO] type 3) of orthodontic patients visiting the dental clinics. Data of all subjects aged 12-30 years with well-established molar and incisor relationships and permanent dentition till second molars were included. Data excluded related to subjects with a history of craniofacial and dental anomalies, extraction or previous orthodontic treatment, pathology or trauma in the region of interest, and with habits such as thumb-sucking or tongue thrusting. The data was divided into three study groups on the basis of sagittal skeletal pattern as Class I: A point, nasion, B point (ANB) angle 0° - 4° ; Class II: ANB angle $>4^\circ$; Class III: ANB angle $<0^\circ$. The palatal rugae were bordered using a sharp hard-black (HB) pencil under suitable light and magnification (Figure 1). The length of each ruga was measured using digital vernier calipers (0-150 mm ME00183, Dentaurum, Pforzheim, Germany). The accuracy of the caliper was 0.02mm and reliability 0.01mm as per the manufacturer.

The palatal rugae were classified on the basis of length as primary rugae >5 mm, secondary rugae 3-5 mm and fragmentary <3 mm.³ The number was totalled for each type on both right and left sides.

The cast was evaluated to determine the pattern and orientation based on classification defined in literature.¹ The three anterior primary rugae were recorded for the length, pattern and orientation (Figure 2).

Data was analysed using SPSS 20. The intra-examiner reliability was assessed using intra-class correlation coefficient. The normality of data was tested using Shapiro-

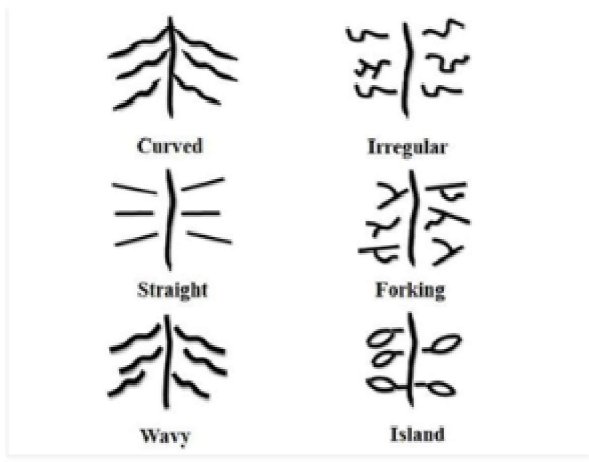


Figure-2: Pattern of palatal rugae: Curved, crescent shape with gentle curve; straight, straight directly from their origin to termination; wavy, serpentine with a slight curve at the origin or termination; forking, two rugae that joined at their origin or termination; island, definite continuous ring formation at the termination, irregular; broken, irregular pattern.

Wilk test, which showed a non-normal distribution. Therefore, non-parametric tests were applied. The Mann-Whitney U test was applied to compare the study parameters between genders. Median and inter-quartile range (IQR) were calculated for palatal rugae number and lengths. Kruskal-Wallis test was used to compare their differences among the groups. Frequencies were calculated for palatal rugae patterns and orientation. Chi-square test was used to compare the patterns and

orientation across the three groups. $P \leq 0.05$ was considered statistically significant.

Results

Of the 165 subjects, there were 55(33.3%) in each of the three groups. The overall mean age was 18.03 ± 5.4 years. The characteristics of palatal rugae were re-evaluated on 20 models 1 month after the initial assessment. The results showed excellent agreement between the two sets of readings. The comparison of number of palatal rugae, and length, pattern and orientation of primary rugae between male and female groups showed non-significant differences ($p > 0.05$). Therefore, to conserve the power of study, data was not divided on the basis of gender for statistical analysis. There was statistically nonsignificant difference in the number of rugae among the skeletal groups except the fragmentary rugae on right side (Table 1).

There were significant differences in rugae lengths among the groups at rugae 1 on both sides and rugae 2 and 3 on the left side ($p < 0.05$) (Table 2). The frequency of different patterns of primary rugae in each malocclusion was also noted (Figure 3). There were statistically significant differences in the pattern among the groups except at rugae 2 and 3 on the left side ($p \leq 0.05$). The distribution of orientation of the rugae showed no significant difference for palatal rugae except at rugae 2 on right side ($p = 0.02$) (Figure 4).

Table-1: Comparison of number of palatal rugae among malocclusion groups.

Number of Rugae		Skeletal Class						p-value
		Class I (n=55)		Class II (n=55)		Class III (n=55)		
		Median	IQR	Median	IQR	Median	IQR	
Primary	Right	4	3 - 5	4	3 - 4	4	3 - 4	0.16
	Left	4	3 - 5	4	3 - 4.5	4	3 - 5	0.35
Secondary	Right	1	0 - 1	1	0.5 - 2	1	0 - 2	0.24
	Left	1	0 - 1	1	1 - 2	1	0 - 1	0.35
Fragmentary	Right	0	0	0	0 - 1	1	0 - 1	0.003*
	Left	0	0 - 1	0	0 - 1	1	0 - 1	0.97

n = 165; Kruskal-Wallis test, * $p \leq 0.05$, IQR - Inter-quartile range.

Table-2: Comparison of lengths of palatal rugae among malocclusion groups.

Length of Primary Rugae (mm)		Skeletal Class						p-value
		Class I (n=55)		Class II (n=55)		Class III (n=55)		
		Median	IQR	Median	IQR	Median	IQR	
1st	Right	8.13	7.34 - 8.72	8.79	7.72 - 9.49	8.68	7.59 - 9.39	0.03*
	Left	9.01	7.44 - 9.91	9.47	8.47 - 10.35	8.99	8.36 - 9.90	0.003*
2nd	Right	8.76	6.88 - 11.09	9.57	7.74 - 10.35	9.53	8.34 - 10.72	0.73
	Left	8.38	6.88 - 9.78	9.42	7.23 - 10.62	10.05	7.56 - 11.33	0.01*
3rd	Right	9.64	8.22 - 11.90	11.03	8.24 - 12.42	11.69	9.15 - 12.58	0.17
	Left	10.51	8.82 - 11.75	10.27	8.82 - 11.80	12.48	10.25 - 13.71	0.004*

n = 165; Kruskal-Wallis test, * $p \leq 0.05$, IQR - Inter-quartile range.

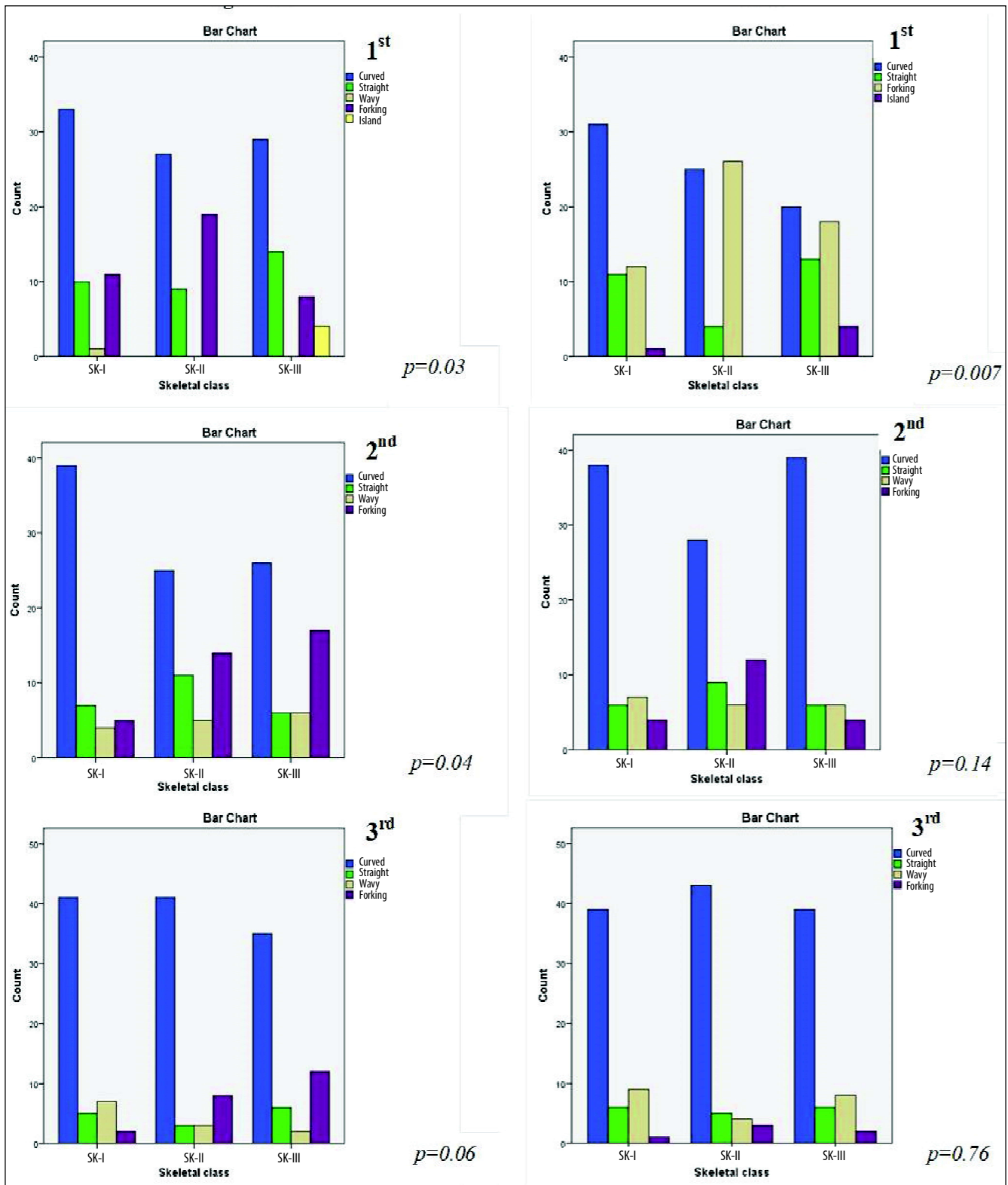


Figure-3: Comparison of pattern of primary palatal rugae among malocclusion groups. n=165, Chi-square test: *p≤0.05.

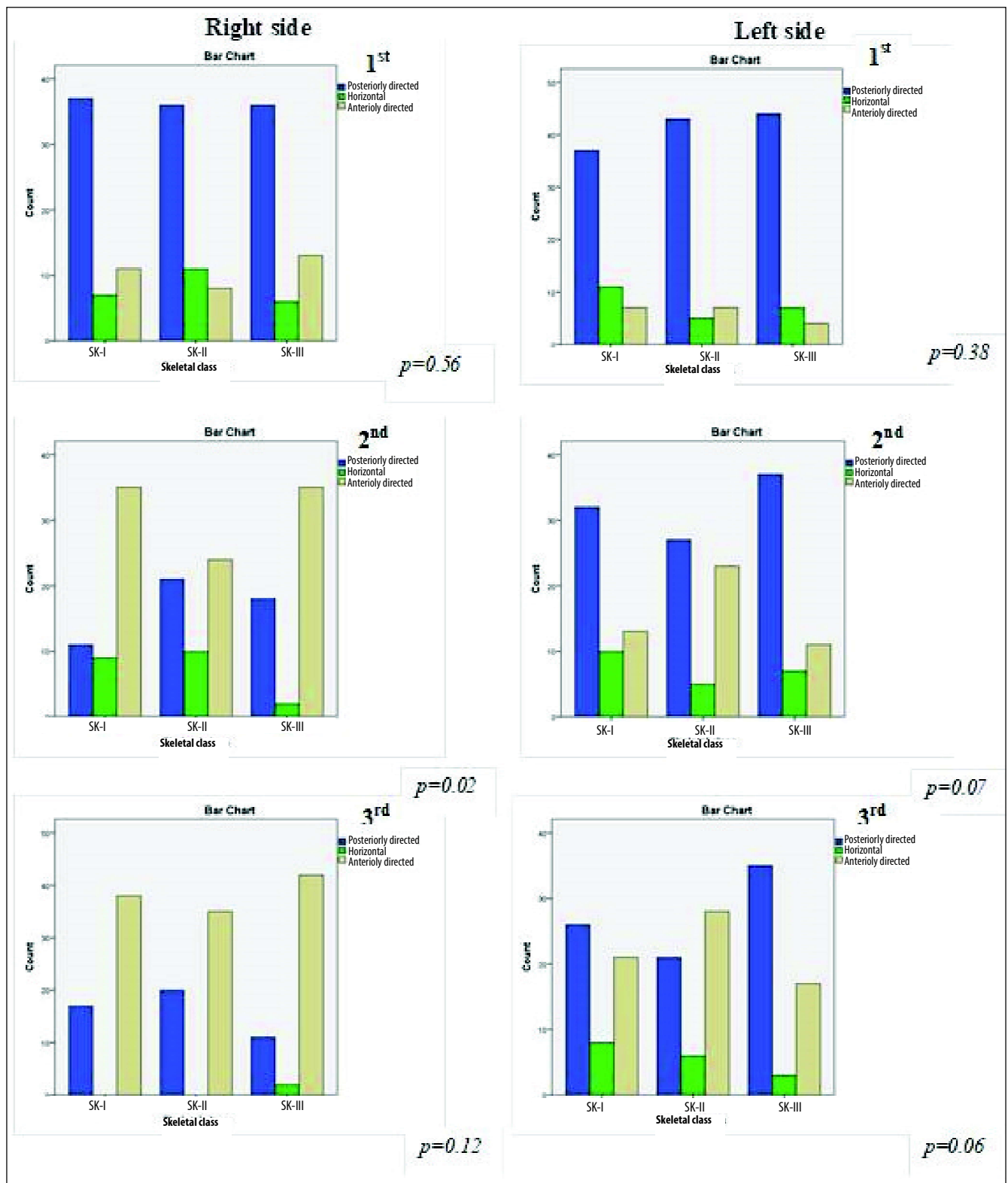


Figure-4: Comparison of orientation of primary palatal rugae among malocclusion groups. n=165, Chi-square test: *p≤0.05.

Discussion

During the diagnosis and treatment planning, dental cast provides the three-dimensional record of malocclusion. It has been established that the sequential formation of these structures occur via classic activator-inhibitor system, which is mediated through the interactions between fibroblast growth factors and hedgehog signalling pathways.¹⁸ The same fundamental molecular signalling pathways regulate the development of craniofacial region in many aspects.

Various methods have been used for the evaluation of palatal rugae. Van der Linden¹⁹ observed the detailed 3-dimensional (3D) information using the Optocom software. The digitisation using the Reflex Metrograph has been used by Almeida et al²⁰ and Bailey et al.²¹ M'Lissa and Sadowsky²² used photocopies of maxillary dental casts to measure the dental and palatal landmarks. However, each of these methods requires a specific device or software. Kapali et al² and Moran et al²³ used slide vernier caliper for the measurement purpose. In the current study, dental casts were evaluated using digital vernier caliper as it is economical, simple and has good reproducibility. With contemporary technological progression, the 3D information could be attained using a 3D scanner.

Primary rugae in the current study numbered three to four. There was no significant difference among the sagittal skeletal malocclusion groups. These findings were consistent with the results reported by Oral et al.¹⁷ Kapoor and Ragini¹⁶ conducted a study to identify characteristics of palatal rugae among Angle's classes of malocclusion according to which there are greater number of rugae in the Class II division 2 group. Although the results were not conclusive due to small sample size, literature supports the results because greater maxillary intercanine and interpremolar arch width has been reported in Class II division 2 compared to Class III samples. The mean lengths of palatal rugae may perhaps be affected by the transverse dimension of maxilla. They were found to be lower in skeletal Class I compared to Class II and III. The results could be due to less severe skeletal Class II and III cases. No previous study compared the length of rugae among the skeletal classes.

The position of the tongue varies with malocclusion pattern; therefore, the rugae pattern may likely vary in different malocclusions. In the current study, curved type of rugae was found to be most predominant pattern in different malocclusion groups. However, Kapali et al² and

Oral et al¹⁷ reported wavy type of rugae as the most prevalent pattern. The conflicting results could be due to ethnic variation.

The mechanism of the development of rugae has been poorly understood.²⁴ They are asymmetric structures that are unique to an individual. The evaluation of the orientation of rugae showed posteriorly directed rugae to be more prevalent in all skeletal patterns at first primary rugae. Oral et al¹⁷ reported horizontal arrangement of rugae in Turkish population. Moreover, strong genomic predilection has been reported in the number, shape and orientation of palatal rugae.

In view of the variable results found in the present study, further studies are recommended in order to confirm the association between the morphological characteristics of palatal rugae and sagittal skeletal malocclusion. This may not only help in early diagnosis and preventive and interceptive treatment, but may also lead a path in forensic dentistry to allow the identification of potential suspects through palatal rugae and their skeletal malocclusions. It may also assist in the identification of the suspects by facilitating the facial reconstruction through skeletal patterns.

Conclusions

No specific pattern was associated with any skeletal pattern in the study. Further research is required to evaluate 3D characteristics of rugae to assess the association between palatal rugae and sagittal skeletal patterns.

Disclaimer: None.

Conflict of Interest: None.

Source of Funding: None.

References

1. Hauser G, Daponte A, Roberts MJ. Palatal rugae. *J Anat* 1989; 165: 237-49.
2. Kapali S, Townsend G, Richards L, Parish T. Palatal rugae patterns in Australian Aborigines and Caucasians. *Aust Dent J* 1997; 42: 129-33.
3. Lysell L. Plicae palatinae transversae and papilla incisive in man; a morphologic and genetic study. *Acta Odontol Scand* 1995; 13: 5.
4. Nunzi MG, Pisarek A, Mugnaini E. Merkel cells, corpuscular nerve endings and free nerve endings in the mouse palatine mucosa express three subtypes of vesicular glutamate transporters. *J Neurocytol* 2004; 33: 359-76.
5. Patil MS, Patil SB, Acharya AB. Palatine rugae and their significance in clinical dentistry: a review of the literature. *J Am Dent Assoc* 2008; 139: 1471-8.

6. English WR, Robison SF, Summitt JB, Oesterle LJ, Brannon RB, Morlang WM. Individuality of human palatal rugae. *J Forensic Sci* 1988; 33: 718-26.
 7. Saraf A, Bedia S, Indurkar A, Degwekar S, Bhowate R. Rugae patterns as an adjunct to sex differentiation in forensic identification. *J Forensic Odontostomatol* 2011; 29: 14-9.
 8. Lee JM, Miyazawa S, Shin JO, Kwon HJ, Kang DW, Choi BJ, et al. Shh signaling is essential for rugae morphogenesis in mice. *Histochem Cell Biol* 2011; 136: 663-75.
 9. Lin C, Fisher AV, Yin Y, Maruyama T, Veith GM, Dhandha M, et al. The inductive role of Wnt- β -Catenin signaling in the formation of oral apparatus. *Dev Biol* 2011; 356: 40-50.
 10. Cobourne MT, Sharpe PT. Making up the numbers: the molecular control of mammalian dental formula. *Semin Cell Dev Biol* 2010; 21: 314-24.
 11. Murdoch AM, Patir A, Seymen F, Vieira AR. Studies of palatine rugae and interferon regulatory factor 6 variations in a group of families with sporadic hypodontia. *J Oral Sci* 2009; 51: 521-6.
 12. Economou AD, Ohazama A, Porntaveetus T, Sharpe PT, Kondo S, Basson MA, et al. Periodic stripe formation by a Turing mechanism operating at growth zones in the mammalian palate. *Nat Genet* 2012; 44: 348-51.
 13. Hoggan BR, Sadowsky C. The use of palatal rugae for the assessment of anteroposterior tooth movements. *Am J Orthod Dentofacial Orthop* 2001; 119: 482-8.
 14. Naini FB, Moss JP. Three-dimensional assessment of the relative contribution of genetics and environment to various facial parameters with the twin method. *Am J Orthod Dentofacial Orthop* 2004; 126: 655-65.
 15. Nayak P, Acharya AB, Padmini AT, Kaveri H. Differences in the palatal rugae shape in two populations of India. *Arch Oral Boil* 2007; 52: 977-82.
 16. Kapoor P, Ragini, Kaur H. Rugoscopy: A diagnostic appurtenance for malocclusion or just a forensic aid?- A pilot study. *J Forensic Res* 2015; 6: 2.
 17. Oral E, Buyuk SK, Simsek H. Evaluation of palatal rugae pattern in different sagittal skeletal relationship adolescent subjects. *Medicine* 2017; 96: e6440.
 18. Jang I, Tanaka M, Koga Y, Iijima S, Yozgatian JH, Cha BK, et al. A novel method for the assessment of three-dimensional tooth movement during orthodontic treatment. *Angle Orthod* 2009; 79: 447-53.
 19. Van der Linden FP. Changes in the position of posterior teeth in relation to ruga points. *Am J Orthod* 1978; 74: 142-61.
 20. Almeida MA, Phillips C, Kula K, Tulloch C. Stability of the palatal rugae as landmarks for analysis of dental casts. *Angle Orthod* 1995; 65: 43-8.
 21. Bailey LT, Esmailnejad A, Almeida MA. Stability of the palatal rugae as landmarks for analysis of dental casts in extraction and nonextraction cases. *Angle Orthod* 1996; 66: 73-8.
 22. M'Lissa MR, Sadowsky C. Efficacy of intraarch mechanics using differential moments for achieving anchorage control in extraction cases. *Am J Orthod Dentofacial Orthop* 1997; 112: 441-8.
 23. Moran A, Tippet H, Manoharan A, Cobourned MT. Alteration of palatine ruga pattern in subjects with oligodontia: A pilot study. *Am J Orthod Dentofacial Orthop* 2016; 150: 295-302.
 24. Blum M, Feistel K, Thumberger T, Schweickert A. The evolution and conservation of left-right patterning mechanisms. *Development* 2014; 141: 1603-13.
-