

Washington University School of Medicine Digital Commons@Becker

Open Access Publications

2019

A fatal case of disseminated microsporidiosis due to *Anncaliia algerae* in a renal and pancreas allograft recipient

Neil W. Anderson

Washington University School of Medicine in St. Louis

Atis Muehlenbachs

Center for Disease Control and Prevention

Sana Arif

Duke University

Jackrapong Bruminhent

Mahidol University

Paul J. Deziel

Mayo Clinic

See next page for additional authors

Follow this and additional works at: https://digitalcommons.wustl.edu/open_access_pubs

Recommended Citation

Anderson, Neil W.; Muehlenbachs, Atis; Arif, Sana; Bruminhent, Jackrapong; Deziel, Paul J.; Razonable, Raymund R.; Wilhelm, Mark P.; Metcalfe, Maureen G.; Qyarnstrom, Yvonne; and Pritt, Bobbi S., "A fatal case of disseminated microsporidiosis due to *Anncaliia algerae* in a renal and pancreas allograft recipient." *Open Forum Infectious Diseases*,. . (2019).
https://digitalcommons.wustl.edu/open_access_pubs/8227

This Open Access Publication is brought to you for free and open access by Digital Commons@Becker. It has been accepted for inclusion in Open Access Publications by an authorized administrator of Digital Commons@Becker. For more information, please contact engeszer@wustl.edu.

Authors

Neil W. Anderson, Atis Muehlenbachs, Sana Arif, Jackrapong Bruminhent, Paul J. Deziel, Raymund R. Razonable, Mark P. Wilhelm, Maureen G. Metcalfe, Yvonne Qvarnstrom, and Bobbi S. Pritt

A Fatal Case of Disseminated Microsporidiosis Due to *Anncaliia algerae* in a Renal and Pancreas Allograft Recipient

Neil W. Anderson,^{1,a} Atis Muehlenbachs,^{2,b} Sana Arif,³ Jackrapong Bruminhent,⁴ Paul J. Deziel,⁵ Raymund R. Razonable,^{5,6} Mark P. Wilhelm,^{5,6} Maureen G. Metcalfe,^{2,c} Yvonne Qvarnstrom,⁷ and Bobbi S. Pritt^{1,6}

¹Division of Clinical Microbiology, Department of Laboratory Medicine and Pathology, Mayo Clinic, Rochester, Minnesota; ²Division of High-Consequence Pathogens and Pathology, National Center for Emerging and Zoonotic Infectious Diseases, Centers for Disease Control and Prevention, Atlanta, Georgia; ³Division of Infectious Diseases, Department of Medicine, Duke University School of Medicine, Durham, North Carolina; ⁴Division of Infectious Diseases, Department of Medicine, Faculty of Medicine Ramathibodi Hospital, Mahidol University, Bangkok, Thailand; ⁵William J. von Liebig Center for Transplantation and Clinical Regeneration, Mayo Clinic, Rochester, Minnesota; ⁶Division of Infectious Diseases, Department of Medicine, Mayo Clinic, Rochester, Minnesota; ⁷Division of Parasitic Diseases and Malaria, Center for Global Health, Centers for Disease Control and Prevention, Atlanta, Georgia

Key words: *Brachiola*; immunocompromised; microsporidiosis; microsporidia; *Nosema*; opportunistic.

CASE REPORT

A 60-year-old male pancreas and renal allograft recipient presented for evaluation of a painless, nonpruritic papular rash on his lower extremities. Seventeen months prior, he received a living unrelated donor kidney transplant for end-stage renal disease secondary to ANCA-associated antglomerular basement membrane disease, followed 7 months later by a pancreas allograft transplant for type 1 diabetes mellitus. He received alemtuzumab and thymoglobulin for induction therapy after renal and pancreas transplants, respectively, followed by prednisone, mycophenolate mofetil and tacrolimus for maintenance immunosuppression. His posttransplant course was complicated by acute pancreas allograft rejection requiring increased dose of prednisone, severe hypogammaglobulinemia requiring monthly intravenous immunoglobulin, and severe lymphopenia (CD4+ T helper cells of 0–5 cells/ μ L). He experienced multiple opportunistic infectious complications, initially with delayed

onset primary cytomegalovirus pneumonitis and retinitis (with virologic recurrences), followed by influenza A pneumonia with prolonged viral shedding, and recurrent dermatomal zoster. Subsequently, he developed overlapping infections due to *Aspergillus* sp. (invasive rhinosinusitis), *Lichtheimia* (*Absidia*) sp. (pneumonia), and *Mycobacterium malmoeense* (bloodstream infection and pneumonia). At the time of his evaluation, he was receiving liposomal amphotericin B and posaconazole for invasive aspergillus sinusitis and *Lichtheimia* pneumonia, and clarithromycin, rifabutin, and ethambutol for *Mycobacterium malmoeense* infection. In addition, he was receiving prophylaxis with trimethoprim-sulfamethoxazole and valganciclovir.

A punch biopsy of the skin lesion in the lower extremity showed extensive vascular thrombosis and dermal necrosis. Clusters of small, 2 to 4 μ m long, oval organisms (Figure 1) were observed in the dermis with a scant associated lymphohistiocytic inflammatory response. Organisms were located within cells and lumens of eccrine ducts and within smooth muscle and lumens of dermal arterioles. No budding was identified. A small number of organisms were positive with Grocott-Gomori's methenamine silver (GMS) stain. Based on this appearance, a presumptive diagnosis of histoplasmosis was made, and he was continued on liposomal amphotericin B and posaconazole. Subsequent fungal cultures from skin biopsies were negative, and serologic and urine antigen testing for *Histoplasma capsulatum* were negative. *H. capsulatum* PCR (polymerase chain reaction) on lesional tissue also was negative. His rash remained unchanged on antifungal therapy and he subsequently developed ulcerations over the tip of his tongue with a yellowish eschar (Figure 1). Biopsy of the lesions showed similar organisms to those previously described.

During this time, he experienced profound pancytopenia. Bone marrow biopsy showed hypocellular bone marrow with no evidence of infection. Over concerns for aplastic anemia, he was given methylprednisolone intravenously followed by a course of prednisone therapy and subsequently cyclosporine, during which his rash worsened and he developed necrotic lesions on his fingertips (Figure 1). Biopsy of a finger lesion once again highlighted small organisms similar to those previously observed with focal GMS positivity. Organisms also were noted to be strongly Gram positive (Twort's Gram stain), focally positive with the Ziehl-Neelsen stain, and focally birefringent with polarized light (Figure 1). Distinctive polar dot-like positivity was observed using Periodic acid-Schiff (PAS) stain without amylase. At this point, expert review by pathologists specializing in the pathology of infectious diseases at Mayo Clinic and the Centers for Disease Control and Prevention's (CDC) Infectious Diseases Pathology Branch and Parasitic

Received 19 April 2019; editorial decision 7 June 2019; accepted 29 June 2019.

^aPresent affiliation: Division of Laboratory and Genomic Medicine, Department of Pathology and Immunology, Washington University School of Medicine in St. Louis, Missouri

^bPresent affiliation: Clinical Laboratory Improvement Amendments Compliance Program, Office of Deputy Director for Infectious Diseases, Centers for Disease Control and Prevention, Atlanta, Georgia

^cPresent affiliation: Deloitte Consulting LLP

Correspondence: B. S. Pritt, MD, MSc, DTMH, Department of Clinical Microbiology, Mayo Clinic, 200 1st St SW, Rochester MN 55906 (pritt.bobbi@mayo.edu).

Open Forum Infectious Diseases®

Published by Oxford University Press on behalf of Infectious Diseases Society of America 2019. This work is written by (a) US Government employee(s) and is in the public domain in the US. DOI: 10.1093/ofid/ofz285

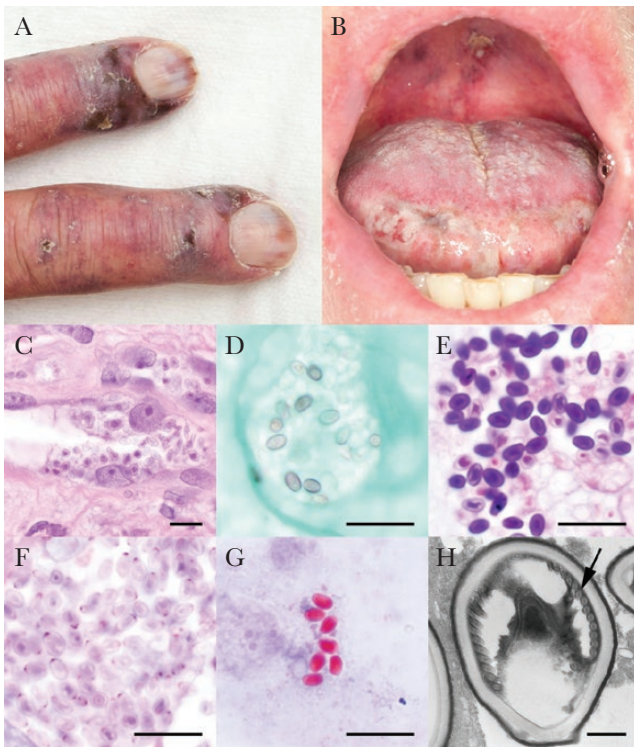


Figure 1. The patient developed several clinical manifestations of disseminated microsporidiosis due to *Anncaliia algeriae*, including (A) ulcerative fingers and (B) oral lesions, as well as ulcerative intranasal lesions and a diffuse papular rash of the lower extremities (not shown). By light microscopic examination, spores were visible using (C) routine hematoxylin and eosin staining, (D) focally positive by Gomori methenamine silver stain, and (E) strongly Gram-positive by Gram stain. (F) The Periodic acid–Schiff stain showed polar dot-like positivity, which is characteristic of microsporidial spores. Spores also were stained bright red using (G) the Ryan blue modified trichrome stain for microsporidia. (H) Electron microscopy showed features of a *Nosema*-like microsporidia, including large size, a thick cell wall, and a single row of polar filaments (arrow). Scale bars represent 20 μm , except in (H) in which the scale bar is 500 nm.

Diseases Branch (Atlanta, GA) concluded that microsporidiosis was the likely diagnosis. Ryan blue modified trichrome stain on sputum and urine showed positively-staining structures (4 μm long) consistent with microsporidial spores. Electron microscopy and molecular studies at the CDC confirmed the diagnosis of microsporidiosis. Based on ultrastructure features (Figure 1), including organism size, cell wall thickness, and number of polar tubule coils, the organism was identified as a *Nosema*-like organism. Molecular amplification and sequencing identified the organisms specifically as *Anncaliia* (formerly *Brachiola*, *Nosema*) *algeriae*. A diagnosis of systemic disease was made based on the presence of microsporidia spores in the lower extremity, finger and tongue biopsies, as well as in urine and sputum samples.

The patient was started on albendazole, 400 mg twice daily, for disseminated microsporidiosis; unfortunately, his skin rash continued to progress, and his lesions on his fingers and oral cavity became necrotic with eschar formation. In addition to

albendazole, itraconazole and clindamycin were added for potential enhanced activity [1]. Approval was received to use fumagillin from the US Food and Drug Administration under an investigational use protocol, but the drug unfortunately was not available from the manufacturer. At this point, the patient's immunosuppressive medications were discontinued to enable his immune system to better mount a response to the infection. He continued to be debilitated. Because of his declining condition and nonresponse to antimicrobial therapy despite the discontinuation of all immunosuppressive regimens, he decided for comfort care. He expired 2 days after transition to comfort measures, 5 months after his clinical presentation.

The microsporidia are a large group of parasitic fungi encompassing several genera. They are obligate intracellular eukaryotic organisms that survive extracellularly by forming a spore with a thick cell wall. This spore contains a polar tubule, a coiled extrusion apparatus that the organism uses to inject its contents into a host cell. Once inside a host cell, intracellular replication leads to production of more spores that are released by cell rupture.

Microsporidia spores are readily identified in typical tissue, stool, or respiratory specimens. They are small (0.8–4 μm in greatest dimension) and are highlighted in direct specimen preparations using modifications to the trichrome stain that increase the chromotrope 2R component (eg, Ryan blue modified trichrome stain), allowing the stain to penetrate the thick cell wall [2]. The organisms also can be visualized on calcofluor white stain or using specific direct fluorescent antibody preparations. In formalin-fixed, paraffin-embedded tissues sections, spores are partially acid fast, stain variably with GMS, exhibit birefringence with polarized light, and have a polar dot-like positivity using the PAS stain [3, 4] that corresponds to the polar tubule. Electron microscopy and, recently, nucleic acid amplification tests are used to identify the infecting genus and species [5].

Of the many different microsporidia capable of causing human disease, the 2 most common, *Encephalitozoon intestinalis* and *Enterocytozoon bieneusi*, are associated with diarrhea in immunosuppressed patients. These organisms also can cause disease in other body sites, including the lungs, kidneys, and central nervous system. Although their spores are small (<2 μm in greatest dimension), the spores of other genera such as *Anncaliia* are larger ($\leq 4 \mu\text{m}$) and may be confused with small yeasts. As such, initial misdiagnosis of microsporidia infection as disseminated fungal infection has been reported in the literature [6]. This was observed in our patient as well, because he was initially misdiagnosed as having disseminated histoplasmosis due to the large size of the observed organisms and focal GMS positivity. However, 2 major aspects of this case were not supportive of this diagnosis: he was already receiving liposomal amphotericin B and posaconazole (both active against *H. capsulatum*) and he had negative fungal

culture, *H. capsulatum* urine antigen, serology, and PCR. These prompted additional expert review at Mayo Clinic and the CDC, which allowed for definitive identification of microsporidiosis. Electron microscopy and molecular amplification identified the organisms as *A. algerae*.

A. algerae is an insect pathogen, infecting primarily mosquitos [7]. This organism only rarely has been reported to cause disease in humans. As of 2018, a review of published literature revealed a total of 7 cases isolated to Australia and North America. These include cases in patients following stem cell and solid organ transplantation. Disease typically manifests as skeletal muscle myositis, with over half of patients experiencing central nervous system or cardiac involvement [6]. Involvement of the vocal chords and bulbar muscles also has been described, leading to dysphagia and aspiration pneumonia [6, 8, 9]. The mechanism of transmission, including potential role of mosquitoes, is unknown.

An important feature common to our case and in previously reported cases is the severity of disease. This is likely attributed to the highly compromised immune status of the patients. Moreover, although albendazole typically is effective for other causes of microsporidiosis, a proportion of infections caused by *A. algerae* appear not to respond as efficiently to this drug [10, 11]. In the absence of controlled studies examining the efficacy of albendazole for this species in comparison to other microsporidia, it is difficult to attribute these instances of treatment failure to albendazole resistance versus other factors, such as differences in host immunity, disease burden, and organism virulence. Other less widely available drugs might enhance effect, such as fumagillin and nikkomycin Z [11]. Efforts to acquire fumagillin from the manufacturer were unsuccessful. Discontinuation of the immunosuppressive drugs should be strongly considered in cases when antimicrobial therapy is very limited, particularly in recipients of kidney and pancreas allografts, in whom alternative treatments (dialysis and insulin, respectively) are available. This approach was not possible in this case as the diagnosis of microsporidiosis occurred later in the disease course.

Clinical familiarity with microsporidia is largely due to HIV-associated cases prior to highly active antiretroviral therapy. These cases often were caused by a narrow spectrum of species and typically resulted in diarrhea with occasional extra-intestinal manifestations. In contrast, only very few cases are reported in non-HIV immunocompromised hosts, such as transplant recipients. Our transplant patient was significantly immunocompromised, even when compared to the typical solid organ transplant recipient—he was profoundly T-cell depleted, hypogammaglobulinemic,

and pancytopenic. This severely immunosuppressed state is phenotypically manifested by sequential and concurrent infections with classic and unusual opportunistic pathogens, including, in this case, lesser known species of microsporidia [12].

In summary, we present a fatal case of disseminated microsporidiosis due to *A. algerae* in a highly immunocompromised kidney and pancreas allograft recipient. Microsporidiosis was initially misdiagnosed as *H. capsulatum* due to its overlapping morphologic features. Clinicians, pathologists, and microbiologists should consider microsporidiosis in their differential diagnosis, particularly in profoundly immunocompromised hosts, and seek expert consultation when appropriate.

Acknowledgments

Disclaimer. The findings and conclusions in this report are those of the authors and do not necessarily represent the views of the Centers for Disease Control and Prevention. Mr. Deziel, and Drs. Arif, Bruminhent, Metcalfe, Muehlenbachs, Pritt, Qvarnstrom, and Wilhelm have no disclosures. Dr. Neil Anderson has received Honoria from Alere and Diasorin Molecular and serves on the scientific advisory board for Diasorin Molecular. Dr. Raymond Razonable has received research grants from Roche and Chimerix and serves on the Data and Safety Monitoring Board for Novartis.

Financial support. None reported.

Potential conflicts of interest. All authors: No reported conflicts of interest. All authors have submitted the ICMJE Form for Disclosure of Potential Conflicts of Interest. Conflicts that the editors consider relevant to the content of the manuscript have been disclosed.

References

1. Kester KE, Turiansky GW, McEvoy PL. Nodular cutaneous microsporidiosis in a patient with AIDS and successful treatment with long-term oral clindamycin therapy. *Ann Intern Med* **1998**; 128:911–4.
2. Garcia LS. Laboratory identification of the microsporidia. *J Clin Microbiol* **2002**; 40:1892–901.
3. Weber R, Deplazes P, Mathis A. Microsporidia. In: Jorgensen J, Pfaller M, Carroll K, Funke G, Landry M, Richter S, Warnock D, eds. *Manual of Clinical Microbiology*. 11th ed. Washington, DC: ASM Press; **2015**:2209–19.
4. Joseph J, Vemuganti GK, Garg P, Sharma S. Histopathological evaluation of ocular microsporidiosis by different stains. *BMC Clin Pathol* **2006**; 6:6.
5. Wang Z, Orlandi PA, Stenger DA. Simultaneous detection of four human pathogenic microsporidian species from clinical samples by oligonucleotide microarray. *J Clin Microbiol* **2005**; 43:4121–8.
6. Suttrave G, Maundrell A, Keighley C, et al. *Anncaliia algerae* Microsporidial Myositis, New South Wales, Australia. *Emerg Infect Dis* **2018**; 24:1528–31.
7. Mathis A, Weber R, Deplazes P. Zoonotic potential of the microsporidia. *Clin Microbiol Rev* **2005**; 18:423–45.
8. Cali A, Neafie R, Weiss LM, et al. Human vocal cord infection with the *Microsporidium Anncaliia algerae*. *J Eukaryot Microbiol* **2010**; 57:562–7.
9. Visvesvara GS, Moura H, Leitch GJ, Leitch GJ, Schwartz DA, Xiao LX. Public health importance of *Brachiola algerae* (Microsporidia)—an emerging pathogen of humans. *Folia Parasitol* **2005**; 52:83–94.
10. Coyle CM, Weiss LM, Rhodes LV 3rd, et al. Fatal myositis due to the microsporidian *Brachiola algerae*, a mosquito pathogen. *N Engl J Med* **2004**; 351:42–7.
11. Boileau M, Ferreira J, Ahmad I, Lavallée C, Qvarnstrom Y, Dufresne SF. Successful treatment of disseminated *Anncaliia algerae* microsporidial infection with combination fumagillin and albendazole. *Open Forum Infect Dis* **2016**; 3:ofw158.
12. Meissner EG, Bennett JE, Qvarnstrom Y, et al. Disseminated microsporidiosis in an immunosuppressed patient. *Emerg Infect Dis* **2012**; 18:1155–8.