

**ORIGINAL ARTICLE**

# A NOVEL DISEASE-CAUSING *NF1* VARIANT IN A CROATIAN FAMILY WITH NEUROFIBROMATOSIS TYPE 1

Kristina Gotovac Jercic<sup>1</sup>, Tamara Zigman<sup>2</sup>, Sanja Delin<sup>3</sup>, Goran Krakar<sup>4</sup>, Vlasta Duranovic<sup>5</sup>, Fran Borovecki<sup>1,6</sup>

**Abstract:** Neurofibromatosis type 1 (NF1) is the most common autosomal dominant neurocutaneous syndrome with the estimated prevalence ranging from 1 in 3000 to 1 in 4000 individuals and wide phenotypical variability. NF1 is caused by autosomal dominant heterozygous mutations in the neurofibromin gene which is located on the chromosome 17 (17q11.2). Phenotypically, NF1 patients have a very heterogeneous clinical phenotype. In this study, a novel frameshift NF1 variant was identified in a Croatian family with NF1 (mother and two daughters). The novel variant c.4482\_4483delTA leads to sequence change that creates a premature translational stop signal (p.His1494Glnfs\*7) in the NF1 gene. Our study showed that even when the same germline NF1 variant has been identified, there is still huge phenotypic variability in patients even within the same family, and it makes prognosis of the disease more complex. The development of next-generation sequencing technologies which allow rapid and accurate identification of disease-causing mutations becomes crucial for molecular characterization of NF1 patients as well as for patient follow-up, in the context of genetic counseling and clinical management of patients.

<sup>1</sup>Department of Neurology, University Hospital Center Zagreb, Zagreb, Croatia

<sup>2</sup>Department of Pediatrics, University Hospital Center Zagreb, Zagreb, Croatia

<sup>3</sup>Department of Pediatrics, General Hospital Zadar, Zadar, Croatia

<sup>4</sup>Sabol Pediatric Clinic, Zagreb, Croatia

<sup>5</sup>Department of Neuropediatrics, Children's Hospital Zagreb, Zagreb, Croatia

<sup>6</sup>Department for Functional Genomics, Center for Translational and Clinical Research, University Hospital Center Zagreb, University of Zagreb School of Medicine, Zagreb, Croatia

**Corresponding author:**

Kristina Gotovac Jercic  
 Department of Neurology, University Hospital Center Zagreb,  
 Kispaticeva 12, HR-10000 Zagreb, Croatia  
 Tel: +385 1 45 90 067  
 e-mail: kristina.gotovac@kbc-zagreb.hr

**Submitted:** June, 2019

**Accepted:** August, 2019

**Key words:** NF1 gene, neurofibromatosis type 1, next generation sequencing, genetic analysis

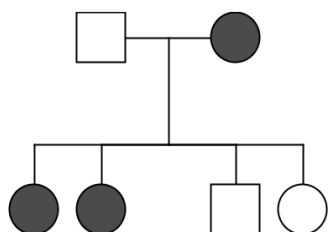
**INTRODUCTION**

Neurofibromatosis type 1 (NF1) is the most common autosomal dominant neurocutaneous syndrome with the estimated prevalence ranging from 1 in 3000 to 1 in 4000 individuals and wide phenotypical variability.<sup>1, 2</sup> Clinical diagnosis of NF1 is suspected with the appearance of the following major features: occurrence of café-au-lait macules, Lisch nodules of the iris, cutaneous and plexiform neurofibromas, axillary freckling and skeletal abnormalities.<sup>3</sup> Phenotypically, NF1 patients have a very heterogeneous clinical phenotype. Besides skin lesions as the most noticeable manifestation, NF1 may affect many organs and cause psychiatric and psychological disorders.<sup>4, 5</sup> NF1 is caused by autosomal dominant heterozygous mutations in the neurofibromin gene which is located on the chromosome 17 (17q11.2). The NF1 gene is a tumor suppressor with the function of stimulating the GTPase activity of the RAS protein serving as a negative regulator of the cellular Ras/MAPK (mitogen-activated protein kinases) signaling pathway.<sup>6, 7</sup> More than 3000 different pathogenic allelic variants have been identified in the NF1 gene so far (The Human Gene Mutation Database), with half of the variants arising *de novo*, which is an expected observation since NF1 has one of the highest mutation rates reported in humans.<sup>8</sup> Molecular diagnosis in NF1 should be of great value for confirming the diagnosis. However, the large size of the gene (257 Kb), its high mutation rate, the existence of 15 pseudogenes and no mutation hot-spots present a big challenge, and, therefore, molecular testing of the NF1 gene is usually time-consuming and expensive.<sup>9-11</sup> The development of next-generation sequencing (NGS) technologies which allows for rapid identification of disease-causing mutations and high-risk alleles has recently been introduced into NF1 diagnosis.<sup>12-15</sup>

## MATERIAL AND METHODS

### *Study subjects, disease criteria, and clinical evaluation*

A family (mother and two daughters) with unusual clinical presentations of NF1 were recruited at the Clinical Hospital Center Zagreb for diagnostic analysis of the NF1 gene (Figure 1). The NF1 diagnosis was established based on the diagnostic criteria of the National Institutes of Health consensus statement.<sup>16</sup> Peripheral blood specimens were collected from the patients. Clinical data including available medical histories, imaging, and histopathological examinations were obtained. The study was carried out in accordance with the principles of the Declaration of Helsinki. Written informed consent was obtained from all participating individuals.



**Figure 1.** Pedigree of the family.

Legend: Squares indicate males, circles indicate females, respectively; open symbols indicate unaffected individuals, filled symbols indicate affected individuals.

### *Targeted gene enrichment and high-throughput sequencing*

The gene panel was designed using the Design Studio Tool (Illumina, San Diego, CA, USA). The coding regions of 142 genes were selected for targeted gene enrichment. The coordinates of genomic regions were based on NCBI build 37 (UCSC hg19). Total DNA was extracted from peripheral blood samples using the Zymo Universal DNA kit (ZR; Zymo Research) according to the manufacturer's instructions. The DNA concentration of each sample was determined using a Qubit 3 Fluorimeter and the dsDNA HS kit (Invitrogen, Thermo Scientific, Wilmington, DE, USA). Custom targeted gene enrichment and DNA library preparation were performed using the Nextera Rapid Capture Custom Enrichment kit (Illumina) according to the manufacturer's instructions. The targeted regions were sequenced using the Illumina MiSeq platform, generating approximately 14 million of 150-bp paired-end reads for each sample ( $Q30 \geq 90\%$ ).

### *Variant calling, filtering, and classification*

The FASTQ files generated by the MiSeq were streamed to Illumina BaseSpace where the data was assembled

with the BWA Genome Alignment Software and the variants called according to the GATK Variant Caller. This produced a Variant Call Format (.VCF) file, which was further imported into Illumina Variant Interpreter. Variants were considered disease-causing under strict criteria in accordance with the published Sherlock guidelines for the interpretation of sequence variants. After sequencing data submission, the pipeline executed the following steps: the quality checks and filter of the reads; the alignment on the reference genome hg19; variant preprocessing; coverage statistics and metrics; variant calling; variant annotation. Genetic variants predicted to alter the protein, such as non-synonymous variants, nonsense variants, canonical splicing site variants (affecting the donor or acceptor splice sites), in-frame and frameshift insertion/deletions were selected. To assess the potential functional impacts of variants, two bioinformatics algorithms were used: Sorting Intolerant From Tolerant (SIFT) and Mutation Taster. Using the online multiple protein sequence alignment tool COBALT we analyzed the conserved domain among *Homo sapiens* (human), *Rattus norvegicus* (Norway rat) and *Mus musculus* (mouse) to see whether the NF1 mutation was located in the conserved region of the human NF1 protein.

### *Variant databases and prediction programs*

The list of variant databases and prediction programs used in the study is presented in Table 1.

**Table 1.** List of variant databases and prediction programs

Variant databases:
1000 Genomes Project <a href="http://browser.1000genomes.org/index.html">http://browser.1000genomes.org/index.html</a>
NCBI dbSNP <a href="http://www.ncbi.nlm.nih.gov/SNP/">http://www.ncbi.nlm.nih.gov/SNP/</a>
Exome Variant Server <a href="http://evs.gs.washington.edu/EVS/">http://evs.gs.washington.edu/EVS/</a>
Genome Aggregation Database (gnomAD) <a href="http://gnomad.broadinstitute.org">http://gnomad.broadinstitute.org</a>
ClinVar <a href="http://www.ncbi.nlm.nih.gov/clinvar/">http://www.ncbi.nlm.nih.gov/clinvar/</a>
Human Genome Mutation Database (HGMD) <a href="http://www.biobase-international.com">http://www.biobase-international.com</a>
Prediction programs:
SIFT <a href="https://sift.bii.a-star.edu.sg/www/SIFT_indels2.html">https://sift.bii.a-star.edu.sg/www/SIFT_indels2.html</a>
Mutation Taster <a href="http://www.mutationtaster.org/">http://www.mutationtaster.org/</a>
COBALT <a href="https://www.ncbi.nlm.nih.gov/tools/cobalt/">https://www.ncbi.nlm.nih.gov/tools/cobalt/</a>

## RESULTS

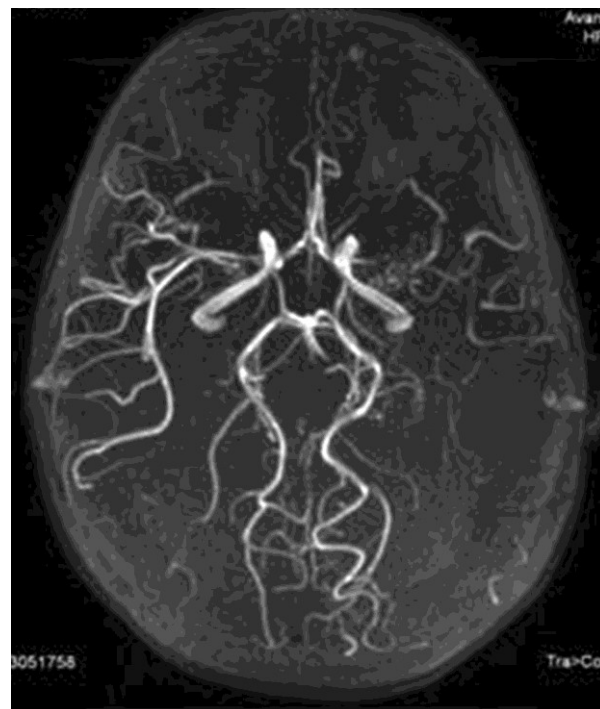### *Clinical Features*

Our first patient is a woman with positive diagnostic criteria for NF1. Her two daughters that we also describe later in the text have positive diagnostic criteria for NF1.

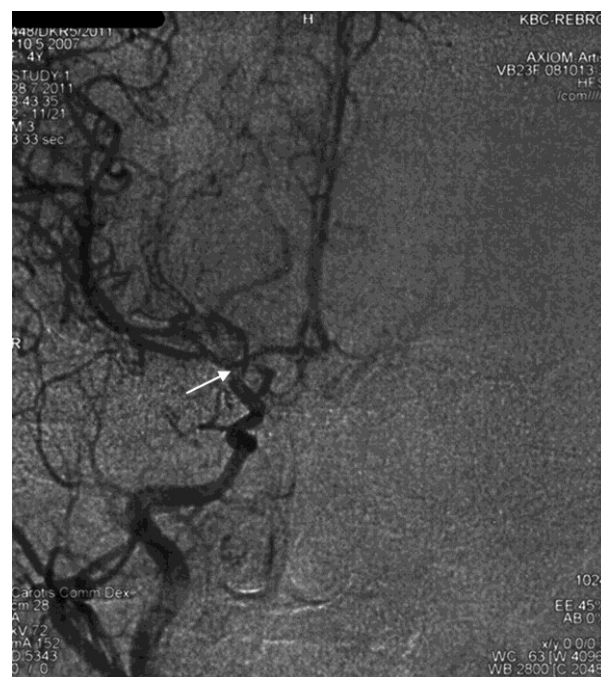Family history is positive for NF1 (her mother and grandfather had numerous café-au-lait spots and cutaneous neurofibromas). At the age of 45, she was admitted to hospital because of a large tumorous mass on the right side of the head and neck. Besides a large, hard and elastic subcutaneous tumor mass on the right side of the head and neck, physical examination revealed numerous café au lait spots, cutaneous and subcutaneous neurofibromas and axillary freckling. Large (around 5 cm in diameter), well-circumscribed spherical tumorous mass, located between the internal carotid artery and the internal jugular vein, reaching the jugular foramen in the cranial direction was found intraoperatively. It was hardly detachable from the vagal nerve. Pathohistological examination revealed an encapsulated tumorous mass, 5.5x4x3.5 cm in diameter, histologically consisting of multiplied stromal cells, elongated and spindle-shaped, moderately polymorphic, with a few areas of high cellularity. Some cells that resembled ganglionic cells were also present. The tumor stroma was abundant and collagenous. Some areas showed the presence of cartilage tissue and necrosis. Immunohistochemical staining showed focal S-100 positivity. Diagnosis of malignant peripheral sheath tumor was established. Radiation therapy was administered postoperatively. Positron emission tomography scan performed 4 months postoperatively showed no signs of tumor dissemination. A brain MRI performed 1 year postoperatively revealed focal areas of signal intensity (FASI) in the anteromedial part of right thalamic nuclei, splenium of corpus callosum and bilaterally in both dentate nuclei of the cerebellum - all lesions typically found in NF1 patients. Currently, the patient is followed up regularly and she is without signs of tumor relapse.

The second patient is the older daughter with positive diagnostic criteria for NF1, delayed psychomotor development and suspected convulsions. She was born from an unremarkable pregnancy and labor. The pediatrician noticed some hypotonia and delayed psychomotor development in the infancy period and later. Language development was markedly delayed. In infancy she had several episodes of generalized convulsions that resembled affective crises and the EEG was repeatedly normal. A brain MRI was performed at the age of 12; it revealed FASI bilaterally in both dentate nuclei of cerebellum. At the age of 13 she was diagnosed with thoracic kyphoscoliosis. The MRI of thoracic spine revealed dural ectasia at the level of anterior coalition of the body of the 6<sup>th</sup> and 7<sup>th</sup> thoracic vertebra with hypoplastic intervertebral discus and arcuate kyphosis. Ophthalmologic examination revealed multiple Lisch nodules of the iris. Physical examination performed at the age of 13 showed short stature (3<sup>rd</sup> centile), sinistroconvex kyphoscoliosis of thoracic spine, café au lait spots on the front and back of the chest and several subcutaneous neurofibromas. Signs of mild cognitive impairment were also present.

The third patient is the younger daughter with positive diagnostic criteria for NF1 and very rare presentation of



**Figure 2. Magnetic angiography in the younger daughter:** magnetic angiography showed left frontal, temporal and parietal pial angiomas and a hypoplastic spheroidal and opercular segment of the left middle cerebral artery (MCA), with many collaterals of lenticular and thalamostriate arteries.



**Figure 3. Digital subtraction angiography:** DSA showed bilateral stenosis of the internal carotid artery. Catheterization of the right common carotid artery and right inner carotid artery in the younger daughter showed terminal part stenosis of the right inner carotid artery (ICA) immediately before bifurcation (arrow); Filiform filling of the residual part of the right inner carotid artery lumen with a weaker filling of the distal segments of the circulation, i.e. right middle cerebral artery and right (MCA) and anterior cerebral artery (ACA).

NF1, moyamoya syndrome (MMS). She was born from an uneventful pregnancy and labor. Her mother noticed café au lait spots already in the infancy period. Her psychomotor development was moderately delayed, especially in the domain of cognitive and language development. At the age of 3, she experienced the first episode of epileptic seizures and she was given valproate as an antiepileptic drug. At the age of 4, she was diagnosed with occlusive cerebral angiopathy; MMS of the left internal carotid artery, middle cerebral artery, right internal carotid artery, right anterior and middle cerebral artery (Figure 2, Figure 3). Soon after the diagnosis, she experienced a transitory ischemic attack with left hemisyndrome, and she was neurosurgically treated in the foreign center (direct and indirect revascularization of affected blood vessels). After the operation her clinical state is stable, without new deficits in neurological examination and new epileptic attacks. Her school performance is very poor and there are signs of low moderate cognitive impairment.

Physical examination at the age of 10 revealed short stature (3<sup>rd</sup> centile), numerous café au lait spots, several subcutaneous neurofibromas and signs of moderate cognitive impairment.

### Genetic analysis

Targeted sequencing of the three probands generated a mean of 14 million total effective reads, with an average of 99.88% mapping to the reference genome. The average sequencing depth on the target sequence region per individual was tenfold. 230 SNPs and 2 InDels were detected in the proband 1, 234 SNPs and 2 InDels were detected in the proband 2, 231 SNPs and 3 InDels were detected in the proband 3. Commonly known variants, documented in the 1000 Genomes Project, dbSNP, NHLBI ESP6500 along with synonymous variants, were removed in order to find the candidate disease-causing variants. *In silico* programs were employed to predict the possible effects of nonsynonymous variants on protein functions. A heterozygous frameshift variant c.4482\_4483delTA (p.His1494GlnfsTer7) in the *NF1* gene was selected as a potential disease-causing variant for the probands of pedigree 1,2 and 3. Predicted pathogenicity analyses performed by different *in silico* programs (MutationTaster and SIFT) indicated that this variant was deleterious. After aligning the three protein

sequences for the conserved region, this shared NF1 frameshift mutation was discovered to be located in a conserved region (Figure 4).

### DISCUSSION

In this study, a novel frameshift NF1 variant was identified in a Croatian family with NF1 (a mother and two daughters). The novel variant c. 4482\_4483delTA leads to sequence change that creates a premature translational stop signal (p.His1494Glnfs\*7) in the NF1 gene. This variant is not present in population databases (ExAC no frequency). Loss-of-function variants in NF1 are known to be pathogenic.<sup>17, 18</sup> Multiple sequence alignment programs showed that the residue p.His1494 is phylogenetically conserved, and *in silico* programs indicated that they are damaging.

The variant is located in the GTPase-activating protein-related domain (GRD) of the protein, the best characterized functional domain of neurofibromin. Several studies have shown that the GRD domain has Ras-GAP activity both *in vitro* and *in vivo*.<sup>19</sup> Current data suggest that about 30–65% of patients with NF1 have specific learning deficits.<sup>20</sup> Although a direct correlation between specific mutations in NF1 and phenotypes has not been established, missense mutation that disrupts the Ras-GAP function of NF1 was found in patients with multiple symptoms including learning disability and cognitive impairment.<sup>21</sup> In general, in most NF1 patients with learning difficulties global cognitive impairment is not a very common feature.<sup>22</sup> Although carrying the same variant, our three patients show a range from normal cognitive function in the mother and mild cognitive impairment in the older daughter to moderate cognitive impairment in the younger daughter.

Only a few NF1 genotype-phenotype correlations have been identified due to its wide phenotypic diversity and the extreme variability of the mutation spectrum. The clearest genotype-phenotype correlation show gross constitutional deletions of the NF1 gene associated with a severe form of the disease and increased susceptibility to malignant peripheral nerve sheath tumors (MPNST).<sup>23, 24</sup> It was recently shown that patients with missense mutations in codons 844-848 have a high prevalence of a severe phenotype, including plexiform

```

P21359.2 1439 LKLSKILQSIANHVLFTKEEHRPFDNFVKSNFDAARRFFLDIASDCPTSDAVNHSLSFISDGNVLAHRLLLWNNQEKI 1518
P97526.1 1420 LKLSKVLQSIANHVLFTKEEHRPFDNFVKSNFLARRFFLDIASDCPTSDAVNHSLSFISDGNVLAHRLLLWNNQEKI 1499
Q04690.1 1441 LKLSKVLQSIANHVLFTKEEHRPFDNFVKSNFLARRFFLDIASDCPTSDAVNHSLSFISDGNVLAHRLLLWNNQEKI 1520
PROBANDS 1439 LKLSKILQSIANHVLFTKEEHRPFDNFVKSNFDAARRFFLDIASDCPTSDAVNQSFLHKSTOP

```

Figure 4. Location of the frameshift variant detected in mother and two daughters.

The mutated site was referred against NF1 or NF1 homolog gene from *Homo sapiens* (P21359.2), *Rattus norvegicus* (P97526.1) and *Mus musculus* (Q04690.1). The position of the frameshift mutation marked by an arrow; black letters show altered amino acids caused by the frameshift variant.

and symptomatic spinal neurofibromas, symptomatic optic pathway gliomas, other malignant neoplasms, as well as bone abnormalities.<sup>25</sup> Patients with deletion of Met 992 or missense mutation of Arg 1809 lack plexiform or cutaneous neurofibromas making these two germline mutations associated with milder disease outcomes in NF1.<sup>26-28</sup> Our patients showed intrafamilial phenotype variability: mother with rare malignant peripheral sheath tumor, older daughter with usual clinical presentation and younger daughter with very rare MMS and early severe presentation. This suggests that NF1 clinical phenotypes may be influenced not only by NF1 variants, but also by other factors, including second hit mutations, mosaicism, genetic modifiers, epigenetic and environmental factors.<sup>27, 29, 30</sup> Studies of twins with NF1 have revealed that each major symptom associated with NF1 is likely to be affected by distinct genetic modifiers.<sup>31</sup>

In our first patient (the mother), diagnosis of MPNST was established. MPNST are biologically aggressive soft tissue sarcomas that are challenging to treat effectively. About 10% of NF1 patients develop MPNST, and it is known that this type of tumors have high metastatic potential and poor prognosis.<sup>32, 33</sup> Large tumor size at presentation (typically >5 cm) has been the most consistently determined adverse prognostic factor.<sup>34</sup> Early diagnosis and surgery offer the most efficiency in treatment so far, chemotherapy and radiotherapy show no clear benefits for patient survival. Currently our patient is followed up regularly and she is without signs of tumor relapse. Discovery of the biomarkers for early detection of MPNSTs would be of great importance. As seen in our case presentation, it is hard to predict whether two daughters have a higher risk of developing MPNST. Besides biomarkers for early detection, patients with MPNSTs would benefit from accurate molecular prognostics markers. Study from Zou and colleagues showed that the expression level of p53 was significantly associated with a worse outcome.<sup>35</sup> Another study detected the AKT and TOR pathway, activated in a broad range of malignancies including sarcoma, with a negative prognosis proposing the inhibition of mTOR as a potential treatment target for both NF1-related and sporadic MPNSTs.<sup>36</sup> MET activation has been suggested as a molecular marker of inferior prognosis which is in line with data showing that MET targeting inhibits invasive phenotype of MPNST cells both *in vitro* and *in vivo*.<sup>37</sup>

MMS is a rare cerebrovascular disorder developing by stenosis and occlusion of small anastomotic vessels in the distal branches of bilateral internal carotid arteries. MMS occurs in 2.3-6% of children with NF1. Symptoms include neurological findings such as epileptic seizures, headache, paresthesia, dysphasia, nystagmus, aphasia, and borderline mental level.<sup>35, 36</sup> There are certain evidence indicating that MMS is related to genetic factors in familial cases, although the involvement of the NF1 gene in the occurrence of MMS remains controversial.<sup>37</sup> NF1 and MMS could be associated by close proximity of the responsible genes

on chromosome 17.<sup>38</sup> Our patient was diagnosed with MMS at the age 4, which is slightly earlier than observed in previous patients (mean age between 5.2 and 11.4 years). Apart from NF1, MMS is rarely observed in connection with other RASopathies. There is only one report on the genetic background of patients with NF1 showing no correlation between the NF1 genotype and MMS phenotype.<sup>39</sup>

In conclusion, we identified a novel frameshift variant c. 4482\_4483delTA in the NF1 gene in a mother and two daughters. Our study showed that even when the same germline NF1 variant has been identified, there is still huge phenotypic variability in patients, and it makes prognosis on the disease more complex. The development of next-generation sequencing technologies which allow rapid and accurate identification of disease-causing mutations becomes crucial for molecular characterization of NF1 patients as well as for patient follow-up in the context of genetic counseling and clinical management of patients.

### Acknowledgments

We thank the patients for their cooperation and contribution in this study.

### REFERENCES

1. Hirbe AC, Gutmann DH. Neurofibromatosis type 1: a multidisciplinary approach to care. *Lancet Neurol*. 2014;13(8):834-843.
2. Gutmann DH, Aylsworth A, Carey JC, Korf B, Marks J, Pyeritz RE, Rubenstein A, Viskochil D. The diagnostic evaluation and multidisciplinary management of neurofibromatosis 1 and neurofibromatosis 2. *JAMA*. 1997;278(1):51-57.
3. Hernandez-Martin A, Duat-Rodriguez A. An Update on Neurofibromatosis Type 1: Not Just Cafe-au-Lait Spots and Freckling. Part II. Other Skin Manifestations Characteristic of NF1. *NF1 and Cancer. Actas Dermosifiliogr*. 2016;107(6):465-473.
4. Rauen KA. The RASopathies. *Annu Rev Genomics Hum Genet*. 2013;14:355-369.
5. Belzeaux R, Lancon C. Neurofibromatosis type 1: psychiatric disorders and quality of life impairment. *Presse Med*. 2006;35(2 Pt 2):277-280.
6. Basu TN, Gutmann DH, Fletcher JA, Glover TW, Collins FS, Downward J. Aberrant regulation of ras proteins in malignant tumour cells from type 1 neurofibromatosis patients. *Nature*. 1992;356(6371):713-715.
7. Martin GA, Viskochil D, Bollag G, McCabe PC, Crosier WJ, Haubruck H, Conroy L, Clark R, O'Connell P, Cawthon RM, Innis MA, McCormik F. The GAP-related domain of the neurofibromatosis type 1 gene product interacts with ras p21. *Cell*. 1990;63(4):843-849.
8. Griffiths S, Thompson P, Frayling I, Upadhyaya M. Molecular diagnosis of neurofibromatosis type 1: 2 years experience. *Fam Cancer*. 2007;6(1):21-34.
9. Okumura A, Ozaki M, Niida Y. Development of a practical NF1 genetic testing method through the pilot analysis of five Japanese families with neurofibromatosis type 1. *Brain Dev*. 2015;37(7):677-689.
10. Wimmer K, Yao S, Claes K, Kehrer-Sawatzki H, Tinschert S, De Raedt T, Legius E, Callens T, Beiglböck H, Maertens O, Messiaen L. Spectrum of single- and multiexon NF1 copy number changes in a cohort of 1,100 unselected NF1

- patients. *Genes Chromosomes Cancer*. 2006;45(3):265-276.
11. van Minkelen R, van Bever Y, Kromosoeto JN, Withagen-Hermans CJ, Nieuwlaet A, Halley DJ, van den Ouweland AM. A clinical and genetic overview of 18 years neurofibromatosis type 1 molecular diagnostics in the Netherlands. *Clin Genet*. 2014;85(4):318-327.
  12. Pasmant E, Parfait B, Luscan A, Goussard P, Briand-Suleau A, Laurendeau I, Fouveaut C, Leroy C, Montadert A, Wolkenstein P, Vidaud M, Vidaud D. Neurofibromatosis type 1 molecular diagnosis: what can NGS do for you when you have a large gene with loss of function mutations? *Eur J Hum Genet*. 2015;23(5):596-601.
  13. Wu-Chou YH, Hung TC, Lin YT, Cheng HW, Lin JL, Lin CH, Yu CC, Chen KT, Yeh TH, Chen YR. Genetic diagnosis of neurofibromatosis type 1: targeted next-generation sequencing with Multiple Ligation-Dependent Probe Amplification analysis. *J Biomed Sci*. 2018;25(1):72.
  14. Uusitalo E, Hammais A, Palonen E, Brandt A, Makela VV, Kallionpaa R, Jouhilahti EM, Poyhonen M, Soini J, Peltonen J, Peltonen S. Neurofibromatosis type 1 gene mutation analysis using sequence capture and high-throughput sequencing. *Acta Derm Venereol*. 2014;94(6):663-666.
  15. Maruoka R, Takenouchi T, Torii C, Shimizu A, Misu K, Higasa K, Matsuda F, Ota A, Tanito K, Kuramochi A, Arima Y, Otsuka F, Yoshida Y, Moriyama K, Niimura M, Saya H, Kosaki K. The use of next-generation sequencing in molecular diagnosis of neurofibromatosis type 1: a validation study. *Genet Test Mol Biomarkers*. 2014;18(11):722-735.
  16. DeBella K, Szudek J, Friedman JM. Use of the national institutes of health criteria for diagnosis of neurofibromatosis 1 in children. *Pediatrics*. 2000;105:608-614.
  17. Fahsold R, Hoffmeyer S, Mischung C, Gille C, Ehlers C, Kucukceylan N, Abdel-Nour M, Gewies A, Peters H, Kaufmann D, Buske A, Tinschert S, Nurnberg P. Minor lesion mutational spectrum of the entire NF1 gene does not explain its high mutability but points to a functional domain upstream of the GAP-related domain. *Am J Hum Genet*. 2000;66(3):790-818.
  18. Sabbagh A, Pasmant E, Imbard A, Luscan A, Soares M, Blanche H, Laurendeau I, Ferkal S, Vidaud M, Pinson S, Bellanne-Chantelot C, Vidaud D, Parfait B, Wolkenstein P. NF1 molecular characterization and neurofibromatosis type I genotype-phenotype correlation: the French experience. *Hum Mutat*. 2013;34(11):1510-1518.
  19. Xu GF, O'Connell P, Viskochil D, Cawthon R, Robertson M, Culver M, Dunn D, Stevens J, Gesteland R, White R, Weiss R. The neurofibromatosis type 1 gene encodes a protein related to GAP. *Cell*. 1990;62(3):599-608.
  20. Rosser TL, Packer RJ. Neurocognitive dysfunction in children with neurofibromatosis type 1. *Curr Neurol Neurosci Rep*. 2003;3(2):129-136.
  21. Klose A, Ahmadian MR, Schuelke M, Scheffzek K, Hoffmeyer S, Gewies A, Schmitz F, Kaufmann D, Peters H, Wittinghofer A, Nurnberg P. Selective inactivation of neurofibromin GAP activity in neurofibromatosis type 1. *Hum Mol Genet*. 1998;7(8):1261-1268.
  22. Shilyansky C, Lee YS, Silva AJ. Molecular and cellular mechanisms of learning disabilities: a focus on NF1. *Annu Rev Neurosci*. 2010;33:221-243.
  23. Pasmant E, Sabbagh A, Spurlock G, Laurendeau I, Grillo E, Hamel MJ, Martin L, Barbarot S, Leheup B, Rodriguez D, Lacombe D, Dollfus H, Pasquier L, Isidor B, Ferkal S, Soulier J, Sanson M, Dieux-Coeslier A, Bieche I, Parfait B, Vidaud M, Wolkenstein P, Upadhyaya M, Vidaud D, members of the NF France Network. NF1 microdeletions in neurofibromatosis type 1: from genotype to phenotype. *Hum Mutat*. 2010;31(6):E1506-1518.
  24. Upadhyaya M, Ruggieri M, Maynard J, Osborn M, Hartog C, Mudd S, Penttinen M, Cordeiro I, Ponder M, Ponder BA, Krawczak M, Cooper DN. Gross deletions of the neurofibromatosis type 1 (NF1) gene are predominantly of maternal origin and commonly associated with a learning disability, dysmorphic features and developmental delay. *Hum Genet*. 1998;102(5):591-597.
  25. Koczkowska M, Chen Y, Callens T, Gomes A, Sharp A, Johnson S, Hsiao MC, Chen Z, Balasubramanian M, Barnett CP, Becker TA, Ben-Shachar S, Bertola DR, Blakeley JO, Burkitt-Wright EMM, Callaway A, Crenshaw M, Cunha KS, Cunningham M, D'Agostino MD, Dahan K, De Luca A, Destree A, Dhamija R, Eoli M, Evans DGR, Galvin-Parton P, George-Abraham JK, Gripp KW, Guevara-Campos J, Hanchard NA, Hernandez-Chico C, Immken L, Janssens S, Jones KJ, Keena BA, Kochhar A, Liebelt J, Martir-Negron A, Mahoney MJ, Maystadt I, McDougall C, McEntagart M, Mendelsohn N, Miller DT, Mortier G, Morton J, Pappas J, Plotkin SR, Pond D, Rosenbaum K, Rubin K, Russell L, Rutledge LS, Saletti V, Schonberg R, Schreiber A, Seidel M, Siqveland E, Stockton DW, Trevisson E, Ullrich NJ, Upadhyaya M, van Minkelen R, Verhelst H, Wallace MR, Yap YS, Zackai E, Zonana J, Zurcher V, Claes K, Martin Y, Korf BR, Legius E, Messiaen LM. Genotype-Phenotype Correlation in NF1: Evidence for a More Severe Phenotype Associated with Missense Mutations Affecting NF1 Codons 844-848. *Am J Hum Genet*. 2018;102(1):69-87.
  26. Pinna V, Lanari V, Daniele P, Consoli F, Agolini E, Margiotti K, Bottillo I, Torrente I, Bruxelles A, Fusilli C, Ficcadenti A, Bargiacchi S, Trevisson E, Forzan M, Giustini S, Leoni C, Zampino G, Digilio MC, Dallapiccola B, Clementi M, Tartaglia M, De Luca A. p.Arg1809Cys substitution in neurofibromin is associated with a distinctive NF1 phenotype without neurofibromas. *Eur J Hum Genet*. 2015;23(8):1068-1071.
  27. Rojnueangnit K, Xie J, Gomes A, Sharp A, Callens T, Chen Y, Liu Y, Cochran M, Abbott MA, Atkin J, Babovic-Vuksanovic D, Barnett CP, Crenshaw M, Bartholomew DW, Basel L, Bellus G, Ben-Shachar S, Bialer MG, Bick D, Blumberg B, Cortes F, David KL, Destree A, Duat-Rodriguez A, Earl D, Escobar L, Eswara M, Ezquieta B, Frayling IM, Frydman M, Gardner K, Gripp KW, Hernandez-Chico C, Heyrman G, Ibrahim J, Janssens S, Keena BA, Llano-Rivas I, Leppig K, McDonald M, Misra V K, Mulbury J, Narayanan V, Orenstein N, Galvin-Parton P, Pedro H, Pivnick EK, Powell CM, Randolph L, Raskin S, Rosell J, Rubin K, Seashore M, Schaa CP, Scheuerle A, Schultz M, Schorry E, Schnur R, Siqveland E, Tkachuk A, Tongsgard J, Upadhyaya M, Verma IC, Wallace S, Williams C, Zackai E, Zonana J, Lazaro C, Claes K, Korf B, Martin Y, Legius E, Messiaen L. High Incidence of Noonan Syndrome Features Including Short Stature and Pulmonic Stenosis in Patients carrying NF1 Missense Mutations Affecting p.Arg1809: Genotype-Phenotype Correlation. *Hum Mutat*. 2015;36(11):1052-1063.
  28. Upadhyaya M, Huson SM, Davies M, Thomas N, Chuzhanova N, Giovannini S, Evans DG, Howard E, Kerr B, Griffiths S, Consoli C, Side L, Adams D, Pierpont M, Hachen R, Barnicoat A, Li H, Wallace P, Van Biervliet JP, Stevenson D, Viskochil D, Baralle D, Haan E, Riccardi V, Turnpenny P, Lazaro C, Messiaen L. An absence of cutaneous neurofibromas associated with a 3-bp inframe deletion in Exon 17 of the NF1 gene (c.2970-2972 delAAT): evidence of a clinically significant NF1 genotype-phenotype correlation. *American Journal of Human Genetics*. 2007;80(1):140-151.
  29. Pemov A, Sung HJ, Hyland PL, Sloan, JL, Ruppert, SL, Baldwin AM, Boland JF, Bass SE, Lee HJ, Jones KM, Zhang XJ, Mullikin JC, Widemann BC, Wilson AF, Stewart DR, NISC Comparative Sequencing. Genetic Modifiers of Neurofibromatosis Type 1-Associated Cafe-au-Lait Macule Count Identified Using Multi-platform Analysis. *Plos Genet*. 2014;10(10).
  30. Cichowski K, Jaks T. NF1 tumor suppressor gene function: Narrowing the GAP. *Cell*. 2001;104(4):593-604.
  31. Rieley MB, Stevenson DA, Viskochil DH, Tinkle BT, Martin LJ, Schorry EK. Variable Expression of

- Neurofibromatosis 1 in Monozygotic Twins. *Am J Med Genet A*. 2011;155a(3):478-485.
32. Evans DG, Baser ME, McGaughran J, Sharif S, Howard E, Moran A. Malignant peripheral nerve sheath tumours in neurofibromatosis 1. *J Med Genet*. 2002;39(5):311-314.
  33. Farid M, Demicco EG, Garcia R, Ahn L, Merola PR, Cioffi A, Maki RG. Malignant peripheral nerve sheath tumors. *Oncologist*. 2014;19(2):193-201.
  34. LaFemina J, Qin LX, Moraco NH, Antonescu CR, Fields RC, Crago AM, Brennan MF, Singer S. Oncologic outcomes of sporadic, neurofibromatosis-associated, and radiation-induced malignant peripheral nerve sheath tumors. *Ann Surg Oncol*. 2013;20(1):66-72.
  35. Zou C, Smith KD, Liu J, Lahat G, Myers S, Wang WL, Zhang W, McCutcheon IE, Slopis JM, Lazar AJ, Pollock RE, Lev D. Clinical, pathological, and molecular variables predictive of malignant peripheral nerve sheath tumor outcome. *Ann Surg*. 2009;249(6):1014-1022.
  36. Endo M, Yamamoto H, Setsu N, Kohashi K, Takahashi Y, Ishii T, Iida K, Matsumoto Y, Hakozaiki M, Aoki M, Iwasaki H, Dobashi Y, Nishiyama K, Iwamoto Y, Oda Y. Prognostic significance of AKT/mTOR and MAPK pathways and antitumor effect of mTOR inhibitor in NF1-related and sporadic malignant peripheral nerve sheath tumors. *Clin Cancer Res*. 2013;19(2):450-461.
  37. Torres KE, Zhu QS, Bill K, Lopez G, Ghadimi MP, Xie X, Young ED, Liu J, Nguyen T, Bolshakov S, Belousov R, Wang S, Lahat G, Liu J, Hernandez B, Lazar AJ, Lev D. Activated MET is a molecular prognosticator and potential therapeutic target for malignant peripheral nerve sheath tumors. *Clin Cancer Res*. 2011;17(12):3943-3955.
  38. Ghosh PS, Rothner AD, Emch TM, Friedman NR, Moodley M. Cerebral Vasculopathy in Children With Neurofibromatosis Type 1. *J Child Neurol*. 2013;28(1):95-101.
  39. Duat-Rodriguez A, Lechon FC, Pino MAL, Fernandez CR, Gonzalez-Gutierrez-Solana L. Neurofibromatosis Type 1 Associated With Moyamoya Syndrome in Children. *Pediatr Neurol*. 2014;50(1):96-98.
  40. Vargiami E, Sapountzi E, Samakovitis D, Batzios S, Kyriazi M, Anastasiou A, Zafeiriou, DI. Moyamoya syndrome and neurofibromatosis type 1. *Ital J Pediatr*. 2014;40:59.
  41. Bekiesinska-Figatowska M, Bragoszewska H, Duczkowski M, Romaniuk-Doroszevska A, Szkudlinska-Pawlak S, Duczkowska A, Madzik J, Kowalska B, Peczkowski P. Circle of Willis abnormalities in children with neurofibromatosis type 1. *Neurol Neurochir Pol*. 2014;48(1):15-20.
  42. Santoro C, Di Rocco F, Kossorotoff M, Zerah M, Boddaert N, Calmon R, Vidaud D, Cirillo M, Cinalli G, Miron G, Giugliano T, Piluso G, D'Amico A, Capra V, Pavanello M, Cama A, Nobili B, Lyonnet S, Perrotta S. Moyamoya syndrome in children with neurofibromatosis type 1: Italian-French experience. *Am J Med Genet A*. 2017;173(6):1521-1530.