

Furuncular Myiasis of the Lower Leg

A 35-year-old Caucasian woman, otherwise healthy, presented with a four weeks history of painful, inflammatory nodules, each with a central opening on her right lower leg (Figure 1). Intermittently, a marked serosanguinous secretion was noted. The remaining skin and mucosa were not affected. The patient denied any history of trauma. One month earlier she had returned from a journey to Peru. Despite topical treatment with corticosteroids and antibiotics as well as systemic therapy with oral doxycycline, the lesions did not show any regression or reduction in their secretion. An incisional biopsy was performed at all sites and the extracted organic specimens were submitted for histopathological assessment. Histopathology revealed a mixed inflammatory dermal infiltrate consisting of numerous eosinophils admixed with some histiocytes and lymphocytes. Furthermore, an organic foreign body with an eosinophilic cuticle consistent with DH became evident (Figure 2, a-e).

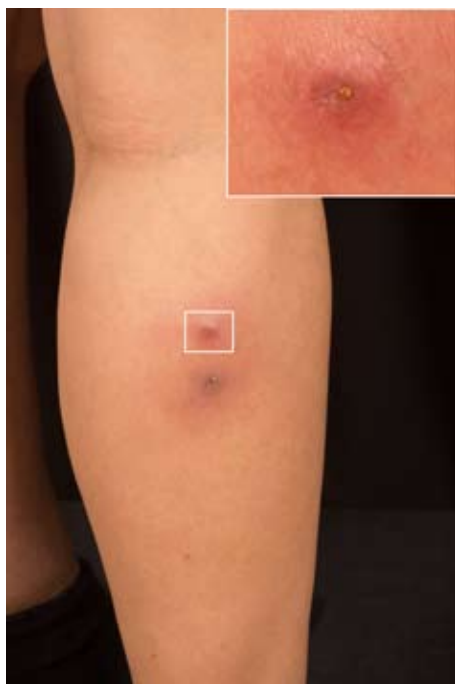

Figure 1. Furuncular lesions on the lower leg. The inset depicts a close-up view of the upper lesion with its central opening.

Human myiasis represents the infestation of humans by developing dipterous larvae (maggots) of various fly species (1). The most common flies causing human myiasis are *Dermatobia hominis* (DH, "human botfly") and, less frequently, *Cordylobia anthropophaga* ("tumbu fly") or *Cordylobia rodhaini* (1).

DH is indigenous in Central and South America, but in Europe and the United States of America only cases of travelers that imported the infestation have been described (2,3). The adult DH is a yellow-headed fly with a grey-blue body of approximately 15 mm. DH is active throughout the year and predominantly found in humid and high temperature regions of Central and South America (2). The larvae of DH develop as obligate parasites in living tissue, causing furuncular myiasis (2,4). Clinically crusted nodules with serosanguinous secretion and sometimes nocturnal pain affecting uncovered anatomical sites are typical (2,4). Differential diagnoses include bacterial furunculosis, arthropod bite reaction, pyoderma, inflamed epidermoid cysts, or cutaneous leishmaniasis (2,5-7). Most cases of furuncular myiasis can be diagnosed solely by their clinical presentation and after carefully taking the patients' history. Nevertheless, dermoscopy and sonography may help to confirm the diagnosis and rule out the abovementioned differential diagnoses (6,7). Although myiasis is a self-limited disease, it can be accompanied by severe complications including tetanus or bacterial superinfections (2). The literature reports a number of treatment options including a) occlusion of the skin opening by paraffin oil, beeswax, petroleum jelly or agents such as liquid nitrogen or ethyl chloride sprays to suffocate the larva and promote self-extrusion; b) removing the larva by forceps after lidocaine instillation; c) surgical removal or d) the use of topical or oral ivermectin (1,8,9). Preventive measures include protective clothing, insect repellents, and sleeping curtains.

Histopathology of furuncular myiasis typically reveals a mixed inflammatory infiltrate of eosinophils, lymphocytes, and macrophages. Sometimes formation of granulomas with giant cells becomes evident (10). Fly larvae show a thick eosinophilic cuticle with external facing sclerotized spines. Internal structures (respiratory and digestive tracts or striated muscle)

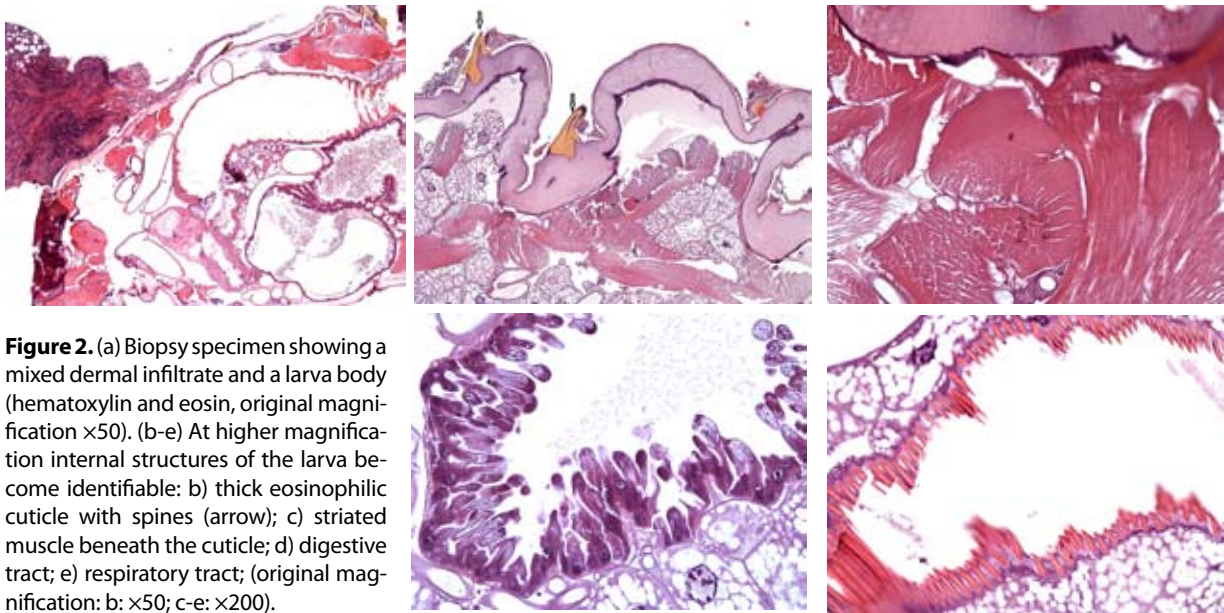


Figure 2. (a) Biopsy specimen showing a mixed dermal infiltrate and a larva body (hematoxylin and eosin, original magnification $\times 50$). (b-e) At higher magnification internal structures of the larva become identifiable: b) thick eosinophilic cuticle with spines (arrow); c) striated muscle beneath the cuticle; d) digestive tract; e) respiratory tract; (original magnification: b: $\times 50$; c-e: $\times 200$).

may occasionally be identified (10), (Figure 2, b-e). In most cases, tissue sections will not be sufficient to identify the fly's genus or its species; however, identification by stereomicroscopy has been reported (10).

In conclusion, we described the clinical and histopathological features of furuncular myiasis by DH in a traveler returning from Peru. Given the ever-increasing numbers of international travelers, western dermatopathologists and dermatologists should be familiar with this disease to avoid prescription of unnecessary topical or systemic medications.

References:

1. Blaizot R, Vanhecke C, Le Gall P, Duvignaud A, Receveur MC, Malvy D. Furuncular myiasis for the Western dermatologist: treatment in outpatient consultation. *Int J Dermatol.* 2018;57:227-30.
2. Uslu U, Erdmann M, Schliep S, Sticherling M. Crusted nodules on the lower left arm in a traveler returning from South America. A quiz. *Acta Derm Venereol.* 2018;98:159-60.
3. Lembo S, Patri A, Lembo C, Balato A. Surprise from skin nodules after travel to South America. *J Eur Acad Dermatol.* 2015;29:1237-8.
4. McGraw TA, Turiansky GW. Cutaneous myiasis. *J Am Acad Dermatol.* 2008;58:907-26.
5. Sampson CE, MaGuire J, Eriksson E. Botfly myiasis: case report and brief review. *Ann Plast Surg.* 2001;46:150-2.
6. Bakos RM, Bakos L. Dermoscopic diagnosis of furuncular myiasis. *Arch Dermatol.* 2007;143:123-4.
7. Szczurko C, Domp Martin A, Moreau A, Belloy F, Remond B, Leroy D. Ultrasonography of furuncular cutaneous myiasis: detection of *Dermatobia hominis* larvae and treatment. *Int J Dermatol.* 1994;33:282-3.
8. Rodriguez-Cerdeira C, Gregorio MC, Guzman RA. *Dermatobia hominis* infestation misdiagnosed as abscesses in a traveler to Spain. *Acta Dermatovenereol Croat.* 2018;26:267-9.
9. Pathania V, Kashif AW, Aggarwal RN. Cutaneous myiasis: Think beyond furunculosis. *Med J Armed Forces India.* 2018;74:268-72.
10. Norgan AP, Pritt BS. Parasitic Infections of the skin and subcutaneous tissues. *Adv Anat Pathol.* 2018;25:106-23.

**Ferdinand Toberer, Susanne Hanner,
Georg Haus, Holger A. Haenssle**

Department of Dermatology, Venerology and Allergology, University Medical Center, Ruprecht-Karls-University, Heidelberg, Germany

Corresponding author:

Ferdinand Toberer, MD
Department of Dermatology, Venerology and Allergology, University Medical Center, Ruprecht-Karls-University
Im Neuenheimer Feld
69120 Heidelberg
Germany
ferdinand.toberer@med.uni-heidelberg.de

Received: October 3, 2018
Accepted: August 10, 2019