



Pyridostigmine in Pediatric Intestinal Pseudo-obstruction: Case Report of a 2-year Old Girl and Literature Review

Giovanni Di Nardo,¹ Federica Viscogliosi,² Francesco Esposito,³ Vincenzo Stanghellini,⁴ Maria Pia Villa,¹ Pasquale Parisi,¹ Alessia Morlando,² Girolamo Calò,⁵ and Roberto De Giorgio^{5*}

¹NESMOS Department, School of Medicine and Psychology, Sapienza University of Rome, Sant'Andrea University Hospital, Rome, Italy;

²Department of Translational Medical Science, Section of Pediatrics, University of Naples "Federico II," Naples, Italy; ³Radiology Unit, Santobono-Pausilipon Children's Hospital, Naples, Italy; ⁴Department of Medical and Surgical Sciences, St. Orsola-Malpighi Hospital, University of Bologna, Italy; and ⁵Department of Medical Sciences, University of Ferrara, Ferrara, Italy

Pediatric chronic intestinal pseudo-obstruction is a rare disorder characterized by a severe impairment of gastrointestinal motility leading to intestinal obstruction symptoms in the absence of mechanical causes. The diagnosis is usually clinical and diagnostic work is usually aimed to rule out mechanical obstruction and to identify any underlying diseases. Treatment is challenging and requires a multidisciplinary effort. In this manuscript we describe the youngest child successfully treated with the orally administrable, long-acting, reversible anti-cholinesterase drug, pyridostigmine. Like other drugs belonging to cholinesterase inhibitors, pyridostigmine enhances gut motility by increasing acetylcholine availability in the enteric nervous system and neuro-muscular junctions. Based on the direct evidence from the reported case, we reviewed the current literature on the use of pyridostigmine in severe pediatric dysmotility focusing on intestinal pseudo-obstruction. The overall data emerged from the few published studies suggest that pyridostigmine is an effective and usually well tolerated therapeutic options for patients with intestinal pseudo-obstruction. More specifically, the main results obtained by pyridostigmine included marked reduction of abdominal distension, reduced need of parenteral nutrition, and improvement of oral feeding. The present case and review on pyridostigmine pave the way for eagerly awaited future randomized controlled studies testing the efficacy of cholinesterase inhibitors in pediatric severe gut dysmotility.

(J Neurogastroenterol Motil 2019;25:508-514)

Key Words

Cholinesterase inhibitors; Enteric nervous system; Gastrointestinal motility; Intestinal pseudo-obstruction; Pyridostigmine bromide

Introduction

Chronic intestinal pseudo-obstruction (CIPO) is characterized by a severe impairment of gastrointestinal (GI) motility leading to signs and symptoms indicative of intestinal obstruction in the ab-

sence of any occluding lesion.¹ Although rare, CIPO is an extremely challenging condition that can be diagnosed in adult and pediatric patients. There are many similarities between adult and pediatric CIPO, but recently published guidelines suggested that pediatric CIPO should be considered as a specific category of CIPO, hence the term PIPO (pediatric intestinal pseudo-obstruction).²

Received: April 8, 2019 Revised: June 4, 2019 Accepted: July 20, 2019

© This is an Open Access article distributed under the terms of the Creative Commons Attribution Non-Commercial License (<http://creativecommons.org/licenses/by-nc/4.0>) which permits unrestricted non-commercial use, distribution, and reproduction in any medium, provided the original work is properly cited.

*Correspondence: Roberto De Giorgio, MD, PhD, AGAF

Department of Medical Sciences, University of Ferrara, Internal Medicine Unit, St. Anna Hospital, Via A. Moro 8, Cona 44124, Ferrara, Italy

Tel: +39-0532-236-374, Fax: +39-0532-239-547, E-mail: dgrrrt@unife.it; deg@aosp.bo.it

So far, the management of PIPO is aimed to avoid unnecessary surgery (ie, cases should carefully assessed prior to a true surgical referral is established), recommend supportive measures, such as fluid and electrolyte balance, nutritional support (often via parenteral nutrition, while enteral is usually not indicated because of severe dysmotility), and symptomatic treatments mainly for nausea/vomiting, diarrhea due to underlying small intestine bacterial overgrowth (SIBO) and abdominal pain.^{1,2} In addition, a key therapeutic target is given by prokinetic agents, which are expected to improve altered motility thereby ameliorating symptoms and signs of PIPO.² Prokinetics, eg, metoclopramide, domperidone, erythromycin, cisapride, tegaserod, prucalopride, neostigmine, and pyridostigmine, have been used both in CIPO and PIPO to improve intestinal motor function and to reduce related symptoms; however, their use has been limited by variable efficacy and, for some of them, major unacceptable side-effects leading to life-threatening consequences.² Cholinesterase inhibitors (CIs) exhibiting prokinetic properties with efficacy in controlling symptoms related to acute or chronic severe gut dysmotility. CIs, including neostigmine and pyridostigmine, increase GI motility by preventing the degradation of acetylcholine, the main excitatory neurotransmitter in the GI tract, thus increasing its concentration in the synaptic cleft.^{3,4}

A recent meta-analysis showed that neostigmine is a safe and effective option for patients with acute colonic pseudo-obstruction who failed to respond to conservative management.⁵ In children with hematologic malignancies and acute colonic pseudo-obstruction neostigmine has been successfully used without side effects.^{6,7} Pyridostigmine, an orally long-acting reversible CI, has been used with success in adult patients with CIPO who failed standard therapies.⁸ There are very limited data regarding the use and the efficacy of pyridostigmine in PIPO patients.⁹⁻¹²

In this manuscript we describe a 2-year old girl with PIPO successfully treated with pyridostigmine and review the available literature on the use of this drug in this severe form of gut dysmotility. To our knowledge this is the youngest child with PIPO treated with pyridostigmine. The parents of the herein reported child gave their consent to all diagnostic procedures and case report publication.

Case Report

A 2-year and 4-month old girl was referred to the Emergency Department of the Santobono-Pausilipon Children's Hospital, Naples, Italy, for persistent vomiting, diarrhea, and hypoglycemia associated to lethargy and asthenia. She had a long-term history of constipation, food refusal, and poor weight and height gain start-

ing from the beginning of the weaning. On admission, the patient's weight and height were 9.05 kg and 84 cm, respectively. Physical examination revealed poor clinical conditions, skin pallor, evident signs of dystrophy, and markedly distended and meteoric abdomen, with evident superficial venous reticulum. Laboratory tests were normal except for an elevated C-reactive protein (15.7 mg/L, normal value < 5). During hospitalization, specific virological examinations disclosed rotavirus and adenovirus infection. Radiologic findings showed gaseous distension of bowel loops with evident air-fluid levels (Fig. 1). A CT-enterography showed massive dilation of the entire GI tract, including esophagus and rectum, in the absence of mechanical causes (Fig. 2). Esophago-gastro-duodenoscopy and colonoscopy (with mucosal biopsies) were normal. Gastrografin enema showed massive colo-rectal dilation. Histopathological examination of suction rectal biopsies excluded Hirschsprung's disease. Based on clinical and radiological findings a diagnosis of PIPO was established. Due to the persistence of abdominal distention, colicky abdominal pain and vomiting in the absence of spontaneous bowel movements the patient was managed with parenteral nutrition, oral metronidazole, and rectal tube placement to facilitate intestinal decompression. During parenteral nutrition there was an improvement of abdominal distension and pain in the absence of vomiting, whereas bowel movements were absent. She tolerated amino acid formula, but all re-feeding attempts with solid foods induced rapid symptom recurrence (ie, intestinal subocclusive crisis). After 20

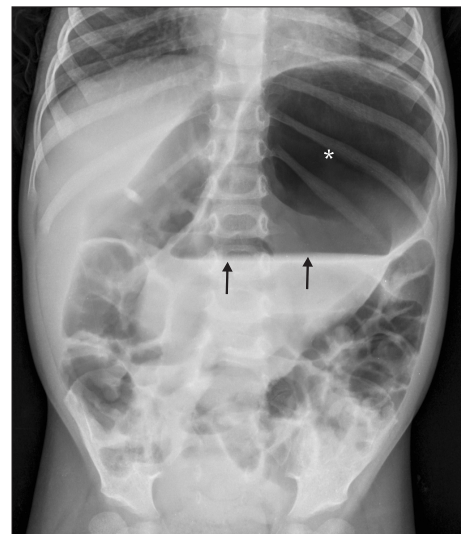


Figure 1. Upright plain abdominal radiograph showing markedly dilated bowel loops with clear-cut air-fluid levels in the reported patient. Notably, a massive gastric dilatation (*) with fluid stagnation (arrows) is clearly detectable.

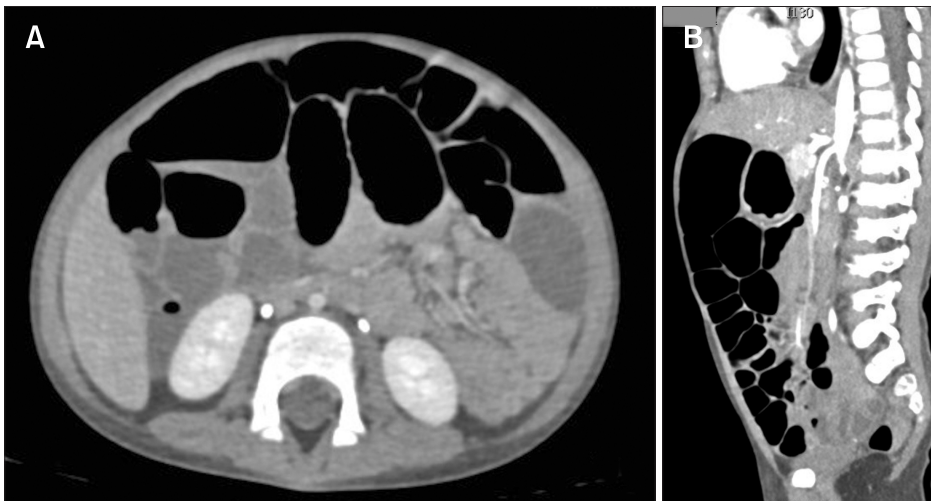


Figure 2. Contrast enhanced abdominal CT scan performed during the diagnostic work-up in order to rule out possible adhesions. (A) Axial and (B) sagittal reformatted images illustrate a massive dilatation involving the entire gastrointestinal tract.

days, the baby had a *Candida albicans*-central venous catheter-related sepsis successfully treated with intravenous fluconazole (5 mg/kg twice a day [bid]) and catheter removal.

In an attempt to improve gut motility, the patient was treated with pyridostigmine at a dose of 2 mg/kg bid and gradually increased to 3 mg/kg bid, with drug safety being monitored via heart rate and breathing. After 3 days she had a good clinical response with disappearance of vomiting, reduction of abdominal distension, and occurrence of spontaneous bowel movements. Also, she was able to tolerate a normal caloric intake (1000 kcal/day) and after 3 months there was a weight gain of 1.5 kg.

Discussion

Both CIPO and PIPO are the most severe clinical phenotypes of gut motility disorders with significant morbidity and potentially lethal consequences.^{1,2} Likewise CIPO, also PIPO is a rare disease with poorly defined incidence and prevalence in the general population. Specifically for PIPO, limited epidemiological data suggested an incidence of approximately 1 per 40 000 live births in the United States. Half to two-thirds of patients manifest their disease within the first month of life and 80% in the first year of age. The remainders are detected sporadically throughout the first 2 decades of life.² The diagnosis should be suspected in any child manifesting with symptoms of intestinal obstruction without an occluding lesion. The clinical manifestations of PIPO depend on the regions of the GI tract involved and the dynamics of presentation that is acute, intermittent or chronic. Various triggers including infections, general anesthesia and emotional stress may precipitate exacerbations with subocclusive episodes. Diarrhea due to bacterial overgrowth is

frequent, and may alternate with constipation or intestinal subocclusive episodes. Abdominal pain, often resulting from even minimal amount of eating, may be severe enough to lead to feeding difficulties resulting in malnutrition.^{1,2} Dysmotility of the gallbladder and cholelithiasis may complicate the clinical picture, increase the morbidity, and worsen the prognosis of this condition.^{1,2} Urinary tract involvement occurs in 33% to 92% of cases.² Megacystis with a hypocontractile detrusor is the most frequent pattern of urological abnormality. Uretero-hydronephrosis is seen in 56% to 68% of cases, although vesico-ureteral reflux occurs in less than 10%.² Based on this background, it is clear that PIPO is a challenging condition for most physicians. Two main aspects should be pointed out about the reported case: (1) the symptoms/signs at the beginning of the weaning, the progressive deterioration of her clinical condition, and failure to thrive had been underestimated; and (2) an acute episode of viral gastroenteritis, due to a combination of rotavirus and adenovirus infection, was probably the trigger precipitating the onset of the disease. Indeed post-acute/post-infectious CIPO and PIPO have been previously reported and about 25% of CIPO cases has some relationship with a demonstrable infection occurring in the clinical history prior to the onset of enteric dysmotility.^{2,13} The recurrent episodes of intestinal sub-occlusion along with the results of endoscopic and imaging tests, including plain abdominal radiographs and a CT-enterography, excluded any mechanical obstructions, and showed diffuse GI dilatation, thus leading to the diagnosis of PIPO. For the sake of clarity, we would like to point out that this patient is still under scrutiny for genetic abnormalities affecting the neuro-muscular integrity of the GI tract. The possibility of underlying enteric neuro-muscular changes may be plausible in the reported case, but specific tests, such as intestinal manometry

or small bowel full thickness histopathology were not attempted. Also, other tests were negative for major neurological impairment or secondary forms of PIPO.

Another challenge of this case was how to manage such a young baby showing a severe, potentially life-threatening gut bowel dysfunction. Indeed, central vein catheter-related septicemia is a frequent and potentially fatal complication in patients with parenteral nutrition.¹⁴ When septicemia occurs, the catheter should be removed, which is a measure exposing these fragile patients to an increased risk of metabolic abnormalities. In the following paragraphs we highlighted the possible beneficial effects of CIs as emerged by the direct experience of this case. CIs may represent a possible option for managing such difficult cases and this knowledge may aid pediatricians, and more broadly, physicians dealing with PIPO.

Management of Pediatric Intestinal Pseudo-obstruction With Pyridostigmine: Review of Current Literatures

Similarly to CIPO, the pillars of PIPO management are primarily directed to: (1) avoid unnecessary surgery, (2) restore fluid and electrolyte balance, (3) maintain an adequate caloric intake (via enteral or parenteral nutrition when needed), and (4) provide pharmacological support aimed at improving coordinated intestinal motility, treat severe symptoms (ie, abdominal pain, disabling nausea, and vomiting), and limit complications such as the occurrence of sepsis and SIBO.^{1,2} The term prokinetics is used to indicate a number of pharmacological compounds capable of improving GI motility, ranging from dopamine receptor antagonists (eg, domperidone and metoclopramide), motilin receptor agonists (erythromycin and azithromycin), and 5-hydroxytryptamine 4 receptor agonists (such as cisapride, tegaserod, and prucalopride), and CIs (neostigmine and pyridostigmine). Only scant data exist on the effects of prokinetics in CIPO and PIPO, but overall, current evidence suggests that beneficial effects can be obtained in some patients. Because of the severe symptoms patients with intestinal pseudo-obstruction and marked intestinal dilatation, CIs are emerging as a practical therapeutic option hopefully useful for both CIPO and PIPO patients. Indeed, the herein case report suggests the interesting possibility that CIs can be safe and effective in the very peculiar pediatric setting represented by the very first years of age.

Pharmacological Properties

Reversible CIs are well known drugs, which were mainly used in general anesthesia and in the symptomatic treatment of patients

with myasthenia gravis.¹⁵ In the GI tract, the inhibition of choline acetyl esterase enzyme increases the availability of acetylcholine at the neuro-neuronal synaptic cleft within the enteric nervous system as well as at neuromuscular junctions. As a result, acetylcholine, acting via nicotinic (neuro-neuronal site) and muscarinic (neuromuscular site) receptors, leads to smooth muscle contractions, which is the basic mechanism for enhancing motility.³ CIs include various molecules, the best known being neostigmine, pyridostigmine and physostigmine. Unlike neostigmine and pyridostigmine, physostigmine crosses the blood brain barrier and its use is substantially limited to toxicological applications or anesthesiological settings. However, in patients with increased blood-brain barrier permeability, pyridostigmine and neostigmine therapy may rarely trigger psychopathological symptoms/signs creating even psychotic pictures.¹⁶ A central cholinergic syndrome caused by the ability of CIs to cross the blood-brain barrier, as a result of an inflammatory or concomitant genetic background, may cause these neurological side effects.

Neostigmine and pyridostigmine show similar clearance (0.5-1 L/hr/kg) and comparable short half-lives (in the range of 30 minutes to 90 minutes), but they differ in terms of bioavailability with pyridostigmine being about 20-30% vs only 1-2% for neostigmine, since the former is usually administered by the oral route, while the latter is typically given intravenously. The difference in bioavailability is probably responsible for a more rapid effect of neostigmine, compared to pyridostigmine in the clinical setting.^{17,18} Finally, a pharmacodynamic parameter that is sometimes used to monitor CIs is represented by red blood cell cholinesterase activity, especially when CIs are administered in patients with chronic diseases such as myasthenia gravis.¹⁹⁻²² For example, a single oral dose of 5 mg of pyridostigmine inhibited red blood cell cholinesterase by about 15%, a result generally considered a safe level of inhibition.²³⁻²⁵

Clinical Evidences

Both neostigmine and pyridostigmine have been shown to be able to promote GI motility. Intravenous neostigmine has proven efficacy in adult and pediatric acute colonic pseudo-obstruction.^{5,6} A recent meta-analysis of 4 studies evaluating 127 patients showed that neostigmine (intravenous dose range 2 mg to 5 mg) is a safe and effective option for patients with acute colonic pseudo-obstruction who failed to respond to conservative management.⁵ In children with hematologic malignancies and acute colonic pseudo-obstruction neostigmine 0.01 mg/kg (maximum 0.5 mg/kg) twice daily for a maximum of 5 total doses has been successfully used without side effects.⁷

Pyridostigmine, an oral, long-acting, and reversible CI, has

been used with success in both CIPO and PIPO, as indicated by at least 5 studies so far published (Table). O'Dea et al⁸ reported 7 adult patients with CIPO who failed standard therapies. Five of these patients had post-surgical CIPO, 1 had post-pneumonia CIPO and 1 had a mitochondrial disorder (mitochondrial encephalopathy, lactic acidosis, and stroke-like episodes syndrome)-related CIPO. In these study populations the administration of 10 mg bid pyridostigmine, then increased to a maximum of 30 mg bid (in 4 patients), evoked a good clinical response in all patients consisting of a decreased abdominal pain and discomfort with reduction of laxative use. None of the 7 patients experienced side effects. Two of these patients underwent later surgery (1 total colectomy and 1 small bowel resection) for recurrent symptoms. Pyridostigmine was discontinued in 1 patient after initial response due to recurrence of symptoms.

In the pediatric setting, Boybeyi et al⁹ first reported a positive outcome by pyridostigmine in a 3-year old child with a history of abdominal distension since the very first days of his life. This young patient was admitted at the age of 6 months with vomiting, abdominal distension, and eating difficulties. Imaging studies revealed microcolon and a megacystis without urinary reflux (likely a case of megacystis microcolon intestinal hypoperistalsis syndrome). Histopathologic examination of surgical specimens did not reveal any neuromuscular abnormalities. The child, treated with pyridostigmine at an initial dose of 30 mg/kg/day, reported a good clinical response as indicated by discontinuation of nasogastric tube decompression and, after few days of treatment, by resuming oral feeding associated with oral laxative-evoked bowel movements.⁹ In another study Manini and Colleagues described an 18-year-old male with an history of chronic constipation and gastroesophageal reflux. At the age of 13 he developed abdominal distension, bilious emesis, decrease of food intake, and weight loss. He underwent an hemicolectomy for a mid-gut volvulus, but after that he became totally dependent on parenteral nutrition with subsequent repeated subocclusive episodes. When pyridostigmine 0.25 mg/kg bid was administered (and further increased up to 0.3 mg/kg/day over the next 2 years) the patient resumed oral feeding (ie, 2-3 small meals daily), had minimal abdominal distention and reduced parenteral nutrition to about 70% of daily caloric need.¹⁰ In the 2018, Choudhury et al¹¹ described a case of a 9-year old girl with myotonic dystrophy and CIPO successfully treated by pyridostigmine. She had a long-term history of constipation and intermittent abdominal distension treated with many types of laxatives without success. Over time (within 6 months), she presented with recurrent symptoms characterized by acute abdominal distention, colicky abdominal

Table. Summary of Published Studies Evaluating the Effects of Pyridostigmine in Chronic Intestinal Pseudo-obstruction and Pediatric Intestinal Pseudo-obstruction Patients

Author	Patients number (age)	Presenting symptoms	CIPO/PIPO subtypes	Pyridostigmine dose	Outcome	Side effects
O'Dea et al, ⁸ 2010	7 (adults)	Severe bowel distension	5 Post-surgical 1 Post pneumonia 1 MELAS syndrome	10 mg bid, then increased to 30 mg bid	All had resolution of abdominal distension and reduced laxative dose Two had surgery later for symptom recurrence	None
Manini et al, ¹⁰ 2017	1 (18 yr)	Abdominal distension; intolerance to enteral feeding; bilious emesis	Neuropathic	0.25 mg/kg/day in 2 doses, increased up to 0.3 mg/kg/day over the next 2 yr	Decreased abdominal distension Increased oral intake Decreased PN	None
Boybeyi et al, ⁹ 2009	1 (3 yr)	Abdominal distension; intolerance to oral feeding; constipation	Neuropathic	30 mg/kg/day	Resolution of abdominal distension Improved oral intake	None
Choudhury et al, ¹¹ 2018	1 (9 yr)	Abdominal distension and pain; vomiting and constipation.	Myopathic	0.5 mg/kg bid and increased to 1 mg/kg bid	Increased bowel movements Reduction of abdominal distension and gastric drainage	None
Lee et al, ¹² 2019	2 (11 and 5 yr, respectively)	Congenital myotonic dystrophy Small bowel and colonic distension; megacystis	Myopathic (ACTG2 mutations)	180 mg/day; 7 mg/kg/day	Tolerance of enteral feeding Reduction in length of hospital stay and need of parenteral nutrition	None

CIPO, chronic intestinal pseudo-obstruction; PIPO, pediatric intestinal pseudo-obstruction; MELAS syndrome, mitochondrial encephalopathy, lactic acidosis, and stroke-like episodes syndrome; ACTG2, actin gamma-2 gene; bid, twice a day; PN, parenteral nutrition.

pain, worsening of constipation, and vomiting. Following exclusion of possible mechanical causes of obstruction, a diagnosis of CIPO was formulated. The patient was treated with gastric drainage and oral pyridostigmine started at a dose of 0.5 mg/kg bid and gradually increased to 1 mg/kg bid with accurate monitoring of her heart rate. She had a good clinical response in terms of reduced abdominal distension and gastric drainage, and managed to tolerate increasing amounts of enteral feeding. After discharge from the hospital, the patient maintained normal oral feeding accompanied by weight gain over a period of 7 months. Because of another mild episode of abdominal distension and vomiting, which resolved spontaneously in 48 hours, the dose of pyridostigmine was increased to 1.5 mg/kg twice per day. In a 12-month period of close follow-up the patient showed a stable body weight and a long minimally symptomatic (or virtually asymptomatic) phase.¹¹

Lee et al¹² recently described the use of pyridostigmine in 2 PIPO patients, an 11-year old girl with major small bowel involvement and a 5-year old girl with altered colonic (but no evidence of microcolon) function with congenital megacystis. Both patients had visceral myopathy with actin gamma-2 gene mutations. After 10 days of intravenous neostigmine (0.5 mg in 50 mL normal saline) at 0.5 mg per hour, the treatment was switched to oral pyridostigmine at a dose of 180 mg/day (case 1) and 7 mg/kg/day (case 2) without side effects, reduced hospital length of stay, and need for parenteral nutrition support.¹²

Based on these studies, one may conclude that an effective dose of pyridostigmine in PIPO should range between 0.25 and 7 mg/kg/day divided into 2 or 3 doses.⁹⁻¹² In clinical practice, patients with chronic gut dysmotility problems should be treated starting with low doses followed by a progressive increase of pyridostigmine, whereas in patients with acute gut dysmotility pyridostigmine should be started at high doses tapered down to the minimal effective dose.¹⁰ Data on long-term duration therapy are not available; in our case we have used pyridostigmine for 6 months with persistent beneficial clinical effects.

Pyridostigmine is usually well tolerated and no major side effects have been described in 13 patients (7 adults and 6 pediatric) with CIPO or PIPO described in the literatures. Nonetheless, although in other non-GI indications (such as myasthenia gravis), pyridostigmine may cause increased salivation, nausea, vomiting, and diarrhea. Also abdominal cramps have been reported and are thought to be due to powerful intestinal contractions induced by the drug, particularly if in the presence of adhesions obstructing the gut lumen. Other side effects include muscle weakness, fasciculations and cramps, miosis, increased urinary frequency, and increased

bronchial secretion.¹⁵ The risk of side effects increases with the increase of the dose. Therefore, pyridostigmine is contraindicated in mechanical intestinal or urinary obstruction, bradycardia, and particular caution should be used in patients with bronchial asthma.

In conclusion, we herein describe the youngest child with severe gut dysmotility, ie, PIPO, successfully treated with pyridostigmine. In line with the available literature, our report suggests that pyridostigmine is a safe and effective, orally administrable, and therapeutic option also in fragile patients with few years of life suffering from severe gut dysmotility.

Financial support: None.

Conflicts of interest: None.

Author contributions: Giovanni Di Nardo, Roberto De Giorgio, Vincenzo Stanghellini, and Girolamo Calò conceived and designed the study, drafted the initial manuscript, and approved the final manuscript as submitted; Francesco Esposito contributed to study design, revised the manuscript, performed radiological examinations, and approved the final manuscript as submitted; and Federica Viscogliosi, Maria Pia Villa, Pasquale Parisi, and Alessia Morlando enrolled and followed-up the patient and approved the final manuscript as submitted.

References

1. Di Nardo G, Di Lorenzo C, Lauro A, et al. Chronic intestinal pseudo-obstruction in children and adults: diagnosis and therapeutic options. *Neurogastroenterol Motil* Published Online First: 29 sep 2016. doi: 10.1111/nmo.12945.
2. Thapar N, Saliakellis E, Benninga MA, et al. Paediatric intestinal pseudo-obstruction: evidence and consensus-based recommendations from an ESPGHAN-led expert group. *J Pediatr Gastroenterol Nutr* 2018;66:991-1019.
3. Law NM, Bharucha AE, Undale AS, Zinsmeister AR. Cholinergic stimulation enhances colonic motor activity, transit, and sensation in humans. *Am J Physiol Gastrointest Liver Physiol* 2001;281:G1228-G1237.
4. Chaudhary NA, Truelove SC. Human colonic motility: a comparative study of normal subjects, patients with ulcerative colitis, and patients with the irritable colon syndrome. II. The effect of prostigmin. *Gastroenterology* 1961;40:18-26.
5. Valle RG, Godoy FL. Neostigmine for acute colonic pseudo-obstruction: a meta-analysis. *Ann Med Surg (Lond)* 2014;19;3:60-64.
6. Gmora S, Poenaru D, Tsai E. Neostigmine for the treatment of pediatric acute colonic pseudo-obstruction. *J Pediatr Surg* 2002;37:E28.
7. Lee JW, Bang KW, Jang PS, et al. Neostigmine for the treatment of acute

- colonic pseudo-obstruction (ACPO) in pediatric hematologic malignancies. *Korean J Hematol* 2010;45:62-65.
8. O'Dea CJ, Brookes JH, Wattchow DA. The efficacy of treatment of patients with severe constipation or recurrent pseudo-obstruction with pyridostigmine. *Colorectal Dis* 2010;12:540-548.
 9. Boybeyi O, Ciftçi AO, Topaloğlu H. An unusual presentation of gastrointestinal obstruction in a three-year-old boy. *Turk J Pediatr* 2009;51:195-198.
 10. Manini ML, Camilleri M, Grothe R, Di Lorenzo C. Application of pyridostigmine in pediatric gastrointestinal motility disorders: a case series. *Paediatr Drugs* 2018;20:173-180.
 11. Choudhury A, Rahyead A, Kammermeier J, Mutalib M. The use of pyridostigmine in a child with chronic intestinal pseudo-obstruction. *Pediatrics* 2018;141(suppl 5):S404-S407.
 12. Lee H, Park S, Oh JT, Kim HM, Kim S, Lee JS. Oral pyridostigmine-responsive visceral myopathy with *ACTG2* mutations: a case series. *J Pediatr Gastroenterol Nutr* 2019;68:e16-e17.
 13. Stanghellini V, Cogliandro RF, De Giorgio R, et al. Natural history of chronic idiopathic intestinal pseudo-obstruction in adults: a single center study. *Clin Gastroenterol Hepatol* 2005;3:449-458.
 14. Joly F, Baxter J, Staun M, et al. Five-year survival and causes of death in patients on home parenteral nutrition for severe chronic and benign intestinal failure. *Clin Nutr* 2018;37:1415-1422.
 15. Maggi L, Mantegazza R. Treatment of myasthenia gravis: focus on pyridostigmine. *Clin Drug Investig* 2011;31:691-701.
 16. Pavlovsky L, Browne RO, Friedman A. Pyridostigmine enhances glutamatergic transmission in hippocampal CA1 neurons. *Exp Neurol* 2003;179:181-187.
 17. Aquilonius SM, Hartvig P. Clinical pharmacokinetics of cholinesterase inhibitors. *Clin Pharmacokinet* 1986;11:236-249.
 18. Aquilonius SM, Eckernäs SA, Hartvig P, Hultman J, Lindström B, Osterman PO. A pharmacokinetic study of neostigmine in man using gas chromatography-mass spectrometry. *Eur J Clin Pharmacol* 1979;15:367-371.
 19. Rogers SL, Friedhoff LT. Pharmacokinetic and pharmacodynamic profile of donepezil HCl following single oral doses. *Br J Clin Pharmacol* 1998;46(suppl 1):1-6.
 20. Henze T. [Therapy of myasthenia gravis with cholinesterase inhibitors-principles and pharmacologic monitoring.] *Fortschr Neurol Psychiatr* 1996;64:110-121. [German]
 21. Sramek JJ, Cutler NR. RBC cholinesterase inhibition: a useful surrogate marker for cholinesterase inhibitor activity in Alzheimer disease therapy? *Alzheimer Dis Assoc Disord* 2000;14:216-227.
 22. Barber HE, Calvey TN, Muir KT. The relationship between the pharmacokinetics, cholinesterase inhibition and facilitation of twitch tension of the quaternary ammonium anticholinesterase drugs, neostigmine, pyridostigmine, edrophonium and 3-hydroxyphenyltrimethylammonium. *Br J Pharmacol* 1979;66:525-530.
 23. Kluwe WM, Page JG, Toft JD, Ridder WE, Chung H. Pharmacological and toxicological evaluation of orally administered pyridostigmine in dogs. *Fundam Appl Toxicol* 1990;14:40-53.
 24. Marino MT, Schuster BG, Brueckner RP, Lin E, Kaminskis A, Lassetter KC. Population pharmacokinetics and pharmacodynamics of pyridostigmine bromide for prophylaxis against nerve agents in humans. *J Clin Pharmacol* 1998;38:227-235.
 25. Stephenson LA, Kolka MA. Acetylcholinesterase inhibitor, pyridostigmine bromide, reduces skin blood flow in humans. *Am J Physiol* 1990;258(4 Pt 2):R951-R957.