

Title	The atypical social brain network in autism: Advances in structural and functional MRI studies
Author(s)	Sato, Wataru; Uono, Shota
Citation	Current Opinion in Neurology (2019), 32(4): 617-621
Issue Date	2019-08-01
URL	http://hdl.handle.net/2433/244291
Right	© 2019 Wolters Kluwer Health, Inc. All rights reserved. This is a non-final version of an article published in final form in Sato W. and Uono S. The atypical social brain network in autism: Advances in structural and functional MRI studies. Current Opinion in Neurology 2019 32(4): 617-621.; The full-text file will be made open to the public on 1 August 2020 in accordance with publisher's 'Terms and Conditions for Self-Archiving'.; This is not the published version. Please cite only the published version. この論文は出版社版ではありません。引用の際には出版社版をご確認ご利用ください。
Type	Journal Article
Textversion	author

The atypical social brain network in autism: advances in structural and functional MRI studies

Wataru Sato^{a,†} and Shota Uono^{b,†}

^a Kokoro Research Center, Kyoto University, Japan. ^b Department of Neurodevelopmental Psychiatry, Kyoto University, Japan. [†] Equal contributors.

Correspondence: Wataru Sato, Kokoro Research Center, Kyoto University, Inuyama, 46 Shimoadachi, Sakyo, Kyoto 606-8501, Japan. Email: sato.wataru.4v@kyoto-u.ac.jp

Abstract

Purpose of review

To review advances in structural and functional MRI studies regarding the neural underpinnings of social atypicalities in autism spectrum disorder (ASD).

Recent findings

According to the hypothesis that the social brain network, which includes brain regions, such as the amygdala and superior temporal sulcus, may be atypical in ASD, recent structural MRI studies have identified regional gray matter volume abnormalities in the social brain regions in ASD groups compared with the typically developing groups. Studies evaluating gray matter volume covariance and white matter volume/integrity suggested network-level abnormalities associated with the social brain regions. Recent functional MRI studies assessing resting-state neural activity showed reduced functional connectivity among the social brain regions in individuals with ASD compared with typically developing groups. Similarly, taskbased functional MRI studies recently revealed a reduction in regional activity and intraregional functional coupling in the social brain regions during the processing of social stimuli in individuals with ASD.

Summary

These structural and functional MRI studies provide supportive evidence for the hypothesis that an atypical social brain network underlies behavioral social problems in ASD.

Keywords

autism spectrum disorder, default mode network, functional connectivity, gray matter volume, social brain network

Key points

- Structural MRI studies have indicated atypical structures of gray and white matter in the social brain network in individuals with ASD.
- Resting-state functional MRI studies have revealed abnormalities in intrinsic activity and connectivity in the social brain regions in individuals with ASD.

- Task-based functional MRI studies have also reported atypical activity and connectivity in the social brain regions while processing social stimuli in individuals with ASD.

Introduction

Autism spectrum disorder (ASD) is a neurodevelopmental disorder characterized by atypicalities in social interaction [1]. Evident features of social atypicalities in ASD include difficulties in perceiving and/or recognizing the faces, emotional facial expressions [2], eyes [3], actions [4], and mental states [5] of other individuals.

Although the neural mechanisms of behavioral social problems in ASD remain elusive, one influential hypothesis is that atypicalities in the structures and/or functions of the social brain network underlie social malfunctioning in individuals with ASD. The idea of social brain regions was proposed to classify brain regions that are specifically associated with the processing of social stimuli [6]. Substantial neuroimaging and neuropsychological evidence in typically developing (TD) individuals supports the existence of such social brain regions, and suggests that they constitute networks. For example, the inferior occipital gyrus (IOG), fusiform gyrus (FG), and superior temporal sulcus (STS; the functional STS region including adjacent middle and superior temporal sulci) are involved in the processing of basic components, invariant aspects, and changeable aspects of faces, respectively [7,8]. The amygdala and ventromedial prefrontal cortex (vmPFC) are involved in processing the emotional significance of social stimuli [9]. The inferior frontal gyrus (IFG) is associated with the understanding of, and/or resonance with, the actions of others, and constitutes a functional network together with the STS and inferior parietal lobule (IPL) [10]. Some brain regions, such as the dorsomedial prefrontal cortex (dmPFC) and posterior cingulate cortex (PCC)/precuneus, collectively termed the default mode network, are typically active during resting states, but also during social cognition, such as mentalizing (i.e., inferring others' mental states) [11]. Based on these findings, together with fragmentary evidence showing structural and/or functional atypicalities in these regions in individuals with ASD, researchers have hypothesized such atypicalities in the social brain network may underlie behavioral social problems in ASD [12–15]. A number of previous structural and functional magnetic resonance imaging (MRI) studies provided support for this proposition, although the findings are not entirely consistent (for reviews, see [16–18]).

Recent structural and functional MRI studies have accumulated supportive evidence for the atypical social brain network hypothesis of ASD, and have also extended this idea. In this article, we briefly review these advances.

Structural MRI studies

Structural MRI studies have long been employed in efforts to identify a structural biomarker of ASD, and several of those studies have reported atypical gray matter volume in social brain regions among individuals with ASD (for a review, see [17]). As an example of recent studies, a multi-site MRI study with a large number of participants (> 1,500 each in ASD and TD groups) ranging from toddlers to older adults found decreased gray matter volume in the amygdala in individuals with ASD [19].

Some recent studies have revealed that gray matter volume abnormalities in social brain regions are associated with social malfunctioning in ASD. For example, Sato et al. [20] reported that the gray matter volume of the STS was positively associated with the ability to mentalize based on others' eyes in TD individuals but not in ASD individuals. Pereira et al. [21] showed that gray matter volume and cortical thickness in individuals with ASD were reduced in distributed brain regions, including the FG, STS, and amygdala, and that reduced cortical thickness in the IFG was associated with the severity of social impairment.

Recent studies have further suggested network-level atypicalities in the gray matter volume of social brain regions in individuals with ASD. For example, Sato et al. [22] applied a multivariate analysis (i.e., partial least squares analysis) to evaluate correlated gray matter voxels to discriminate ASD from TD individuals; The widespread sets of correlated voxels covering certain social brain regions, such as the IOG, FG, STS, amygdala, vmPFC, IFG, and dmPFC, showed reduced gray matter volume in the ASD group (Figure 1). Pappaianni et al. [23] performed a different multivariate analysis (i.e., independent component analysis) and revealed that a widespread network, including the FG, STS, and IPL, differentiated ASD from TD groups.

Consistent with the idea of network-level problems underlying ASD, several recent structural MRI studies have analyzed white matter volume or integrity and have reported that individuals with ASD have atypical white matter structure around the social brain regions. Some studies have also showed a correspondence between these structural atypicalities and behavioral social problems. For example, Lo et al. [24] found that tract integrity in the superior longitudinal fasciculus, which connects the STS and IFG, was reduced in individuals with ASD compared with TD controls; moreover, the decreased values in the ASD group were associated with impairments in social interaction, as measured by a self-reported questionnaire. d'Albis et al. [25] revealed that individuals with ASD showed reduced connectivity in widespread white matter in the frontal, parietal, and temporal regions, including around the STS and vmPFC, which was associated with difficulties related to social awareness and empathy. Gibbard et al. [26] reported that decreased integrity of white matter

tracts between the amygdala and neocortical regions in individuals with ASD was associated with difficulty in the ability to mentalize based on others' eyes.

In summary, the findings of these structural MRI studies indicate that atypical structures of gray and white matter in the social brain network are associated with behavioral social malfunctioning in individuals with ASD.

Functional MRI studies: resting-state

Numerous functional MRI studies have measured resting-state neural activity in individuals with ASD. Previous studies provided rather convergent findings, indicating that resting-state functional connectivity between the dmPFC and PCC/precuneus within the default mode network is reduced in individuals (specifically, adults) with ASD (e.g., [27]; for a review, see [28]). Several recent studies investigating resting-state functional connectivity confirmed this finding (e.g., [21]).

Recent studies have further revealed that social brain regions outside the default mode network also show reduced activity and functional connectivity during resting states in individuals with ASD. For example, Odriozola et al. [29] selected the amygdala as the region of interest and found that individuals with ASD, compared with TD individuals, showed weaker functional connectivity between the amygdala and vmPFC during resting state, which was further associated with the severity of social affective impairment. Fishman et al. [30] also analyzed resting-state amygdala functional connectivity and found reduced functional connectivity between the amygdala and IOG in an ASD group compared with a TD group. Jung et al. [31] revealed that resting-state activity of the IOG was reduced in an ASD group compared with a TD group; moreover, the degree of reduction was associated with symptom severity.

In summary, consistent with structural MRI studies, these resting-state functional MRI studies suggest that abnormalities in intrinsic activity and connectivity in the social brain regions are implicated in the social difficulties observed in individuals with ASD.

Functional MRI studies: task

A number of previous task-based functional MRI studies have reported atypical (usually reduced) activity in social brain regions in individuals with ASD during the processing of social stimuli, such as emotional facial expressions and eyes (e.g., [32]; for a review, see [18]). Recent studies further investigated detailed computational profiles of social brain activity in ASD. For example, Ciaramidaro et al. [33] measured brain activity during implicit and explicit processing of facial expressions (i.e., gender and emotion recognition, respectively) in

ASD and TD groups. Implicit, but not explicit, processing of emotional facial expressions was associated with reduced activity in several social brain regions, including the amygdala, FG, and STS, in the ASD group compared with the TD group. Sato et al. [34] measured brain activity and assessed behavioral performance in a cueing paradigm in response to subliminally and supraliminally presented averted eye gaze stimuli in ASD and TD groups. Behaviorally, the subliminally presented averted eyes elicited attentional shift in the TD, but not in the ASD, group; neurally, these stimuli evoked reduced activation in the amygdala in the ASD group compared with the TD group. These studies extend previous findings of atypical activity of the social brain regions in ASD by indicating that atypical activation can occur at automatic and unconscious stages during the processing of social stimuli in individuals with ASD.

In addition, a few recent studies have shown both weak activity in social brain regions in individuals with ASD and the possibility of improvement through training. Specifically, Yang et al. [35] asked individuals with ASD to participate in a 5-week social skills training course using virtual reality, and measured brain activity in response to biological motion stimuli before and after training using functional MRI. The activity changes in the STS showed a positive correlation with improved mentalizing scores after training. Datko et al. [36] tested the effect of at least 20 hours of training on the control of electroencephalographic activity associated with the observation and execution of actions in ASD and TD groups. After the training, individuals with ASD and TD individuals showed comparable activity in several social brain regions, including the IFG, during the observation and imitation of others' hand actions, although before training, the activity was weaker in the ASD than in the TD group.

Several previous task-based functional MRI studies have also showed that the atypical activity of some social brain regions represents functional networks during the processing of social stimuli in individuals with ASD (e.g., STS–IFG connectivity during emotional expression processing [37]). Recent studies further revealed that the widespread social brain regions constitute functional networks and are associated with social atypicalities in ASD. For example, Cole et al. [38] analyzed functional connectivity during mentalizing or non-mentalizing tasks in response to others' actions in ASD and TD groups. Functional coupling between dmPFC activity and the average activity of the IFG and IPL was stronger during mentalizing versus non-mentalizing tasks in the TD group, but not in the ASD group. Moreover, the degree of this functional connectivity was negatively associated with the severity of ASD symptoms. Lynn et al. [39] analyzed functional connectivity while ASD and TD groups encoded and decoded images of faces and cars. Functional connections between the FG and several other regions, including the dmPFC and IPL, were reduced during the

processing of faces in the ASD group compared with the TD group.

In summary, findings from task-based functional MRI studies also suggest that atypical activity and connectivity in the social brain regions while processing social stimuli are associated with behavioral social problems in individuals with ASD.

Conclusion

These recent structural and functional MRI studies have accumulated supportive evidence for the hypothesis that atypical social brain networks underlie behavioral social problems seen in ASD. Specifically, findings from these studies confirmed that gray matter volume and activation in the social brain regions are atypical, usually reduced, in individuals with ASD. Furthermore, the findings revealed the structural and functional networking patterns among the social brain regions associated with behavioral social problems in ASD.

However, it must be noted that other studies have suggested that regions other than those mentioned above may also be involved in atypical social functioning in individuals with ASD. For example, a recent functional MRI study has revealed atypical activity in the basal ganglia during the processing of social rewards in individuals with ASD [40]. The concept of the social brain network may be spatially extended in future research.

In addition, it should be noted that some studies have reported inconsistent findings regarding structural or functional atypicalities in the social brain network in individuals with ASD (for a review, see [16, 18]). This may be at least partially explained by the heterogeneity of the behavioral social problems associated with ASD. Decomposing the behavioral social problems of ASD (e.g., examining specific stages in the processing of emotional facial expressions) partialing out the effects of comorbidities (e.g., language impairments and heightened anxiety) may be useful for further exploration of the neural underpinnings of behavioral social problems in ASD.

Acknowledgements

None.

Financial support and sponsorship

This study was supported by funds from Research Complex Program from Japan Science and Technology Agency (JST) and JST CREST (JPMJCR17A5).

Conflict of interest

The authors have no conflict of interest.

References

1. American Psychiatric Association. Diagnostic and statistical manual of mental disorders (5th ed.). Arlington, VA: American Psychiatric Publishing; 2013.
2. Hobson RP. Autism and the development of mind. Hove, UK: Lawrence Erlbaum Associates; 1993.
3. Mundy P, Sigman M, Kasari C. The theory of mind and joint-attention deficits in autism. In Understanding other minds: Perspectives from autism. Edited by Baron-Cohen S, Tager-Flusberg H. New York, NY: Oxford University Press; 1994: 181–203.
4. Williams JH, Whiten A, Singh T. A systematic review of action imitation in autistic spectrum disorder. *J Autism Dev Disord* 2004 34: 285–299.
5. Baron-Cohen S. Mindblindness: An essay on autism and theory of mind. Cambridge, MA: MIT Press; 1995.
6. Brothers L. The social brain: A project for integrating primate behavior and neurophysiology in a new domain. *Concepts Neurosci* 1990 1: 27–51.
7. Haxby JV, Hoffman EA, Gobbini MI. The distributed human neural system for face perception. *Trends Cogn Sci* 2000 4: 223–233.
8. Allison T, Puce A, McCarthy G. Social perception from visual cues: Role of the STS region. *Trends Cogn Sci* 2000 4: 267–278.
9. Adolphs R. Recognizing emotion from facial expressions: psychological and neurological mechanisms. *Behavioral and Cogn Neurosci Rev* 2002 1: 21–61.
10. Iacoboni M. Neural mechanisms of imitation. *Curr Opin Neurobiol* 15 632–637 2005.
11. Schilbach L, Eickhoff SB, Rotarska-Jagiela A, et al. Minds at rest? Social cognition as the default mode of cognizing and its putative relationship to the "default system" of the brain. *Conscious Cogn* 2008 17: 457–467.
12. Bachevalier J. Medial temporal lobe structures and autism: a review of clinical and experimental findings. *Neuropsychologia* 1994 32: 627–648.
13. Emery NJ. The eyes have it: the neuroethology, function and evolution of social gaze. *Neurosci Biobehav Rev* 2000 24: 581–604.
14. Williams JH, Whiten A, Suddendorf T, et al. Imitation, mirror neurons and autism. *Neurosci Biobehav Rev* 2001 25: 287–295.
15. Johnson MH, Griffin R, Csibra G, et al. The emergence of the social brain network: evidence from typical and atypical development. *Dev Psychopathol* 2005 17: 599–619.
16. Bernhardt BC, Di Martino A, Valk SL, et al. Neuroimaging-based phenotyping of the autism spectrum. *Curr Top Behav Neurosci* 2017 30: 341–355.
17. Ecker C. The neuroanatomy of autism spectrum disorder: An overview of structural neuroimaging findings and their translatability to the clinical setting. *Autism* 2017 21: 18–28.
18. Müller RA, Fishman I. Brain connectivity and neuroimaging of social networks in autism. *Trends Cogn Sci* 2018 22: 1103–1116.

- 19.** van Rooij D. Cortical and subcortical brain morphometry differences between patients with autism spectrum disorder and healthy individuals across the lifespan: Results from the ENIGMA ASD Working Group. *Am J Psychiatry* 2018 175: 359–369.
This structural MRI study investigated a large number of participants (> 1,500 each in ASD and TD groups) and found group differences in morphometry measures in several brain regions, including decreased gray matter volume in the amygdala in the ASD group.
20. Sato W, Uono S, Kochiyama T, et al. Structural correlates of reading the mind in the eyes in autism spectrum disorder. *Front Hum Neurosci* 2017 11: 361.
- 21.** Pereira AM., Campos BM, Coan AC, et al. Differences in cortical structure and functional MRI connectivity in high functioning autism. *Front Neurol* 2018 9: 539.
This study analyzed structural and resting-state functional MRI in ASD and TD groups. The ASD group showed that gray matter volume and cortical thickness in distributed brain regions, including the FG, STS, and amygdala, were reduced and that reduced cortical thickness in the IFG was associated with the severity of social impairment. The ASD group also showed decreased functional connectivity between the PCC and several frontal regions.
- 22.* Sato W, Kochiyama T, Uono S, et al.. Reduced gray matter volume in the social brain network in adults with autism spectrum disorder. *Front Hum Neurosci* 2017 11: 395.
This study applied a partial least squares analysis to structural MRI of ASD and TD groups. The results revealed that widespread sets of correlated voxels covering certain social brain regions, such as the IOG, FG, STS, amygdala, vmPFC, IFG, and dmPFC, showed reduced gray matter volume in the ASD group.
23. Pappaiani E, Siugzdaite R, Vettori S, et al. Three shades of grey: detecting brain abnormalities in children with autism using source-, voxel- and surface-based morphometry. *Eur J Neurosci* 2018 47: 690–700.
24. Lo YC, Chen YJ, Hsu YC, et al. Reduced tract integrity of the model for social communication is a neural substrate of social communication deficits in autism spectrum disorder. *J Child Psychol Psychiatry* 2017 58: 576–585.
- 25.* d’Albis MA, Guevara P, Guevara M, et al. Local structural connectivity is associated with social cognition in autism spectrum disorder. *Brain* 2018 141: 3472–3481.
This structural MRI study analyzed white matter integrity in ASD and TD groups. The ASD group showed reduced connectivity in widespread white matter in the frontal, parietal, and temporal regions, including around the STS and vmPFC, which was associated with difficulties related to social awareness and empathy.
26. Gibbard CR, Ren J, Skuse DH, et al. Structural connectivity of the amygdala in young adults with autism spectrum disorder. *Hum Brain Mapp* 2018 39: 1270–1282.
27. Cherkassky VL, Kana RK, Keller TA, et al. Functional connectivity in a baseline resting-state network in autism. *Neuroreport* 2006 17: 1687–1690.
28. Padmanabhan A, Lynch CJ, Schaer M, et al. The default mode network in autism. *Biol*

Psychiatry Cogn Neurosci Neuroimaging 2017 2: 476–486.

- 29.** Odriozola P, Dajani DR, Burrows CA, et al. Atypical frontoamygdala functional connectivity in youth with autism. *Dev Cogn Neurosci* in press.

This study analyzed resting-state functional MRI in ASD and TD groups. The ASD group showed weaker functional connectivity between the amygdala and vmPFC, which was further associated with the severity of social affective impairment.

- 30.* Fishman I, Linke AC, Hau J, et al. Atypical functional connectivity of amygdala related to reduced symptom severity in children with autism. *J Am Acad Child Adolesc Psychiatry* 2018 57: 764–774.

This study analyzed resting-state functional MRI in ASD and TD groups and found reduced functional connectivity between the amygdala and IOG in the ASD group.

- 31.* Jung M. Decreased structural connectivity and resting-state brain activity in the lateral occipital cortex is associated with social communication deficits in boys with autism spectrum disorder. *Neuroimage* in press.

This study analyzed structural and resting-state functional MRI in ASD and TD groups. The ASD group showed decreased structural connectivity in several regions. The ASD group also showed reduced resting-state activity of the IOG; moreover, the degree of reduction was associated with symptom severity.

32. Baron-Cohen S, Ring HA, Wheelwright S, et al.. Social intelligence in the normal and autistic brain: an fMRI study. *Eur J Neurosci* 1999 11: 1891–1898.

- 33.* Ciaramidaro A, Bölte S, Schlitt S, et al.. Transdiagnostic deviant facial recognition for implicit negative emotion in autism and schizophrenia. *Eur Neuropsychopharmacol* 2018 28: 64–275.

This study investigated functional MRI during implicit and explicit processing of facial expressions in ASD, schizophrenia, and TD groups. Implicit, but not explicit, processing of emotional facial expressions was associated with reduced activity in several social brain regions (e.g., the amygdala and FG) in the ASD and schizophrenia groups.

34. Sato W., Kochiyama T., Uono, S, et al. Neural mechanisms underlying conscious and unconscious gaze-triggered attentional orienting in autism spectrum disorder. *Front Hum Neurosci* 2017 11: 339.

35. Yang YJD, Allen T, Abdullahi SM, et al.. Neural mechanisms of behavioral change in young adults with high-functioning autism receiving virtual reality social cognition training: A pilot study. *Autism Res* 2018 11: 713–725.

- 36.** Datko M, Pineda JA, Müller RA Positive effects of neurofeedback on autism symptoms correlate with brain activation during imitation and observation. *Eur J Neurosci* 2018 47: 579–591.

This task-based functional MRI study tested the effect of training on the control of electroencephalographic activity associated with the observation and execution of actions in ASD and TD groups. After the training, the groups showed comparable activity in several social brain regions (e.g., the IFG) during the observation and

imitation of others' hand actions, although the activity was weaker in the ASD group before training.

37. Sato W., Toichi M., Uono S. Impaired social brain network for processing dynamic facial expressions in autism spectrum disorders. *BMC Neurosci* 2012 13: 99.
 38. Cole EJ, Barraclough NE, Andrews TJ. Reduced connectivity between mentalizing and mirror systems in autism spectrum condition. *Neuropsychologia* 2019 122: 88–97.
 - 39.* Lynn AC, Padmanabhan A, Simmonds D, et al. Functional connectivity differences in autism during face and car recognition: underconnectivity and atypical age-related changes. *Developmental Science* 2018 21: e12508.
- This task-based functional MRI study analyzed functional connectivity while ASD and TD groups encoded and decoded images of faces and cars. Functional connections between the FG and several other regions (e.g., dmPFC) were reduced during the processing of faces in the ASD group.
40. Kohls G, Antezana L, Mosner MG, et al. Altered reward system reactivity for personalized circumscribed interests in autism. *Mol Autism* 2018 9: 9.

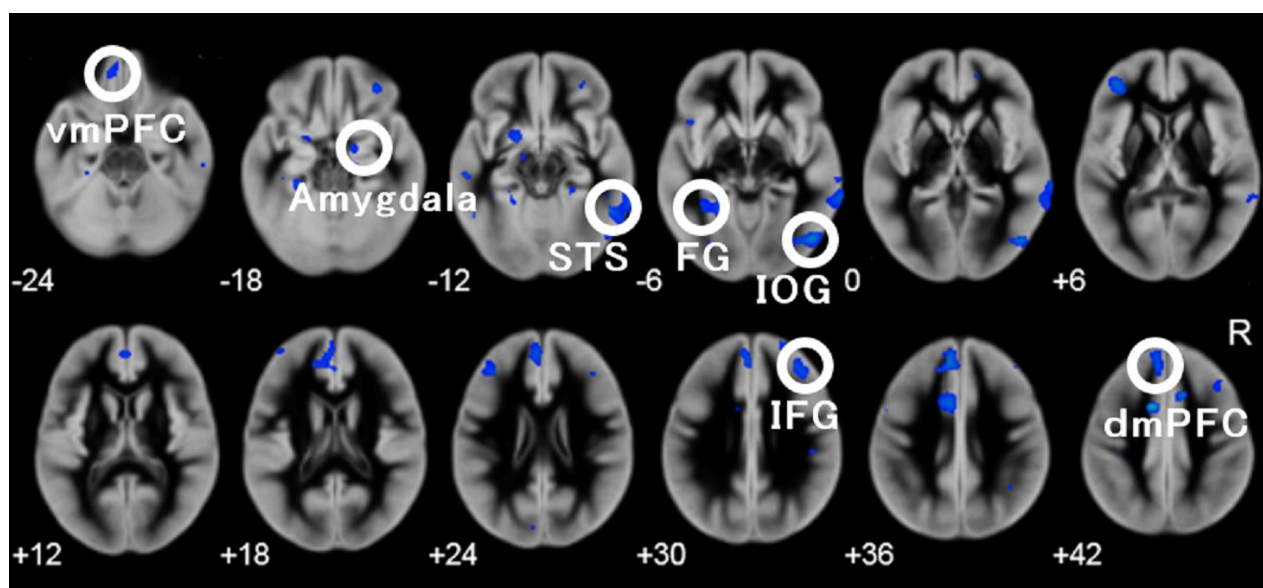


Figure 1. Correlated gray matter voxels (blue–cyan color) that significantly discriminated the autism spectrum disorder and typically developing groups and covered social brain regions (revised from Sato et al. [22]). Numbers below the slices indicate the z-axis of the Montreal Neurological Institute system coordinates. R = right hemisphere; vmPFC = ventromedial prefrontal cortex; STS = superior temporal sulcus; FG = fusiform gyrus; IOG = inferior occipital gyrus; IFG = inferior frontal gyrus; dmPFC = dorsomedial prefrontal cortex.