

# DWI for Assessment of Rectal Cancer Nodes After Chemoradiotherapy

## Citation for published version (APA):

van Heeswijk, M. M., Lambregts, D. M. J., Palm, W. M., Hendriks, B. M. F., Maas, M., Beets, G. L., & Beets-Tan, R. G. H. (2017). DWI for Assessment of Rectal Cancer Nodes After Chemoradiotherapy: Is the Absence of Nodes at DWI Proof of a Negative Nodal Status? *American Journal of Roentgenology*, 208(3), W79-W84. <https://doi.org/10.2214/AJR.16.17117>

## Document status and date:

Published: 01/03/2017

## DOI:

[10.2214/AJR.16.17117](https://doi.org/10.2214/AJR.16.17117)

## Document Version:

Publisher's PDF, also known as Version of record

## Document license:

Taverne

## Please check the document version of this publication:

- A submitted manuscript is the version of the article upon submission and before peer-review. There can be important differences between the submitted version and the official published version of record. People interested in the research are advised to contact the author for the final version of the publication, or visit the DOI to the publisher's website.
- The final author version and the galley proof are versions of the publication after peer review.
- The final published version features the final layout of the paper including the volume, issue and page numbers.

[Link to publication](#)

## General rights

Copyright and moral rights for the publications made accessible in the public portal are retained by the authors and/or other copyright owners and it is a condition of accessing publications that users recognise and abide by the legal requirements associated with these rights.

- Users may download and print one copy of any publication from the public portal for the purpose of private study or research.
- You may not further distribute the material or use it for any profit-making activity or commercial gain
- You may freely distribute the URL identifying the publication in the public portal.

If the publication is distributed under the terms of Article 25fa of the Dutch Copyright Act, indicated by the "Taverne" license above, please follow below link for the End User Agreement:

[www.umlib.nl/taverne-license](http://www.umlib.nl/taverne-license)

## Take down policy

If you believe that this document breaches copyright please contact us at:

[repository@maastrichtuniversity.nl](mailto:repository@maastrichtuniversity.nl)

providing details and we will investigate your claim.

# DWI for Assessment of Rectal Cancer Nodes After Chemoradiotherapy: Is the Absence of Nodes at DWI Proof of a Negative Nodal Status?

Miriam M. van Heeswijk<sup>1,2,3</sup>  
 Doenja M. J. Lambregts<sup>2</sup>  
 Walter M. Palm<sup>3</sup>  
 Babs M. F. Hendriks<sup>3</sup>  
 Monique Maas<sup>2,3</sup>  
 Geerard L. Beets<sup>1,4</sup>  
 Regina G. H. Beets-Tan<sup>1,2</sup>

**Keywords:** DWI, locally advanced rectal cancer, lymph node staging, nodal restaging, organ preservation

DOI:10.2214/AJR.16.17117

Received July 21, 2016; accepted after revision September 6, 2016.

Based on presentations at the 2015 European Congress of Radiology, Vienna, Austria, and the 2015 annual meeting of the European Society of Gastrointestinal and Abdominal Radiology, Paris, France.

<sup>1</sup>GROW School for Oncology and Developmental Biology, Maastricht University Medical Centre, Maastricht, The Netherlands.

<sup>2</sup>Department of Radiology, The Netherlands Cancer Institute, PO Box 90203, 1006 BE Amsterdam, The Netherlands. Address correspondence to D. M. J. Lambregts (d.lambregts@nki.nl).

<sup>3</sup>Department of Radiology, Maastricht University Medical Centre, Maastricht, The Netherlands.

<sup>4</sup>Department of Surgery, The Netherlands Cancer Institute, Amsterdam, The Netherlands.

## WEB

This is a web exclusive article.

AJR2017; 208:W79–W84

0361–803X/17/2083–W79

© American Roentgen Ray Society

**OBJECTIVE.** When considering organ preservation in patients with rectal cancer with good tumor response, assessment of a node-negative status after chemoradiation therapy (CRT) is important. DWI is a very sensitive technique to detect nodes. The study aim was to test the hypothesis that the absence of nodes at DWI after CRT is concordant with a ypN0 status.

**MATERIALS AND METHODS.** A retrospective study was performed of 90 patients with rectal cancer treated with CRT followed by restaging MRI at 1.5 T, including DWI (highest b value, 1000 s/mm<sup>2</sup>). Two independent readers counted the number of nodes visible in the mesorectal compartment on DW images obtained after CRT. The number of nodes on DWI (0 vs ≥ 1) was compared with the number of metastatic nodes at histopathology or long-term clinical follow-up (yN0 vs yN-positive status).

**RESULTS.** Seventy-one patients had a yN0 status, and 19 had a yN-positive status. For 10 patients, no nodes were observed at DWI, which was concordant with a yN0 status in 100% of cases. In the other 61 patients with a yN0 status, the median number of nodes detected at DWI was three (range, 1–17 nodes). To differentiate between yN0 and yN-positive status, sensitivity was 100%, specificity was 14%, the positive predictive value was 24%, and the negative predictive value was 100%.

**CONCLUSION.** Although the absence of nodes at DWI is not a frequent finding, it appears to be a reliable predictor of yN0 status after CRT in patients with rectal cancer. DWI may thus be a helpful adjunct in assessing response after CRT and may help select patients for organ-saving treatment.

**M**RI is part of the standard workup for patients with rectal cancer. MRI is increasingly being adopted for the restaging of disease in patients with rectal cancer after neoadjuvant chemoradiation therapy (CRT). Restaging MRI is valuable to evaluate the response of a locally advanced tumor to CRT and to determine whether the extent of the surgical resection can be decreased in case of significant tumor regression. Furthermore, in case of a very good or complete tumor response, patients may be considered for organ-preserving treatment options (although presently mainly in trial settings), such as a local excision (e.g., transanal endoscopic microsurgery) or a watchful waiting policy [1–4]. If organ preservation is considered, it is crucial to accurately select the nearly complete responders. A combination of MRI including DWI together with endoscopy and biopsy offers the best results to determine whether a tumor remnant remains present within the

bowel wall [5]. The assessment of the response of the lymph nodes mainly relies on imaging. With organ preservation, one needs to ensure that there is no residual nodal disease because this induces a risk for a nodal recurrence [6, 7]. It is known that standard morphologic MRI is of limited use for assessing lymph nodes [8, 9], although more favorable results have been suggested for restaging of nodes after CRT compared with results for primary nodal staging [8–11]. Sensitivities reported for the detection of nodal disease after CRT range between 42% and 89% [12–15]. Particularly in patients with a good tumor response (ypT0–2) who may be considered for organ preservation, low sensitivities of around 40% have been reported [15], probably because, in these cases, residual disease typically occurs within very small nodes that are difficult to evaluate with imaging. This still limits the clinical utility of imaging for the prediction of the pathologic nodal status after CRT.

**TABLE 1: Sequence Parameters for the T2- and T1-Weighted and DWI Sequences**

| Parameter                    | T2-Weighted Fast Spin-Echo | 3D T1-Weighted Gradient-Recalled Echo | DWI Sequence 1 (n = 56)           | DWI Sequence 2 (n = 17)                        | DWI Sequence 3 (n = 22)                   |
|------------------------------|----------------------------|---------------------------------------|-----------------------------------|--|---|
| TR/TE                        | 8456–9558/130–150          | 9.8/4.6                               | 4808–4829/70                      | 4971/70  | 4172–5241/68–70                           |
| No. of slices                | 22–33                      | 200                                   | 50                                | 24   | 20–24                                     |
| Slice thickness (mm)         | 2                          | 1                                     | 5                                 | 5  | 5   |
| Slice gap (mm)               | 2                          | NA                                    | 0.5                               | 0.5  | 0.5                                       |
| In-plane resolution (mm)     | 0.78 × 1.14                | 1.15 × 1.15                           | 2.50 × 3.11–3.18                  | 1.82 × 2.31                                    | 1.82 × 2.27                               |
| Echo-train length            | 25                         | 1                                     | 1                                 | 1  | 1   |
| No. of signal averages       | 2–6                        | 1                                     | 4                                 | 5  | 5   |
| b Value (s/mm <sup>2</sup> ) | NA                         | NA                                    | 0, (100) <sup>a</sup> , 500, 1000 | 0, 500, 1000                                   | 0, (25, 50, 100) <sup>a</sup> , 500, 1000 |
| Fat-suppression technique    | NA                         | NA                                    | STIR                              | Spectral presaturation with inversion recovery | Spectral attenuated inversion recovery    |
| Echo-planar imaging factor   | NA                         | NA                                    | 53–55                             | 55   | 61  |

Note—DWI sequence 1 was used from the start of the study through November 2011, DWI sequence 2 was used from December 2011 through June 2012, and DWI sequence 3 was used from July 2012 through the end of the study. NA = not applicable.

<sup>a</sup>Values in parentheses were used for only a subset of patients.

In recent years, DWI has proven its value and is now recommended as a routine addition to the MRI protocol for the assessment of rectal cancer, particularly in the restaging setting [16–20]. DWI highlights tissues with a dense cellular structure, making it a very suitable technique to detect malignant tumors but also to detect lymph nodes, because lymphoid tissue has an intrinsically high cellular density [21–25]. With this in mind, DWI should also be well equipped to detect the typically small nodes that remain after CRT, as has also been suggested by a previous report showing that, in the restaging setting, DWI detects 26% more nodes than does standard T2-weighted MRI [22]. One could even argue that, given the high sensitivity of DWI to detect nodes, the absence of visible lymph nodes on DW images after CRT should indicate that no metastatic lymph nodes remain. If we can confirm this hypothesis, DWI could be valuable as a tool to help select node-negative patients after CRT. The aim of this study therefore was to evaluate whether the absence of nodes at DWI can be used to establish a valid diagnosis of a yN0 status in patients with rectal cancer after neoadjuvant treatment.

## Materials and Methods

### Patients

This study retrospectively assessed 130 consecutive patients who received a diagnosis of locally advanced rectal cancer and were treated with a long course of neoadjuvant CRT between November 2009 and May 2013 at Maastricht University Medical Centre (Maastricht,

The Netherlands). The study meets the guidelines of our country's responsible governmental agency; because of the retrospective nature of the study, informed consent was not required. Inclusion criteria were biopsy-proven rectal adenocarcinoma, long course of neoadjuvant treatment, availability of a restaging MRI examination including a DWI sequence after neoadjuvant treatment, and availability of histopathologic findings after surgery or a sustained yN0 status and disease-free survival (DFS) of at least 2 years after organ-preserving treatment as an endpoint for nodal response. The routine neoadjuvant treatment consisted of 50.4 Gy of radiation combined with capecitabine (2 × 825 mg/m<sup>2</sup>/day). Four patients underwent 5 × 5 Gy of radiation combined with rapamycin and a long (8–10 week) waiting interval before restaging and surgery. Forty patients were excluded for the following reasons: a prolonged interval (> 50 days) between restaging MRI and surgery (because histopathologic findings in this setting will no longer be representative for the MRI findings; n = 24), missing data (e.g., missing histopathology reports; n = 13), or DFS of less than 2 years after organ-preserving treatment (n = 3). This left a total study population of 90 patients who met all inclusion criteria. Some of the study patients were included in previous studies from our group on DWI for assessment of tumor response and on contrast-enhanced lymph node imaging. These previous studies did not focus on the use of DWI for lymph node evaluation [26, 27].

### MRI

All patients underwent primary staging and restaging MRI on a 1.5-T system (Intera Achieva

or Ingenia, both from Philips Healthcare). The standard protocol included 2D T2-weighted fast spin-echo sequences in three orthogonal directions (with the transverse images angled perpendicular and the coronal images angled parallel to the tumor axis as identified on the sagittal scan) and a transverse 3D T1-weighted gradient-echo sequence with 1-mm isotropic voxels. This protocol was chosen according to the findings of previous studies on lymph node evaluation [27, 28]. The DWI sequence was a transverse echo-planar imaging diffusion sequence with 1000 s/mm<sup>2</sup> as the highest b value, angled in the same plane as the transverse T2-weighted and T1-weighted sequences. All imaging sequences covered the full mesorectal compartment. Detailed sequence parameters are provided in Table 1.

### Image Evaluation

MRI examinations were evaluated by two independent readers with 6 and 3 years of specific experience in reading pelvic MR images. The two readers evaluated the restaging high-b-value (1000 s/mm<sup>2</sup>) DW images and counted the number of visible lymph nodes within the mesorectal compartment (Fig. 1). A lymph node on DW images was defined as a round or oval structure showing high signal intensity compared with the suppressed background signal of the mesorectal fat. The anatomic T2-weighted and T1-weighted sequences, as well as the primary staging MRI examinations, were at the reader's disposal for anatomic correlation and to confirm high-signal structures as lymph nodes. The final nodal count on DWI was classified as no visible nodes or one or more visible nodes. The readers were blinded to all other patient data, including histopathologic

DWI Assessment of Rectal Cancer Nodes After CRT

TABLE 2: Demographic and Clinical Characteristics of 90 Patients With Rectal Cancer

| Characteristic   | Value       |                     |
|--|-------------|---------------------|
| Sex, no. (%) of patients   |             |                     |
| Male   | 60 (67)     |                     |
| Female   | 30 (33)     |                     |
| Age (y), median (range)  | 65 (32–81)  |                     |
| yN category, no. (%) of patients   |             |                     |
| N0   | 71 (79)     |                     |
| N-positive   | 19 (21)     |                     |
| N1   | 15 (17)     |                     |
| N2   | 4 (4)       |                     |
| No. (%) of patients per yT category  | ypN0 Status | ypN-Positive Status |
| T0   | 28 (31)     | 0                   |
| T1   | 7 (8)       | 0                   |
| T2   | 13 (14)     | 3 (3)               |
| T3   | 20 (22)     | 12 (13)             |
| T4   | 3 (3)       | 4 (4)               |
| No. of nodes harvested at histopathologic examination in patients who underwent surgical resection, median (range) | 12 (0–25)   | 11 (5–26)           |
| No. of malignant nodes, median (range)   | NA          | 2 (1–5)             |
| Size of nodes at histopathologic examination (mm), median (range)  |             |                     |
| Malignant  | 6 (1–21)    |                     |
| Benign   | 3 (1–23)    |                     |

Note—NA = not applicable.

outcome, as well as to each other’s results. In case of a discrepancy in lymph node count (i.e., 0 vs ≥ 1 nodes seen at DWI) between the two observers, the readers reevaluated the images in consensus to obtain a final count.

Reference Standard

Sixty-eight patients underwent a total mesorectal excision. For these patients, histologic examination of the surgical resection specimens according to the sixth edition of the American Joint Committee on Cancer TNM staging system [29] (as advocated during the study period in our center) served as the standard of reference. The total number of nonmetastatic and metastatic lymph nodes at histopathologic examination was recorded, as well as the overall nodal category (ypN0,

ypN1, or ypN2). The remaining 22 patients underwent a local excision (n = 2) or a watchful waiting policy with intensive follow-up (n = 20). For these patients, DFS of 24 months or longer with no evidence of growing or suspicious nodes on follow-up imaging was considered a surrogate endpoint for a yN0 status. Median DFS follow-up in these patients was 61 months (range, 44–75 months).

Statistical Analysis

Statistical analyses were performed using SPSS (version 22.0, IBM). To assess interobserver agreement for the number of lymph nodes detected on DW images, the intraclass correlation coefficient was calculated with the two-way mixed method with absolute agreement for single measures. For all other analyses, the number of lymph nodes counted

on DW images was averaged between the two readers (for patients for whom an additional consensus reading was performed, the number reached after consensus reading was used). Contingency tables (2 × 2) were constructed to correlate the number of nodes detected at DWI after CRT (i.e., 0 vs ≥ 1 nodes) with histopathologic examination or follow-up. Sensitivity, specificity, and positive and negative predictive values were calculated using a yN-positive status as the positive outcome.

Results

Patient and Treatment Characteristics

Sixty patients were men and 30 were women. Seventy-one patients had a yN0 status (50 ypN0 after surgery and 21 ycN0 with a sustained ycN0 status and DFS of > 24 months). Nineteen patients had a ypN-positive status after surgery (16 ypN1 and 3 ypN2). Detailed patient characteristics are shown in Table 2. The median interval between the restaging MRI and surgery was 16 days (range, 5–50 days).

Number of Nodes at DWI to Predict yN0 Versus yN-Positive Status

For 10 of 90 patients, no nodes were observed at DWI, which was concordant with a yN0 status at histopathologic examination or follow-up in all 10 (100%) cases. In the remaining 61 patients with a yN0 status, the median number of nodes detected at DWI was three (range, 1–17 nodes). The 19 patients with a ypN-positive status had a median of four nodes (range, 1–7 nodes) detected at DWI. In patients with a ypN1 status, the median number of nodes at DWI was four (range, 1–7) versus four (range, 4–6) in patients with a ypN2 status. Diagnostic accuracy figures to discriminate yN0 versus yN-positive (with yN-positive being the positive outcome) are presented in Table 3. Sensitivity was 100%, specificity was 14%, positive predictive value was 24%, and negative predictive value was 100%.

Results per yT Category

Figure 2 shows the distribution of patients with zero or one or more nodes at DWI among different tumor response groups. Of the patients with zero nodes at DWI, four

TABLE 3: Diagnostic Performance to Diagnose ypN-Positive Versus ypN0 Status According to the Presence or Absence of Visible Nodes at DWI Performed After Chemoradiation Therapy

| Parameter                       | Sensitivity | Specificity | Positive Predictive Value | Negative Predictive Value |
|---------------------------------|-------------|-------------|---------------------------|---------------------------|
| Percentage (no. of nodes/total) | 100 (19/19) | 14 (10/71)  | 24 (19/80)                | 100 (10/10)               |
| 95% CI                          | 82–100      | 7–24        | 15–35                     | 69–100                    |

Note—In this analysis, yN-positive status is defined as the positive outcome.

had residual tumor (1 ypT2, 2 ypT3, and 1 ypT4) and six were (clinical) complete tumor responders (yT0). The percentage of patients with no nodes at DWI was highest (21%) in the yT0 group, compared with 4% in the ypT1–2 group and 8% in the ypT3–4 group. The median number of nodes detected at DWI was two (range, 0–17 nodes) in the yT0 group, three (range, 0–12 nodes) in the ypT1–2 group, and three (range, 0–9 nodes) in the ypT3–4 group. In the subgroup of patients with a complete tumor response (yT0), six of 28 patients had no visible nodes at DWI, which results in a specificity of 21%.

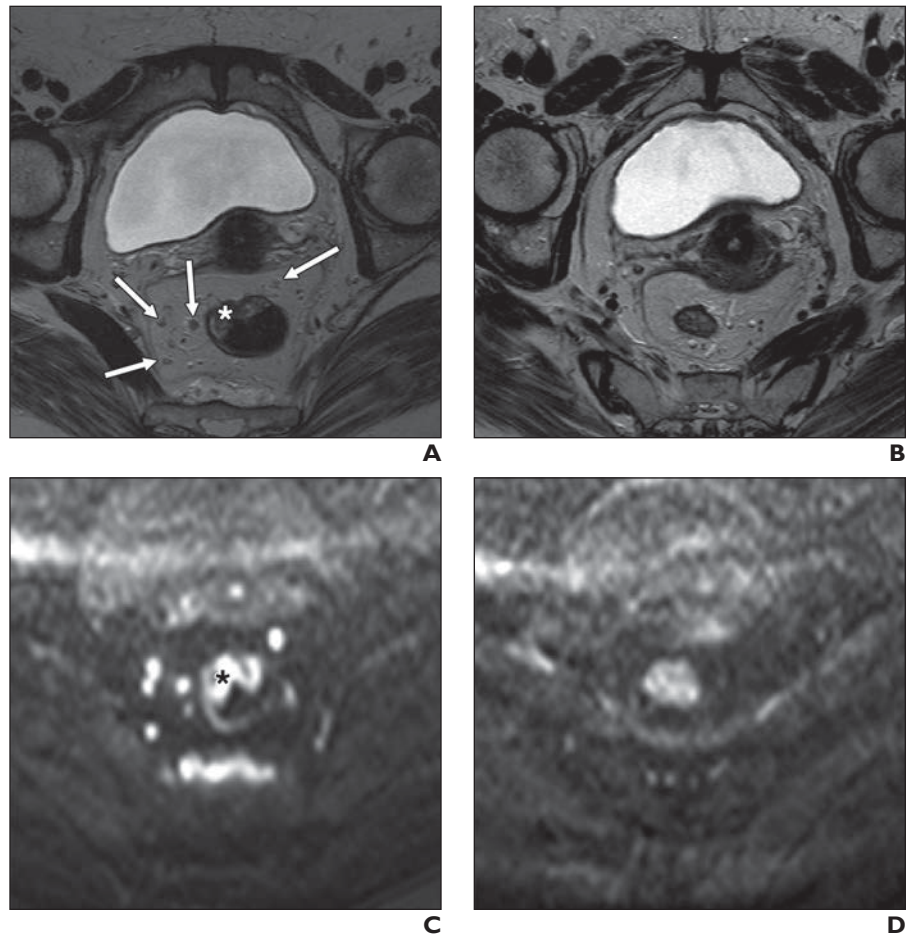
#### Interobserver Agreement

Agreement between the two readers regarding the number of nodes detected at DWI was good, with an intraclass correlation coefficient of 0.72 (95% CI, 0.46–0.84). For seven patients, both readers initially observed no nodes, and for 68 patients, both readers observed one or more nodes. For the remaining 15 patients, there was a discrepancy in the number of nodes (0 vs  $\geq 1$  nodes) observed by the two readers and an additional consensus reading was performed (which resulted in the diagnosis of 0 nodes in three patients and  $\geq 1$  nodes in the other 12 patients).

#### Discussion

The goal of this study was to evaluate whether the absence of visible lymph nodes at DWI after CRT is proof of a negative lymph node status. Although the absence of nodes at DWI was an infrequent finding, occurring in only 10 of 90 patients, our results show that this was concordant with a yN0 status in all cases. This finding suggests that, from a clinical point of view, patients with yN0 status can safely be identified when they have no visible nodes at restaging DWI. However, for most patients with a yN0 status (61/71 patients with yN0 status), nodes were still visible at DWI. Hence, specificity was only 14%, which would imply a very stringent patient selection, where many of the complete nodal responders will be missed.

Interestingly, the number of patients with no visible nodes at DWI was higher in the patients with a complete tumor response compared with patients with residual tumor. In the yT0 subgroup, 21% of the patients had no visible nodes at DWI, compared with only 4–8% of the patients who still had residual tumor. The specificity to discriminate yN-positive versus yN0 status—albeit still far from optimal—was thus better for the pa-



**Fig. 1**—72-year-old woman with rectal tumor.

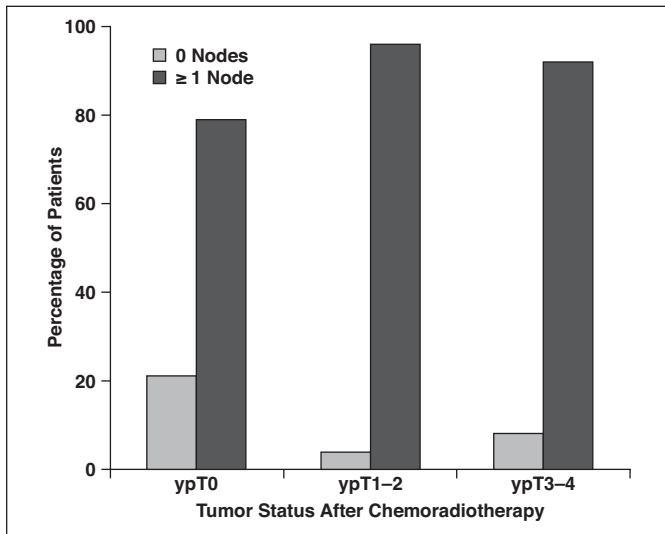
**A–D**, T2-weighted MR image obtained before treatment (**A**) shows rectal tumor (asterisk, **A**) and several lymph nodes in mesorectal fat (arrows, **A**), some of which are difficult to discern. On corresponding DW image (**C**), more nodes are observed and nodes are more conspicuous because of their marked high signal, comparable with that of tumor (asterisk, **C**), making them stand out compared with suppressed signal of mesorectal fat. No residual tumor is observed on T2-weighted MR image (**B**) or corresponding DW image (**D**) obtained after patient underwent chemoradiation therapy, and no residual nodes are observed. Patient had complete response (ypT0N0).

tients with a complete tumor response than for the whole patient group (21% vs 14%). This is beneficial because the yT0 group constitutes the most interesting subgroup with respect to the identification of potential candidates for organ-preserving treatments (in particular watchful waiting). For these patients, it is particularly important to identify residual nodal disease, because the nodes are left in situ and any missed residual nodal metastases harbor a potential risk for recurrence. The prevalence of a positive lymph node status after CRT is low in patients with a good tumor response (5–17%) [4, 7, 30, 31]. Moreover, as an effect of long-course neoadjuvant therapy, most lymph nodes decrease in size [15, 32]. As a result, residual nodal metastases mostly occur in very small nodes (< 3 mm). These small nodal sizes make it

difficult to detect and therefore interpret the nodes after CRT, resulting in low reported sensitivities of 42% for the detection of residual nodal metastases in patients with a good tumor response after CRT [15].

The sensitivity to detect residual positive nodes in our study was 100%, which is better than that reported in previous studies for routine T2-weighted MRI (42–89%) [12–15]. This means that, when there is residual nodal disease, we will always see residual nodes at post-CRT DWI. However, it does not work the other way around: when we see residual nodes at DWI, this does not necessarily indicate that there is residual nodal disease. High-signal-intensity nodes were also still visualized after CRT in 61 of 71 patients with yN0 status, resulting in a low specificity of 14%, which is considerably lower than the

## DWI Assessment of Rectal Cancer Nodes After CRT



**Fig. 2**—Percentage of patients with zero nodes versus one or more nodes visible at DWI ( $b = 1000 \text{ s/mm}^2$ ) specified for patients with complete response (ypT0), good response (ypT1–2), and poor response (ypT3–4) of their primary rectal tumor, respectively.

specificities in the range of 46–95% previously reported for routine T2-weighted MRI [12–15]. This is in line with the findings of previous studies showing that, when considering all high-signal nodes on DWI as positive for nodal disease, this leads to false-positive rates of up to 50% [24, 33, 34]. Hence, we will need to look for additional tools to further characterize the visible residual nodes after CRT. Inconsistent results have been reported for quantitatively measuring the apparent diffusion coefficient of nodes on DWI to differentiate between positive and negative lymph nodes, both for the primary staging of lymph nodes as well as for restaging of nodes after CRT [22, 23, 33–35]. Moreover, in small nodes, it can be very challenging to obtain reproducible apparent diffusion coefficient measurements [22]. A potentially promising alternative is the use of lymph node-specific contrast agents, with promising results reported for both ultrasmall superparamagnetic particles of iron oxide contrast agents, as well as for the gadolinium-based contrast agent gadofosveset trisodium [27, 28, 36, 37]. However, these contrast agents have not yet found their way into clinical practice.

Our study had some limitations. For 22 patients, long-term follow-up was used as a surrogate reference standard instead of histopathologic outcome. Patients had no signs of nodal recurrence for more than 2 years, with a median follow-up duration of 61 months (minimum, 44 months). Because previous studies have shown that both endoluminal and nodal recurrences mostly occur within the first 2 years, we believe this may be used as an alternative endpoint for a

ypN0 status [3]. Second, we evaluated nodes within only the mesorectal compartment because extramesorectal nodes are not routinely resected and therefore cannot be correlated with histopathologic outcome. Third, there were some variations in the DWI protocol (e.g., fat-suppression techniques) used throughout the course of the study. This, however, reflects daily practice where imaging protocols are subject to updates and optimization. All of the images were, however, subjectively deemed to be of good diagnostic quality by both observers. The quality of fat suppression was similar, and the signal-to-background ratio of the visualized lymph nodes was comparable in all studies. Fourth, the readers had a 3D T1-weighted sequence with 1-mm isotropic voxels at their disposal. This sequence was part of the protocol because of ongoing studies on lymph node imaging, but it is not typically part of routine clinical rectal MRI protocols. Its use in the current study may thus potentially limit the generalizability of our study results. However, in practice, lymph nodes were typically well recognized as nodes on the DWI sequence, and the need to refer to the T1-weighted sequence was limited. Finally, we did not perform a within-patient comparison of our results for DWI to routine assessment of the nodes on T2-weighted MRI, because the specific aim of our study was to test the hypothesis that the absence of nodes at DWI could be used to predict a yN0 status and various previous studies have already shown the superiority of DWI compared with T2-weighted MRI for the detection of nodes. We did, however, compare our results

to those previously reported in the literature for T2-weighted MRI.

In conclusion, our results suggest that—although it is not a frequent finding—the absence of lymph nodes on a restaging DWI image can be a reliable predictor of a node-negative status after neoadjuvant CRT in patients with locally advanced rectal cancer and that the percentage of patients without visible nodes at DWI is highest in patients with a complete tumor response. DWI may therefore play a supporting role in the selection of patients for organ preservation after CRT. When we see remaining nodes at DWI after CRT, we need to look for other tools to further characterize these nodes.

### References

1. Lezoche G, Baldarelli M, Guerrieri M, et al. A prospective randomized study with a 5-year minimum follow-up evaluation of transanal endoscopic microsurgery versus laparoscopic total mesorectal excision after neoadjuvant therapy. *Surg Endosc* 2008; 22:352–358
2. Verseveld M, de Graaf EJ, Verhoef C, et al. Chemoradiation therapy for rectal cancer in the distal rectum followed by organ-sparing transanal endoscopic microsurgery (CARTS study). *Br J Surg* 2015; 102:853–860
3. Habr-Gama A, Perez RO, Nadalin W, et al. Operative versus nonoperative treatment for stage 0 distal rectal cancer following chemoradiation therapy: long-term results. *Ann Surg* 2004; 240:711–717; discussion, 717–718
4. Maas M, Nelemans PJ, Valentini V, et al. Long-term outcome in patients with a pathological complete response after chemoradiation for rectal cancer: a pooled analysis of individual patient data. *Lancet Oncol* 2010; 11:835–844
5. Maas M, Lambregts DM, Nelemans PJ, et al. Assessment of clinical complete response after chemoradiation for rectal cancer with digital rectal examination, endoscopy, and MRI: selection for organ-saving treatment. *Ann Surg Oncol* 2015; 22:3873–3880
6. Gosens MJ, van Krieken JH, Marijnen CA, et al. Improvement of staging by combining tumor and treatment parameters: the value for prognostication in rectal cancer. *Clin Gastroenterol Hepatol* 2007; 5:997–1003
7. Park IJ, You YN, Skibber JM, et al. Comparative analysis of lymph node metastases in patients with ypT0–2 rectal cancers after neoadjuvant chemoradiotherapy. *Dis Colon Rectum* 2013; 56:135–141
8. Lahaye MJ, Engelen SM, Nelemans PJ, et al. Imaging for predicting the risk factors—the circumferential resection margin and nodal disease—of local recurrence in rectal cancer: a meta-analysis. *Semin Ultrasound CT MR* 2005; 26:259–268

9. Bipat S, Glas AS, Slors FJ, Zwinderman AH, Bossuyt PM, Stoker J. Rectal cancer: local staging and assessment of lymph node involvement with endoluminal US, CT, and MR imaging—a meta-analysis. *Radiology* 2004; 232:773–783
10. Engelen SM, Beets-Tan RG, Lahaye MJ, et al. MRI after chemoradiotherapy of rectal cancer: a useful tool to select patients for local excision. *Dis Colon Rectum* 2010; 53:979–986
11. Lahaye MJ, Beets GL, Engelen SM, et al. Locally advanced rectal cancer: MR imaging for restaging after neoadjuvant radiation therapy with concomitant chemotherapy. Part II. What are the criteria to predict involved lymph nodes? *Radiology* 2009; 252:81–91
12. Lee JH, Jang HS, Kim JG, et al. Prediction of pathologic staging with magnetic resonance imaging after preoperative chemoradiotherapy in rectal cancer: pooled analysis of KROG 10-01 and 11-02. *Radiother Oncol* 2014; 113:18–23
13. Koh DM, Chau I, Tait D, Wotherspoon A, Cunningham D, Brown G. Evaluating mesorectal lymph nodes in rectal cancer before and after neoadjuvant chemoradiation using thin-section T2-weighted magnetic resonance imaging. *Int J Radiat Oncol Biol Phys* 2008; 71:456–461
14. Brown G, Radcliffe AG, Newcombe RG, Dallimore NS, Bourne MW, Williams GT. Preoperative assessment of prognostic factors in rectal cancer using high-resolution magnetic resonance imaging. *Br J Surg* 2003; 90:355–364
15. Perez RO, Pereira DD, Proscurshim I, et al. Lymph node size in rectal cancer following neoadjuvant chemoradiation: can we rely on radiologic nodal staging after chemoradiation? *Dis Colon Rectum* 2009; 52:1278–1284
16. Kim SH, Lee JM, Hong SH, et al. Locally advanced rectal cancer: added value of diffusion-weighted MR imaging in the evaluation of tumor response to neoadjuvant chemo- and radiation therapy. *Radiology* 2009; 253:116–125
17. Park MJ, Kim SH, Lee SJ, Jang KM, Rhim H. Locally advanced rectal cancer: added value of diffusion-weighted MR imaging for predicting tumor clearance of the mesorectal fascia after neoadjuvant chemotherapy and radiation therapy. *Radiology* 2011; 260:771–780
18. Lambregts DM, Vandecaveye V, Barbaro B, et al. Diffusion-weighted MRI for selection of complete responders after chemoradiation for locally advanced rectal cancer: a multicenter study. *Ann Surg Oncol* 2011; 18:2224–2231
19. Song I, Kim SH, Lee SJ, Choi JY, Kim MJ, Rhim H. Value of diffusion-weighted imaging in the detection of viable tumor after neoadjuvant chemoradiation therapy in patients with locally advanced rectal cancer: comparison with T2 weighted and PET/CT imaging. *Br J Radiol* 2012; 85:577–586
20. Beets-Tan RG, Lambregts DM, Maas M, et al. Magnetic resonance imaging for the clinical management of rectal cancer patients: recommendations from the 2012 European Society of Gastrointestinal and Abdominal Radiology (ESGAR) consensus meeting. *Eur Radiol* 2013; 23:2522–2531
21. Mir N, Sohaib SA, Collins D, Koh DM. Fusion of high b-value diffusion-weighted and T2-weighted MR images improves identification of lymph nodes in the pelvis. *J Med Imaging Radiat Oncol* 2010; 54:358–364
22. Lambregts DM, Maas M, Riedl RG, et al. Value of ADC measurements for nodal staging after chemoradiation in locally advanced rectal cancer: a per lesion validation study. *Eur Radiol* 2011; 21:265–273
23. Heijnen LA, Lambregts DM, Mondal D, et al. Diffusion-weighted MR imaging in primary rectal cancer staging demonstrates but does not characterise lymph nodes. *Eur Radiol* 2013; 23:3354–3360
24. Heusner TA, Kuemmel S, Koeninger A, et al. Diagnostic value of diffusion-weighted magnetic resonance imaging (DWI) compared to FDG PET/CT for whole-body breast cancer staging. *Eur J Nucl Med Mol Imaging* 2010; 37:1077–1086
25. Nakai G, Matsuki M, Inada Y, et al. Detection and evaluation of pelvic lymph nodes in patients with gynecologic malignancies using body diffusion-weighted magnetic resonance imaging. *J Comput Assist Tomogr* 2008; 32:764–768
26. Lambregts DM, Rao SX, Sasses S, et al. MRI and diffusion-weighted MRI volumetry for identification of complete tumor responders after preoperative chemoradiotherapy in patients with rectal cancer: a bi-institutional validation study. *Ann Surg* 2015; 262:1034–1039
27. Heijnen LA, Lambregts DM, Martens MH, et al. Performance of gadofosveset-enhanced MRI for staging rectal cancer nodes: can the initial promising results be reproduced? *Eur Radiol* 2014; 24:371–379
28. Lambregts DM, Beets GL, Maas M, et al. Accuracy of gadofosveset-enhanced MRI for nodal staging and restaging in rectal cancer. *Ann Surg* 2011; 253:539–545
29. Greene FL, Page DL, Fleming ID, eds. *AJCC cancer staging manual*, 6th ed. Chicago, IL: American Joint Committee on Cancer, 2002
30. Bedrosian I, Rodriguez-Bigas MA, Feig B, et al. Predicting the node-negative mesorectum after preoperative chemoradiation for locally advanced rectal carcinoma. *J Gastrointest Surg* 2004; 8:56–62; discussion, 62–63
31. Yeo SG, Kim DY, Kim TH, et al. Pathologic complete response of primary tumor following preoperative chemoradiotherapy for locally advanced rectal cancer: long-term outcomes and prognostic significance of pathologic nodal status (KROG 09-01). *Ann Surg* 2010; 252:998–1004
32. Heijnen LA, Maas M, Beets-Tan RG. Nodal restaging in rectal cancer: why is restaging after chemoradiation more accurate than primary nodal staging? *Int J Colorectal Dis* 2016; 31:1157–1162
33. Attenberger UI, Pilz LR, Morelli JN, et al. Multiparametric MRI of rectal cancer: do quantitative functional MR measurements correlate with radiologic and pathologic tumor stages? *Eur J Radiol* 2014; 83:1036–1043
34. Yasui O, Sato M, Kamada A. Diffusion-weighted imaging in the detection of lymph node metastasis in colorectal cancer. *Tohoku J Exp Med* 2009; 218:177–183
35. Cho EY, Kim SH, Yoon JH, et al. Apparent diffusion coefficient for discriminating metastatic from non-metastatic lymph nodes in primary rectal cancer. *Eur J Radiol* 2013; 82:e662–e668
36. Koh DM, Brown G, Temple L, et al. Rectal cancer: mesorectal lymph nodes at MR imaging with USPIO versus histopathologic findings—initial observations. *Radiology* 2004; 231:91–99
37. Lahaye MJ, Engelen SM, Kessels AG, et al. USPIO-enhanced MR imaging for nodal staging in patients with primary rectal cancer: predictive criteria. *Radiology* 2008; 246:804–811