

# In Vivo Imaging of Hypoxia in Atherosclerotic Plaques in Humans

## Citation for published version (APA):

van der Valk, F. M., Sluimer, J. C., Voo, S. A., Verberne, H. J., Nederveen, A. J., Windhorst, A. D., Stroes, E. S. G., Lambin, P., & Daemen, M. J. A. P. (2015). In Vivo Imaging of Hypoxia in Atherosclerotic Plaques in Humans. *JACC-Cardiovascular Imaging*, 8(11), 1340-1341. <https://doi.org/10.1016/j.jcmg.2014.12.015>

## Document status and date:

Published: 01/11/2015

## DOI:

[10.1016/j.jcmg.2014.12.015](https://doi.org/10.1016/j.jcmg.2014.12.015)

## Document Version:

Publisher's PDF, also known as Version of record

## Document license:

Taverne

## Please check the document version of this publication:

- A submitted manuscript is the version of the article upon submission and before peer-review. There can be important differences between the submitted version and the official published version of record. People interested in the research are advised to contact the author for the final version of the publication, or visit the DOI to the publisher's website.
- The final author version and the galley proof are versions of the publication after peer review.
- The final published version features the final layout of the paper including the volume, issue and page numbers.

[Link to publication](#)

## General rights

Copyright and moral rights for the publications made accessible in the public portal are retained by the authors and/or other copyright owners and it is a condition of accessing publications that users recognise and abide by the legal requirements associated with these rights.

- Users may download and print one copy of any publication from the public portal for the purpose of private study or research.
- You may not further distribute the material or use it for any profit-making activity or commercial gain
- You may freely distribute the URL identifying the publication in the public portal.

If the publication is distributed under the terms of Article 25fa of the Dutch Copyright Act, indicated by the "Taverne" license above, please follow below link for the End User Agreement:

[www.umlib.nl/taverne-license](http://www.umlib.nl/taverne-license)

## Take down policy

If you believe that this document breaches copyright please contact us at:

[repository@maastrichtuniversity.nl](mailto:repository@maastrichtuniversity.nl)

providing details and we will investigate your claim.

# iMAIL

## LETTERS TO THE EDITOR

### In Vivo Imaging of Hypoxia in Atherosclerotic Plaques in Humans

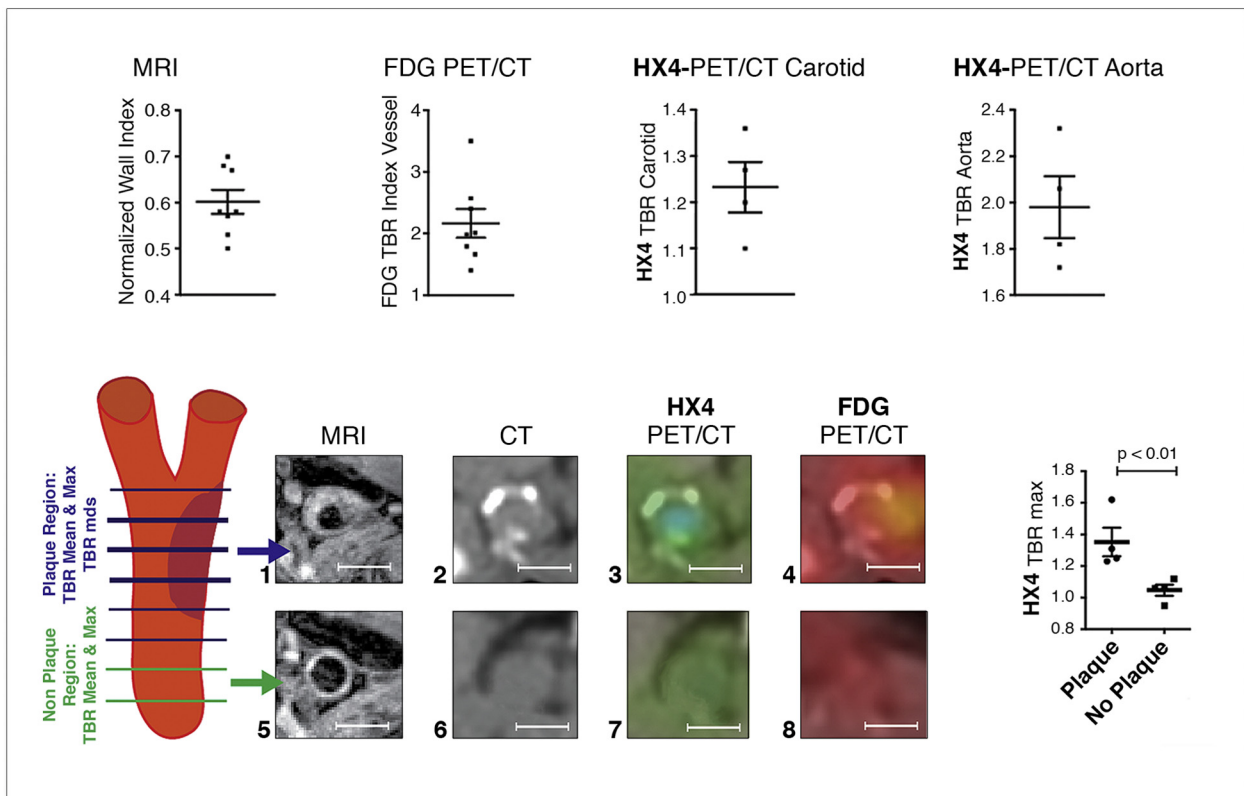


In recognition of hypoxia's involvement in atherogenesis, it has been suggested that plaque hypoxia be used as a target for molecular imaging to identify high-risk patients, anticipate acute cardiovascular events, and monitor atheroma therapies (1). We demonstrate the potential of hypoxia imaging in humans using a highly selective hypoxia

marker,  $^{18}\text{F}$ -2-(4-((2-nitro-1H-imidazol-1-yl)methyl)-1H-1,2,3-triazol-1-yl)propan-1-ol (HX4), for positron emission tomography/computed tomography (PET/CT) (2).

In 8 patients with carotid artery stenosis, we performed multimodal imaging within 3 weeks, consisting of: 1) magnetic resonance imaging (MRI) with a 3.0-T whole-body scanner (Intera, Philips, Best, the Netherlands) to calculate the normalized wall index (mean wall area/outer wall area) (3); 2)  $^{18}\text{F}$ -fluorodeoxyglucose (FDG)-PET/CT (100 MBq); and 3) HX4-PET/CT (100 MBq) imaging on a dedicated scanner (Gemini, Philips) 90 min after tracer infusion. FDG and HX4 uptake was quantified in the carotid

**FIGURE 1** Hypoxia Imaging in Atherosclerosis



Patients included in this study were characterized by advanced atherosclerosis, as detected by the elevated normalized wall index (NWI) on magnetic resonance imaging (MRI) and elevated  $^{18}\text{F}$ -fluorodeoxyglucose (FDG) uptake in the arterial wall, expressed as the target-to-background ratio (TBR) in the index vessel measured with positron emission tomography/computed tomography (PET/CT). As a marker of hypoxia,  $^{18}\text{F}$ -2-(4-((2-nitro-1H-imidazol-1-yl)methyl)-1H-1,2,3-triazol-1-yl)propan-1-ol (HX4) uptake was enhanced in both the carotid arteries as the aorta, quantified as HX4 TBR using PET/CT (scale bars indicate 2 cm). A schematic of the analyzed segments with the corresponding MRI, CT, HX4-PET/CT, and FDG-PET/CT images in the most diseased area of the plaque compared to nonplaque regions underscore plaque-specific HX4 uptake in patients (scale bars indicate 1 cm).

arteries and aorta in regions with and without plaque, providing a target-to-background ratio (TBR) as the ratio of maximal/mean arterial wall standardized uptake values and mean venous blood activity (3).

The included patients (4 men and 4 women; mean age  $68 \pm 6$  years) had a history (>6 months) of transient ischemic attack ( $n = 5$ ), ischemic stroke ( $n = 3$ ), and/or myocardial infarction ( $n = 3$ ). Patients had an increased carotid wall thickness as shown by MRI, providing a mean normalized wall index of  $0.60 \pm 0.07$  (Figure 1). In addition, patients exhibited enhanced FDG uptake at the level of both the carotid arteries and aorta as assessed with PET/CT, as shown by the increased maximal target-to-background ratio for  $^{18}\text{F}$ -fluorodeoxyglucose ( $^{18}\text{F}$ FDG TBRmax) for the carotid arteries ( $1.72 \pm 0.25$ ) and aorta ( $2.61 \pm 0.64$ ) (Figure 1).

Subsequently, HX4 uptake was assessed at the level of the carotid arteries in 4 patients and at the level of the aorta in the other 4 patients (Figure 1). When quantified,  $^{18}\text{F}$  TBRmax of the carotid arteries was  $1.27 \pm 0.13$  and  $1.98 \pm 0.27$  for the aorta (Figure 1). HX4 uptake was specific to plaque regions  $^{-18}\text{F}$  TBRmax was  $1.32 \pm 0.16$  in the most diseased segment compared with  $1.15 \pm 0.20$  in the nonplaque region ( $p < 0.01$ ) (Figure 1). Following the relationship between plaque burden and hypoxia, we observed a strong correlation between atherosclerotic HX4 uptake and carotid arterial wall dimensions ( $r = 0.97$ ;  $p = 0.04$ ). In addition, we showed a correlation with HX4 uptake and FDG uptake in the plaque ( $r = 0.75$ ;  $p = 0.03$ ).

Taken together, we showed increased HX4 uptake in plaque regions that correlated to arterial wall dimensions and metabolic activity. Recently, a pre-clinical PET study in atherosclerotic rabbits showed positive correlations of the hypoxia tracer  $^{18}\text{F}$ -fluoromisonidazole to plaque burden and macrophage content, but not to FDG uptake, which might reflect distinct differences in rabbit and human plaque composition (4). In support, previous work in human carotid artery specimens showed in situ correlations between a nonradioactive structural analogue of HX4, pimonidazole, and features of plaque vulnerability (5). Nonetheless, additional studies are warranted to assess HX4's relationship with FDG and its direct link to hypoxia-associated molecules in human plaques. Future studies are aimed at: 1) using additional MRI imaging sequences or MRI-traceable HX4 to overcome the low spatial resolution of PET and provide greater insight in HX4 uptake in different plaque components; and 2) addressing the relationship between HX4, hypoxia, and plaque vulnerability in vivo.

In conclusion, we present a noninvasive imaging approach to visualize hypoxia in advanced atherosclerotic lesions in humans in vivo. Current data support efforts to develop and implement imaging modalities to quantify hypoxia in patients at risk for cardiovascular disease.

Fleur M. van der Valk, MD

Judith C. Sluimer, MD, PhD

Stefan A. Vöo, MD

Hein J. Verberne, MD, PhD

Aart J. Nederveen, PhD

Albert D. Windhorst, MD, PhD

Erik S.G. Stroes, MD, PhD

Philippe Lambin, MD, PhD

Mat J.A.P. Daemen, MD, PhD\*

\*Academic Medical Center

Department of Pathology, Room M2-206

PO Box 22660

1100 DD, Amsterdam

the Netherlands

E-mail: [m.j.daemen@amc.nl](mailto:m.j.daemen@amc.nl)

<http://dx.doi.org/10.1016/j.jcmg.2014.12.015>

Please note: The authors have reported that they have no relationships relevant to the contents of this paper to disclose.

## REFERENCES

1. Carlin S, Humm JL. PET of hypoxia: current and future perspectives. *J Nucl Med* 2012;53:1171-4.
2. Chen L, Zhang Z, Kolb HC, et al.  $^{18}\text{F}$ -HX4 hypoxia imaging with PET/CT in cancer: comparison with  $^{18}\text{F}$ -FMISO. *Nucl Med Commun* 2012;33:1096-102.
3. Fayad ZA, Mani V, Woodward M, et al. Rationale and design of dal-PLAQUE. *Am Heart J* 2011;162:214-21.e2.
4. Mateo J, Izquierdo-Garcia D, Badimon JJ, et al. Noninvasive assessment of hypoxia in rabbit advanced atherosclerosis using  $^{18}\text{F}$ -fluoromisonidazole positron emission tomographic imaging. *Circ Cardiovasc Imaging* 2014;7:312-20.
5. Sluimer JC, Gasc JM, van Wanroij JL, et al. Hypoxia, hypoxia-inducible transcription factor, and macrophages in human atherosclerotic plaques are correlated with intraplaque angiogenesis. *J Am Coll Cardiol* 2008;51:1258-65.

## Serial Multimodality Evaluation of Aortocoronary Bypass Grafts During the First Year After CABG Surgery



The CABG-PRO (Cardiac Catheterization for Bypass Graft Patency Rate Optimization) trial (NCT01063491), was a randomized, controlled, double-blind, parallel-group study of early versus no early graft angiography in patients undergoing coronary artery bypass graft (CABG) surgery. Enrollment in the CABG-PRO trial was stopped early because of low rates of saphenous vein graft (SVG) percutaneous coronary intervention among patients undergoing early coronary angiography (1 of 21 patients). Of those 21 patients, matched