

P R A C T I C E

Case Report: The Effects of Massage Therapy on a Woman with Thoracic Outlet Syndrome

Mary Lillias Wakefield, BHS, MT

Mt. Eden Lymphoedema and Massage Clinic, Mt Eden, Auckland, New Zealand

Introduction: Thoracic outlet syndrome (TOS) refers to a group of conditions resulting from compression of the neurovascular structures of the thoracic outlet. The parameters for physical therapy include myofascial release (MFR), neuromuscular therapy (NMT), muscle strengthening, and stretching. This case study examined the effects of neuromuscular therapy, massage, and other manual therapies on a 56-year-old female presenting with bilateral numbness over the forearms and hands on waking. Numbness occurred most days, progressing to “dead rubbery” forearms and hands once or twice a month.

Methods: The treatment plan was implemented over eight weeks and consisted of six, 50-minute bodywork sessions. Several nonbodywork strategies were also employed to address potential contributing factors to the TOS symptomology experienced by the client. Objective measurements included posture analysis (PA), range of movement (ROM), and Roos and Adson’s tests. The Measure Your Own Medical Outcome Profile (MYMOP2), a client-generated measure of clinical outcome, was used to measure clinical change.

Results: MYMOP2 overall profile score results demonstrated an improvement of 2.25 from

pretreatment to post-treatment measurement. Clinically meaningful change was measured by the individual and was indicative of substantial symptom improvement where a score change of over one was considered as meaningful.

Conclusions: A course of massage was effective for numbness symptoms in an individual with TOS, and results lasted over a year without additional treatments. Further research is needed to fully understand the effects of massage for TOS symptoms.

KEY WORDS: entrapment neuropathy; brachial plexus; subclavian compression; lymphatic massage; neuromuscular therapy; MYMOP2

INTRODUCTION

Thoracic outlet syndrome (TOS) results from compression of the neurovascular structures within the region of the neck and axilla, called the thoracic outlet⁽¹⁾. Three sites of potential compression are shown in Figure 1⁽²⁾. Structures involved include the brachial plexus, subclavian artery, and/or subclavian vein⁽²⁾. Symptoms may be neural, vascular, and/or

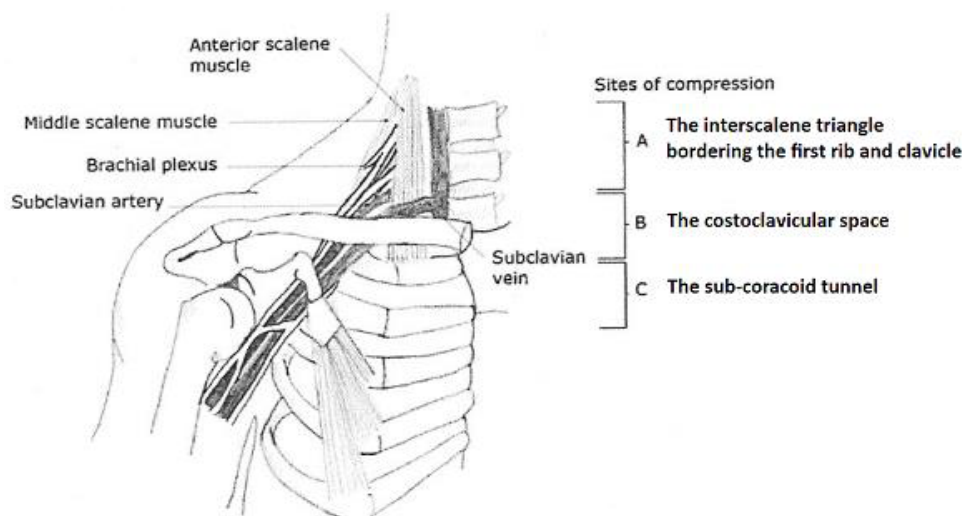


FIGURE 1. Thoracic outlet anatomy⁽²⁾.

lymphatic related, the most prevalent being neural⁽³⁾. Neurogenic symptoms are predominantly unilateral and include muscle weakness, sensory disturbance, and/or reflex hypoactivity⁽⁴⁾.

The presence of a seventh cervical rib, an accessory muscle or abnormally close interscalene muscle rib attachments render the neurovascular structures more susceptible to compression⁽³⁾. Other predisposing factors include poor posture, sleeping position, and poor breathing⁽³⁾. Sport featuring repetitive overhead movements can precipitate TOS^(2,5). Trauma to the neck can also be a contributing factor, where excessive muscle spasm results in anterior scalene hypertonicity⁽²⁾.

Nonsurgical interventions, such as breathing education, have been shown to be beneficial in TOS by decreasing pressure on neurovascular structures^(6,7). Surgical interventions are the treatment of choice in severe cases, in most literature⁽⁸⁾. Studies of conservative treatment are fewer and rarely cover the details of the interventions employed^(8,9). This massage-focused case study was designed to reduce the gap in evidence-based research for conservative TOS treatments. The aim of this case report is to describe the process and outcomes of a six-session massage therapy treatment plan including neuromuscular therapy (NMT), manual therapy techniques, and supplementary nonbodywork aspects for a 56-year-old female presenting with TOS symptomology.

METHODS

Client Profile

The subject presented in 2011 with a two-year history of waking with bilateral numbness (more pronounced on the left) over the medial aspect of the anterior and posterior forearms and hands, specifically,

in the third, fourth, and fifth fingers. Numbness occurred most days, progressing to “dead rubbery” forearms and hands once or twice a month. Sleeping on right side (more so than left) resulted in symptoms, but normal sensation returned within 5 min of waking. Symptoms did not correlate with activities of daily living or include pain.

The client reported two significant prior falls: the first (ten years prior) involved right-sided contact and the second (two years prior) involved occipital impact, which resulted in a violent headache. Following the most recent fall, the client experienced continual numbness in the upper extremities upon waking. Neither medical attention nor pharmaceutical intervention was sought by the client, yet she alluded to worrying about causative pathology if awake at night.

Pretreatment assessment included postural analysis (PA), utilizing a grid and plum line, as shown in Figure 2. In standing PA, the head was rotated to the right with left shoulder and clavicle elevation and protraction. Increased anterior tilt of the right scapula was evident. Sternocleidomastoid and scalenii muscles were hypertonic (predominantly right-sided) with fascial tension visible in surrounding neck, throat, and supraclavicular areas. Cervical lordosis was absent. Both forearms were pronated (left more so). Supine observation confirmed the above findings, although the head became flexed to the left demonstrating tension within the left upper trapezius and scalenii group. It was observed that the client used upper chest breathing.

For thoroughness⁽²⁾, all-inclusive testing of the upper limb and cervical spine were conducted, including active (AROM) and passive ranges of movement of the cervical spine, shoulder girdle, shoulder, elbow, and wrist⁽⁶⁾. Both active and passive ROM testing identified limited cervical spine lateral flexion and rotation. Cervical spine flexion passive ROM produced symptoms (numbness in fifth digits), which

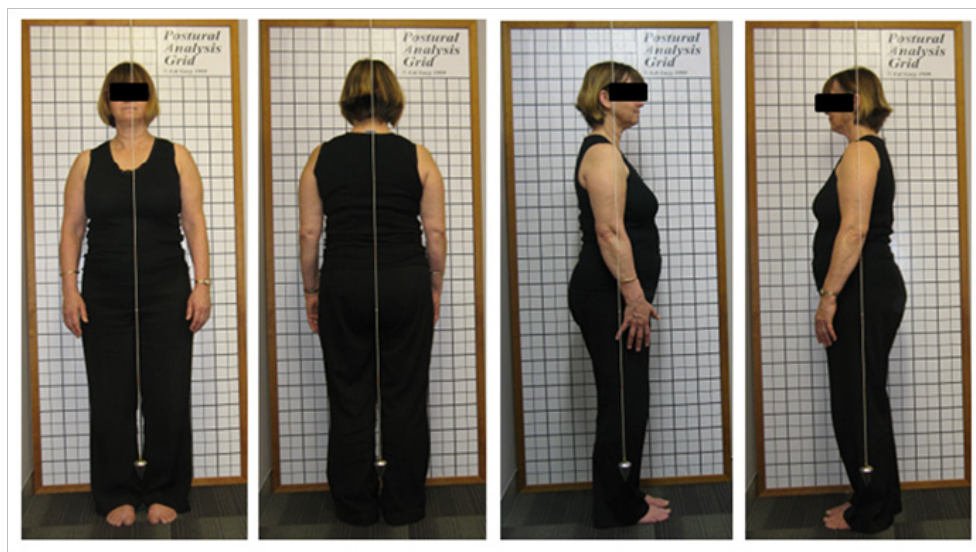


FIGURE 2. Postural analysis (PA), utilizing a grid and plum line.

were more pronounced in the right limb. Medial and lateral shoulder rotations were limited, with symptom presentation on passive left medial rotation and right lateral rotation. Elbow flexion, extension, and wrist flexion (AROM) testing were all symptomatic at end range. All symptoms were confirmed in the lower arms and hands; more specifically, symptoms occurred in the palmar cutaneous branches of the ulnar nerve, a peripheral branch of the lower brachial plexus. This presentation is indicative of TOS⁽¹⁰⁾.

The Valsalva and Slump tests, general neurological assessments known as safe with low-risk, were performed to rule out neural tension restriction as the causation for the presenting symptomology^(1,4). Both tests were negative. Tinel's peripheral nerve test was performed to exclude carpal tunnel syndrome⁽²⁾ and the result was negative.

Specific tests indicative of subclavian arterial compression were performed and included the Roos test, Allen maneuver, and Adson's test⁽⁴⁾, all of which were positive for compression. Roos test positioning places arterial, venous, and nervous architecture in tension simultaneously, where the scalene, costoclavicular, and axillary portions are all at stress⁽²⁾. In comparison, Adson's test assesses the scalene triangle and the first rib restriction^(2,11).

Palpation revealed constricted and taut fascia over the left side of the neck in comparison to the right. Sternocleidomastoid, scalenii, and upper trapezius muscles were hypertonic, the left more so than right. Muscle hypertonicity was also evident centrally over the lower cervical and upper thoracic spine. The inferior portion of the cervical spine was more prominent. Lymphatic congestion was evident through the anterior neck. Palpation did not recreate the presenting symptoms.

After the initial assessment for this case study, the client visited her medical practitioner to discuss the

whiplash and fall incidents. He ordered X-rays to ascertain cervical spine structural stability and to rule out any anomalies associated with TOS. The radiologist reported degenerative disc changes at C4-C5 and C5-C6, but no suboccipital instability. With this in mind, there were no clinical contraindications to massage.

Therapist Description

The treatment therapist (author) was in her final year of a three-year, 3600-hr Bachelor of Health Studies (BHS) degree program at the New Zealand College of Massage, Auckland, New Zealand during the report period. The New Zealand Qualifications Authority (NZQA) accredited the BHS with core modules in anatomy, physiology and pathology, musculoskeletal anatomy, and clinical therapeutics, along with research methodology, biochemistry, and health psychology. Additional therapist training at the time of report included Casley-Smith certification in complex lymphatic therapy. Treatments for this report occurred in a therapeutic clinic devoted to massage therapy.

Treatment Plan

The pretreatment muscular and neural test results indicated a presentation of TOS — more specifically, of subclavian artery compression and lower branch brachial plexus compression. The client's treatment goal was to reduce her bilateral numbness and "dead rubbery" feeling in forearms and hands on waking. The treatment plan developed for the client included NMT, therapeutic and lymphatic massage, and other manual therapies such as myofascial release (MFR) and myofascial thoracic inlet diaphragm release (Table 1). These techniques aimed to reduce symptomatic muscle hypertonicity and myofascial

TABLE 1. Description of Massage Techniques Used in Each Session

<i>Session</i>	<i>Technique</i>	<i>Time</i>	<i>Muscle/Muscle Groups</i>
1,2	MFR (diaphragm) ⁽¹²⁾	5 min	thoracic inlet
	MFR ⁽¹³⁾	20 min	pectoralis major/minor, SCM, scalenii
	Lymphatic massage ⁽¹⁴⁾	5 min	anterior neck
	NMT ⁽¹¹⁾	5 min	upper trapezius, lower trapezius
	Broad slow effleurage ⁽¹¹⁾	15 min	upper and midback focusing on erector spinae
3, 4	MFR (diaphragm) ⁽¹²⁾	5 min	thoracic inlet
	MFR ⁽¹³⁾	20 min	pectoralis major/minor, SCM, scalenii
	NMT ⁽¹¹⁾	20 min	SCM, scalenii, upper and lower trapezius, posterior suboccipitals, levator scapulae
	Muscle energy technique ⁽¹¹⁾	3 min	sternoclavicular joint, acromioclavicular joint
	Cranial base release ⁽¹²⁾	2 min	posterior suboccipitals
5,6	MFR ⁽¹³⁾	20 min	anterior chest and rib cage, anterior neck
	NMT ⁽¹¹⁾	25 min	SCM, scalenii, upper trapezius, levator scapulae, splenius capitis, anterior deltoid, forearm flexors
	Muscle energy technique ⁽¹¹⁾	3 min	sternoclavicular joint, acromioclavicular joint
	Cranial base release ⁽¹²⁾	2 min	posterior suboccipitals

constriction, and improve movement in the neck and surrounding area whilst alleviating pressure on neurovascular structures⁽³⁾. The treatment plan was implemented during the course of eight weeks and consisted of six, 50-min bodywork sessions. The initial intention for implementation was for the client to have weekly treatments, but illness necessitated two skipped weeks between sessions five and six. No adverse events occurred during the course of treatment.

For home care, muscle stretching was recommended, involving lateral neck stretch (sternocleidomastoid, scalenii, and levator scapulae), rotating neck stretch (sternocleidomastoid, scalenii, semispinalis, and splenius capitis), and bent arm chest stretch (pectoralis major and minor)⁽¹⁵⁾.

Several nonbodywork strategies were employed during the course of the massage treatment plan in an effort to address the potential contributing factors to the TOS symptomology experienced by the client.

These strategies included breathing education and nutrition and hydration assessment, together with sleep and exercise recommendations.

Assessments

Several assessments were used to measure treatment plan effectiveness including those typical in massage practice such as PA, ROM, and palpation. The Roos and Adson's tests, less typical in massage practice, were also utilized to assess subclavian arterial compression⁽⁴⁾.

ROM measurements were taken using a tape measure with the client in the anatomical position⁽¹⁰⁾. Fixed measurement points were established for each objective measurement to ensure reliability of data collected (Note: footnotes for Tables 2 and 3 outline the landmarks used to collect data). To facilitate interpretation of measurement data, each recording

TABLE 2. Cervical Spine Active Range of Movement (AROM)

<i>Movement</i>	<i>Pretreatment Data</i>	<i>Pretreatment Data (converted to degrees)</i>	<i>Post-treatment Data</i>	<i>Post-treatment Data (converted to degrees)</i>
Flexion ^a (AO ^b)	14.0 cm	48°	12.0 cm	44°
Flexion ^a (C7 ^c)	10.0 cm	39°	8.0 cm	33°
Extension ^a (AO ^b)	16.5 cm	53°	17.0 cm	54°
Extension ^a (C7 ^c)	17.0 cm	54°	17.5 cm	54°
Lateral flexion ^d (right)	21.5 cm	11°	20.0 cm	17°
Lateral flexion ^d (left)	19.5 cm	19°	17.0 cm	28°
Rotation ^d (right)	15.0 cm	50°	14.0 cm	48°
Rotation ^d (left)	14.0 cm	48°	13.5 cm	47°

Points of measurement using tape measure:

^aFlexion and ^aExtension were measured from suprasternal notch to tip of nose

^bAtlanto-occipital joint

^cSeventh cervical vertebrae

^dLateral flexion and ^dRotation were measured from acromion to tip of nose

To facilitate trigonometric calculation for flexion, extension and lateral rotation, a vertical plan view measurement was taken using a horizontal line dissecting both external auditory meatus's and drawing a perpendicular line to the tip of nose (12.5 cm). For lateral flexion, a vertical plan view measurement was taken using a horizontal line dissecting both external auditory meatus's and finding the midpoint. From this point, a measurement was made to the acromion (21 cm). Readers will note that improved flexion, lateral flexion, and rotation were indicated with smaller measured values measured at post-treatment, compared to pretreatment. Conversely, in extension, a larger measured value represents an increase in ROM.

TABLE 3. Shoulder AROM (reduced range only)

<i>Movement</i>	<i>Pretreatment Data</i>	<i>Pretreatment Data (converted to degrees)</i>	<i>Post-treatment Data</i>	<i>Post-treatment Data (converted to degrees)</i>
Medial rotation (right)	16.0 cm	44°	13.5 cm	36°
Medial rotation (left)	14.5 cm	39°	13.0 cm	34°
Lateral rotation (right)	10.5 cm	27°	7.5 cm	19°
Lateral rotation (left)	12.5 cm	32°	8.0 cm	20°

All centimeter measurements, taken from tape measure, are from styloid process of ulna to massage table. To facilitate trigonometric calculation, forearm length from styloid process of ulna to olecranon was 23 cm. Readers will note that improved medial and lateral rotation was indicated with smaller measured values measured at post-treatment, compared to pretreatment.

was converted from centimeters into degrees^(16,17) using a trigonometry[†] formula and then compared to standard norms⁽¹⁰⁾.

The most notable assessment utilized in this case report was the MYMOP2 tool, which is recognized as an effective way to measure patient-centered outcomes^(18,19). The MYMOP2 consists of seven-point Likert scales for four items: two items relate to symptoms of importance, and the others relate to the impact on a self-defined activity and to general well-being^(18,20). MYMOP2 scores derive from the four Likert scales, with zero representing ‘best possible’ and six ‘worst experienced’ over assessment periods⁽¹⁸⁾. Scores can be considered per item or as an overall MYMOP2 profile score, which is an average of the four components, where higher scores indicate worse outcomes. When considering change on an individual basis, one needs to consider change seen within each of the four parameters measured, where clinically significant change is measured by its importance to that individual⁽²¹⁾. At pretreatment, the client identified bilateral forearm and hand numbness on waking and “dead rubbery” feeling as the two self-identified symptoms and scored them 3 and 6, respectively. The activity she identified as difficult was being unable to use her hands on waking and was scored at 3. She scored her general well-being at 1. The client’s overall MYMOP2 score was 3.25 pre-intervention.

Data points were established prior to treatment (pretreatment) and one week after treatment finish (post-treatment) for PA, ROM, and MYMOP2, with a midtreatment measurement (after session 4) for MYMOP2 only.

RESULTS

Post-treatment PA (Figure 3) demonstrated the shoulders were level, highlighting a neck translation to the right. Both forearms remained pronated. Supine observations confirmed findings, except that head position was neutral. Having photographs taken was stressful for the client and hindered her relaxation. This was evident in the inset photograph taken minutes before the post-treatment photographs (Figure 3).

Improved cervical spine and shoulder AROM was seen in all post-treatment data. Nevertheless, cervical spine rotation, lateral flexion, and shoulder medial rotation remained at less than normal limits (Tables 2 and 3). There was no tingling or numbness during

post-treatment testing. Pain, which had not been part of the initial assessment, had not occurred with treatment nor was it present in post-treatment assessment.

Both pretreatment and post-treatment data demonstrated a positive Roos test, but Adson’s test changed from positive to negative as a result of the massage treatment.

Following treatment assessment, palpation revealed softening of the fascia surrounding the neck and no detectible lymphatic congestion. Taut muscle fibers were reduced in sternocleidomastoid, scalenii, and upper trapezius.

MYMOP2 post-treatment results highlighted a meaningful improvement in the two identified symptoms (Figure 4). The key symptomatic improvement was absence of “dead rubbery” feeling post-treatment, something that progressed from worst possible (6) to best (0) outcome. Bilateral forearm and hand numbness scores and the chosen activity (arm movement on waking) reduced from 3 to 1 at post-treatment. Client well-being was initially scored at 1 and at post-treatment increased to 2, due to increasing work pressures, according to the client. Symptomatic reduction in bilateral forearm and hand numbness was achieved, where symptoms now occurred once a month, rather than six or seven times weekly. Although some aspects of the client’s ROM were limited, improvements were meaningful to the client, as indicated by the clinically significant change in MYMOP2 scores.

DISCUSSION

TOS is a multifaceted condition with complex and varied presentations where accurate diagnosis and treatment are not without difficulty^(2,3). Watson et al.⁽²²⁾ highlighted the importance of a structured methodology in conservative treatment. This case report offers a uniform approach that is both effective and reduces the risk of symptom exacerbation due to aggressive intervention resulting in further damage. A retrospective review of TOS (n = 500) by Ambrad-Chalela et al.⁽⁸⁾ demonstrated that 17 cases with recurrent symptoms were offered physical therapy (massage, mobilization, ultrasound, and scalene stretching) with results showing a lack of improvement. The methodology description for this study was limited and, therefore, difficult to assess; however, it may provide support for the possibility that the massage aspects of the treatment plan produced a positive outcome. Vanti et al.⁽²³⁾ identified that conservative therapy outcomes were often complicated by small sample sizes, disparity in inclusion criteria, and differing study methodology. While this case report is limited by its inherently small sample size, it does realize the call made by Vanti and colleagues⁽²³⁾ for clearly documented conservative treatment protocols, which are essential to standardized research.

[†] Trigonometry is the study of triangles and the relationship between the sides and angles contained within⁽¹⁶⁾. The formula: “SOH CAH TOA,” is an acronym for Sine θ [angle] = Opposite length / Hypotenuse length; Cosine θ [angle] = Adjacent length / Hypotenuse length, and Tangent θ [angle] = Opposite length / Adjacent length.

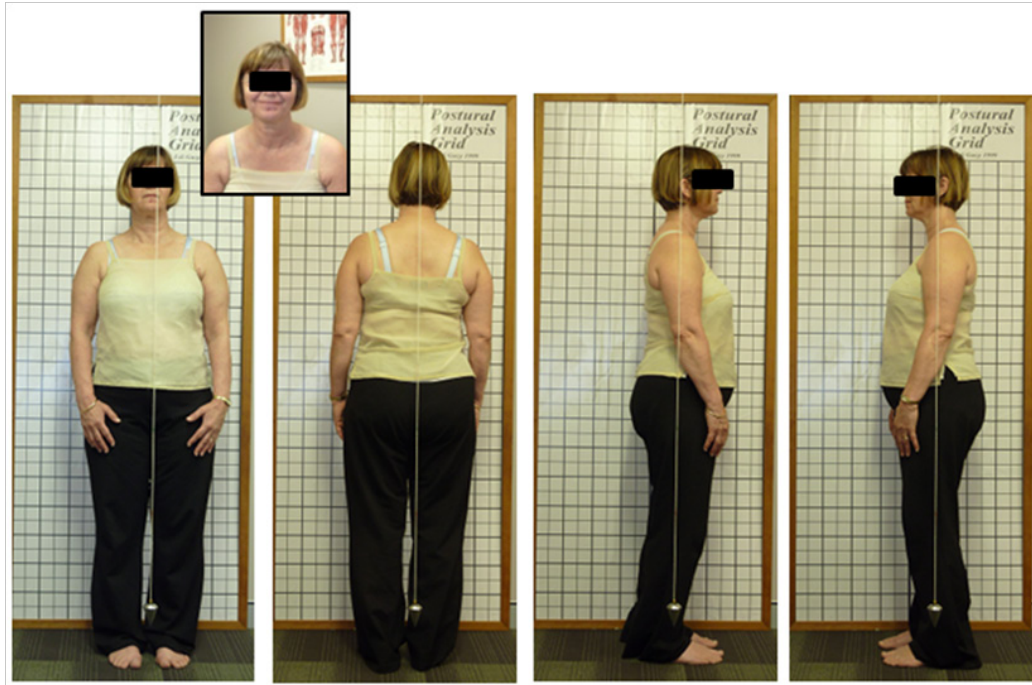

FIGURE 3. Post-treatment PA.

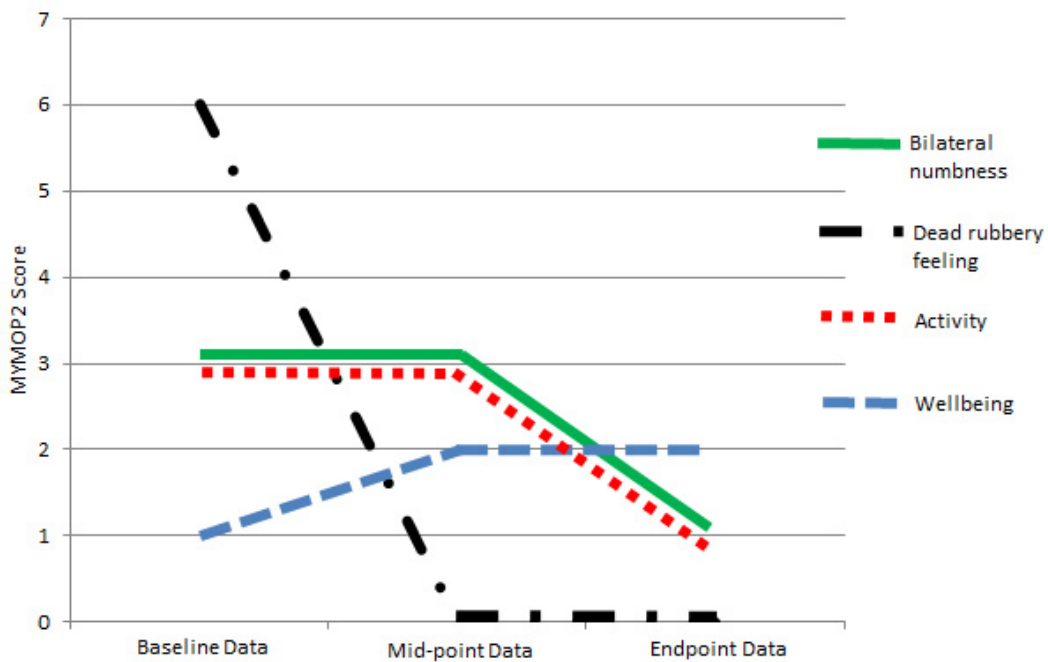


FIGURE 4. MYMOP2 results.

In addition to descriptive improvements measured by PA, ROM, and palpation, the client in this case report experienced clinically meaningful improvement in her condition, as evidenced by MYMOP2. Complete absence of “dead rubbery” arm symptom and the reduction of bilateral forearm and hand numbness to once monthly were considered clinically significant improvement by the client. Midtreatment data collection results highlighted no change in symptom one, (bilateral forearm and hand numbness), but a complete and sustained improvement in symptom 2 (“dead rubbery” feeling). In future research, for clients presenting with symptom two only, an effective time frame may be four treatments. However, where individuals presenting with TOS symptomology as described in symptom one, more than four treatments may be needed to be effective. The MYMOP2 questionnaire proved to be an effective client-centered assessment tool that was easily used in practice⁽²⁴⁾. It would be a good tool to include in future massage research for TOS and other conditions.

Improved post-treatment specific test results, where Roos test remained positive and Adson’s test changed to negative, warrants mention. The Roos test assesses the scalene, costoclavicular, and axillary areas⁽²⁾, whereas Adson’s test assesses the scalene triangle and first rib attachment⁽¹¹⁾. The specific test results could highlight the need for further bodywork in the costoclavicular and axillary regions.

As introduced in the description of the treatment plan for this case report, several nonbodywork strategies were employed in an effort to address potential contributing factors to the TOS symptomology experienced by the client and to support the massage treatment applied. These types of strategies are typical in massage practice, but are often excluded in discussion regarding massage treatment effectiveness. This treatment plan included keeping diaries for a week regarding nutrition, hydration, and symptomology. A key factor in long-term management was learning correct diaphragmatic breathing⁽⁷⁾.

Food and fluid diaries highlighted a daily water intake averaging only 400 mls. Poor hydration, as exhibited by the client, can lead to chemical and fluid imbalance within tissue that predisposes to inflammation⁽²⁵⁾. It is believed that, as cellular waste accumulates, muscle tissue and surrounding fascia show signs of inflammation and become congested, and trigger points form⁽²⁶⁾. The client adjusted her fluid intake to a recommended daily fluid intake of 30 mls per kilogram of body weight⁽²⁷⁾. While tissue tension was evident at pretreatment palpation, it was substantially improved at post-treatment, perhaps partly due to her improved hydration.

The client reported that she slept in fetal position with her shoulders and head supported on one pillow. The quality of bed, mattress, and/or pillows has been shown to aggravate TOS symptoms⁽³⁾. Sleeping

position was discussed, with recommendations made regarding sleeping either supine or on the side, ensuring that she tucked the corners of the pillow between her chin and shoulders⁽³⁾. The symptom diary emphasized exacerbation of symptoms with right-sided sleeping. Bolstering, in the form of a long pillow along the right side, was recommended to address this. Coincidentally, her cervical spine right lateral flexion ROM was substantially limited.

Home care strategies, such as weekly walks with friends, were designed to bolster overall well-being, something that scored poorly on MYMOP2.

It could be seen that a weakness of this study is the lack of home care compliance with stretches, possibly limiting treatment outcomes. The lack of compliance may have limited the client gaining the full potential from a holistic treatment approach. An added weakness could have been the use of a tape measure rather than goniometer in outcome measurements. As with all case reports, the true weakness of this case report is the sample size of one.

Nonetheless, the strengths seen in this case report are a thorough documentation of the treatment approach, along with inclusion of nonbodywork strategies that tend to occur in massage treatment sessions but go unmentioned in formal research. By including such points in this case report, a more accurate depiction of treatment approach was presented for this case, as well as reflecting massage as practiced in the real world.

During a verbal and informal one-year follow-up over the telephone, the client reported that she has maintained the progress made during this case study, which had improved her quality of life immensely. She has not sought further massage. Outcomes of this case study support the use of conservative massage treatment in cases of TOS. Symptomatic and functional improvement of TOS has been demonstrated, but further research is needed to fully understand the effects of massage on TOS with and without pain.

ACKNOWLEDGMENTS

The author wishes to acknowledge and thank several people for their efforts and support of the current work. Special thanks are extended to The New Zealand College of Massage, particularly the author’s case report supervisor, Jill Dunn MHS (Comp Med) and clinical supervisor Sue Gillespie BHS. Niki Munk PhD, LMT, is also acknowledged and thanked for her role as publication writing mentor. Heartfelt appreciation is extended to Peter Wakefield for his unwavering support and encouragement throughout this process. A very special thank you is also extended to the participant of this case report. Finally, gratitude is extended to the Massage Therapy Foundation which recognized this report with the 2012 Gold Award in their Student Case Report Contest.

CONFLICT OF INTEREST NOTIFICATION

The author declares there are no conflicts of interest.

COPYRIGHT

Published under the [Creative Commons Attribution-NonCommercial-NoDerivs 3.0 License](https://creativecommons.org/licenses/by-nc-nd/3.0/).

REFERENCES

1. Brukner P, Khan K. *Brukner & Khan's Clinical Sports Medicine*, 3rd ed. Sydney, Australia: McGraw-Hill; 2006.
2. Watson LA, Pizzari T, Balster S. Thoracic outlet syndrome Part 1: clinical manifestations, differentiation and treatment pathways. *Man Ther*. 2009;14(6):586–595.
3. Simons DG, Travell JG, Simons, LS. *Travell and Simon's Myofascial Pain and Dysfunction: The Trigger Point Manual. Vol. 1: Upper Half of Body*, 2nd ed. Baltimore MD: Lippincott Williams & Wilkins; 1999.
4. Magee D J. *Orthopedic Physical Assessment*, 4th ed. St Louis, MO: Elsevier; 2006.
5. Duralde XA. Neurological injuries in the athlete's shoulder. *J Athl Training*. 2000;35(3):316–328.
6. Pascarelli EF, Hsu YP. Understanding work-related upper extremity disorders: clinical findings in 485 computer users, musicians, and others. *J Occup Rehabil*. 2001;11(1):1–21.
7. Bartley J, Clifton-Smith T. *Breathing Matters: a New Zealand Guide*. Auckland, New Zealand: Random House, New Zealand; 2006.
8. Ambrad-Chalela E, Thomas GI, Johansen KH. Recurrent neurogenic thoracic outlet syndrome. *Am J Surg*. 2004;187(4):505–510.
9. Clarkson HM. *Joint Movement and Function Assessment: a Research-Based Practical Guide*. Philadelphia, PA: Lippincott Williams and Wilkins; 2005.
10. Kendall FP, McCreary EK, Provance PG, Rodgers MM, Romani WA. *Muscles: Testing and Function with Posture and Pain*, 5th ed. Baltimore, MD: Lippincott Williams and Wilkins; 2005.
11. Chaitow L, DeLany J. *Clinical Applications of Neuromuscular Therapy. Vol. 1: The Upper Body*, 2nd ed. Philadelphia, PA: Churchill Livingstone Elsevier; 2008.
12. Upledger JE, Vredevoogd JD. *Craniosacral Therapy*. Seattle: Eastland Press; 1983.
13. Barnes J. *Myofascial Release: the Search for Excellence*. Malvern, PA: Myofascial Release Seminars; 1990.
14. Casley-Smith JR, Casley-Smith JR. *Modern Treatment for Lymphoedema*, 5th ed. Adelaide: The Lymphoedema Association of Australia; 1997.
15. Walker B. *The Anatomy of Stretching*. Berkeley, CA: North Atlantic Books; 2007.
16. Rapid Tables.com. *Tangent Calculator*. Available from: www.rapidtables.com/calc/math/Tan_Calculator.htm Accessed April 2014.
17. Haydock P, Sidebottom T, Watson J. *Level 1 Mathematics and Statistics Learning Workbook*. Auckland, NZ: ESA Publications Ltd.
18. Paterson C. Measuring outcomes in primary care: a patient generated measure, MYMOP, compared with the SF-36 health survey. *BMJ*. 1996;312:1016.
19. Paterson C, Britten N. In pursuit of patient-centered outcomes: a qualitative evaluation of the Measure Yourself Medical Outcome Profile. *J Health Serv Res Policy*. 2000;5(1):27–36.
20. Paterson C. Seeking the patients perspective: a qualitative assessment of EuroQol, COOP-WONCA charts and MYMOP2. *Quality Life Res*. 2004;13:871–881.
21. Centre for Academic Primary Care. *MYMOP2*. Bristol, UK: University of Bristol. Available from: www.bris.ac.uk/primaryhealthcare/resources/mymop Accessed January 2014.
22. Watson LA, Pizzari T, Balster S. Thoracic outlet syndrome Part 2: conservative management of thoracic outlet. *Man Ther*. 2010;15(4):305–314.
23. Vanti C, Natalini L, Romeo A, Tosarelli D, Pillastrini P. Conservative treatment of thoracic outlet syndrome: a review of literature. *Eur Med Phys*. 2006;42:55–70.
24. Polus BI, Kimpton AJ, Walsh AJ. Use of the measure your medical outcome profile (MYMOP) and W-BQ12 (Well-being) outcomes measures to evaluate chiropractic treatment: an observational study. *Chiropr Man Ther*. 2011;19:7.
25. Gould BE. *Gould's Pathophysiology for the Health Professions*. Philadelphia, PA: Elsevier Inc; 2006.
26. Dalton E. Strategies to address forward head postures Part one: Sacrificing complexity of movement for stability. *Massage Magazine*. 2006;Jan-Feb:99–104.
27. New Zealand Ministry of Health. Food and nutrition guidelines for healthy adults: a background paper. Available from: www.health.govt.nz/publication/food-and-nutrition-guidelines-healthy-adults-background-paper Accessed November 2011.

Corresponding author: Mary Lillias Wakefield, BHS, MT, Mt. Eden Lymphoedema and Massage Clinic, 34 Paice Ave., Mt. Eden, Auckland 1024, New Zealand

E-mail: mwakefieldmassage@gmail.com