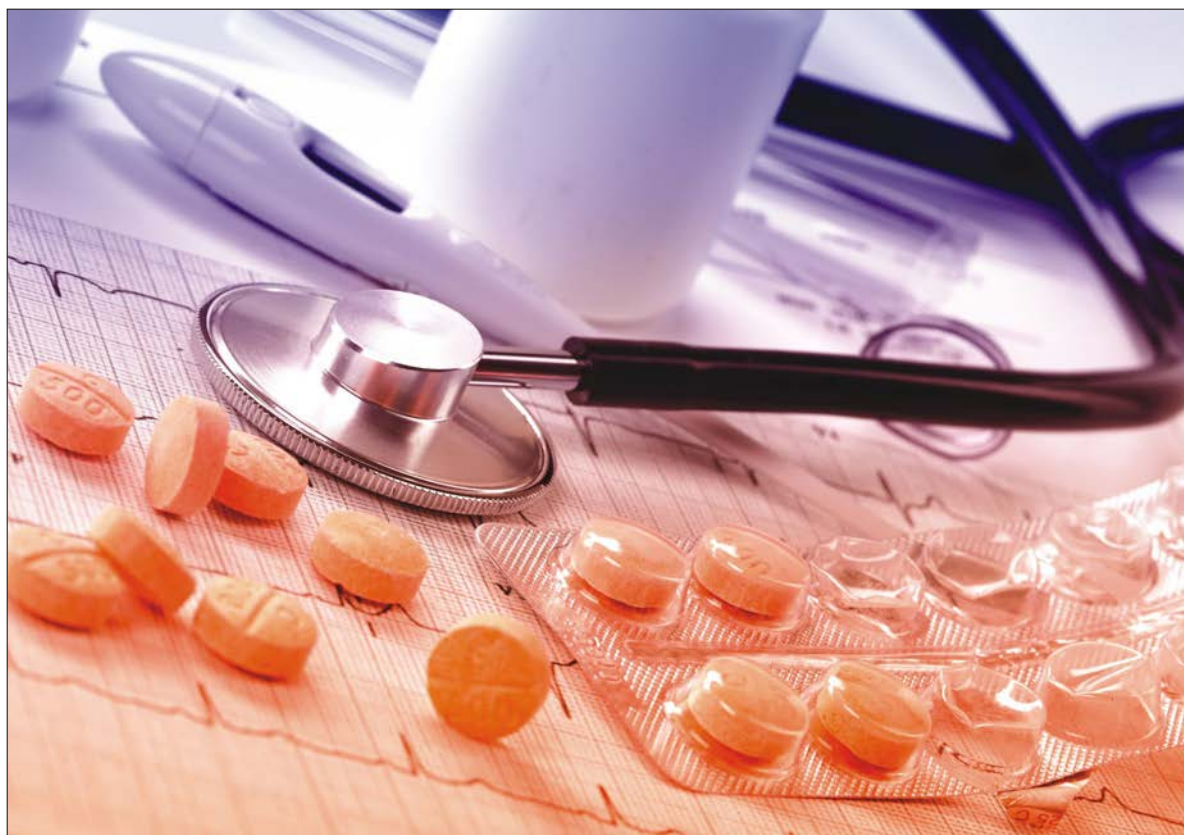



# Journal of Medical Sciences

ISSN 1682-4474

**science**  
alert

**ANSI***net*  
an open access publisher  
<http://ansinet.com>



## Research Article

# Tumor Necrosis Factor-alpha Levels and Histopathology Finding after Intervention with *Curcuma longa* Extract

<sup>1</sup>Tigor Peniel Simanjuntak, <sup>2</sup>Mochammad Hatta, <sup>3</sup>Syahrul Rauf, <sup>4</sup>Silvia Arin Prabandari, <sup>5</sup>Carmen Siagian and <sup>6</sup>Ressy Dwiyantri

<sup>1</sup>Department of Obstetrics and Gynecology, Faculty of Medicine, Christian University of Indonesia, 13630 Jakarta, Indonesia

<sup>2</sup>Molecular Biology and Immunology Laboratory, Faculty of Medicine, Hasanuddin University, 90425 Makassar, Indonesia

<sup>3</sup>Department of Obstetrics and Gynecology, Faculty of Medicine, Hasanuddin University, 90425 Makassar, Indonesia

<sup>4</sup>Primate Research Center, Bogor Agricultural Institute, 16151 Bogor, Indonesia

<sup>5</sup>Department of Clinical Nutrition, Faculty of Medicine, Christian University of Indonesia, 13630 Jakarta, Indonesia

<sup>6</sup>Department of Medical Microbiology, Faculty of Medicine, Tadulako University, Palu, Indonesia

## Abstract

**Background and Objective:** *Curcuma longa* (*C. longa*) extract has been reported as a potent anti-inflammatory agent. The main objective of this study was to evaluate the effectiveness of *Curcuma longa* extract to decrease Tumor Necrosis Factor-alpha (TNF- $\alpha$ ) and cells damage prevention in early pregnant mice with acute toxoplasmosis. **Materials and Methods:** This study evaluated 20 early pregnant mice. The mice were divided into five groups (G1-G5). G1-G4 were injected with 10 tachyzoites of *Toxoplasma gondii* and G5 was not injected. Three days later, G1 and G2 were intervened with *C. longa* extract dose of 125 mg and 500 mg kg<sup>-1</sup>/day, respectively. G3 was a positive control and G4 was a negative control. G5 was not intervened. The TNF- $\alpha$  level was examined serially (before and 3 days post tachyzoites injection and 3 and 7 days post-intervention). The placental mice were taken 7 days after intervention for histopathology examination. **Results:** The TNF- $\alpha$  level increased significantly 3 days after tachyzoites injection ( $p < 0.05$ ) and TNF- $\alpha$  level decreased significantly 3 and 7 days after *curcuma longa* intervention compared to the negative control ( $p < 0.05$ ). Hemorrhagic and necrotic cells were not found in the group intervened with *C. longa* extract but it found in the positive and negative control groups were 75 and 100%, respectively. **Conclusion:** *Curcuma longa* is effective to suppress TNF- $\alpha$  level and prevent placental cells damage in early pregnant mice with acute toxoplasmosis.

**Key words:** Cells damage, *Curcuma longa*, early pregnancy, histopathology, TNF- $\alpha$ , toxoplasmosis

**Citation:** Tigor Peniel Simanjuntak, Mochammad Hatta, Syahrul Rauf, Silvia Arin Prabandari, Carmen Siagian and Ressay Dwiyantri, 2018. Tumor Necrosis factor-alpha levels and histopathology finding after intervention with *Curcuma longa* extract. J. Med. Sci., 18: 56-62.

**Corresponding Author:** Mochammad Hatta, Molecular Biology and Immunology Laboratory, Faculty of Medicine, Hasanuddin University, 90425 Makassar, Indonesia

**Copyright:** © 2018 Tigor Peniel Simanjuntak *et al.* This is an open access article distributed under the terms of the creative commons attribution License, which permits unrestricted use, distribution and reproduction in any medium, provided the original author and source are credited.

**Competing Interest:** The authors have declared that no competing interest exists.

**Data Availability:** All relevant data are within the paper and its supporting information files.

## INTRODUCTION

Toxoplasmosis is a zoonotic disease caused by *Toxoplasma gondii*<sup>1,2</sup>. It can cause abortion if the infection happens during early pregnancy<sup>3,4</sup>. The abortion caused by *Toxoplasma gondii* (*T. gondii*) not only caused by direct effect of parasites but can occur due to excessive pro-inflammatory reaction. *Toxoplasma gondii* will trigger antibody (anti-toxoplasma IgG-IgM anti-body)<sup>5,6</sup> and cellular immunity (TNF- $\alpha$ )<sup>7,8</sup>. The excessive TNF- $\alpha$  levels reported can cause intravascular thrombosis, ischemic and necrotic cells. The increased of TNF- $\alpha$  levels due to *Toxoplasma gondii* infection in early pregnancy can lead to abortion<sup>9</sup>.

Serranti *et al.*<sup>10</sup> reported that until now, there has been no ideal drug for toxoplasmosis therapy in pregnant women<sup>10</sup>. Spiramycin is still the drug of choice but it has been proven unable to eradicate infection in the fetus. Early pregnancy with acute *T. gondii* infection may be treated with spiramycin<sup>11</sup>. The therapy with spiramycin will kill the parasite because it works as a bactericidal but spiramycin unable to inhibit the inflammatory process. The abortion caused by *T. gondii* infection is not only due to the direct effects of the parasite but it can also result from excessive inflammatory responses leading to abortion<sup>9,12</sup>.

*Curcuma longa* has been shown to have potent anti-inflammatory<sup>13-15</sup> and anti-bacterial, anti-parasites but more likely to be anti-inflammatory<sup>15-17</sup>. Curcumin is the main content of *C. longa*, it has been shown to suppress TNF- $\alpha$ <sup>13-15</sup>. There was no study conducted which evaluate the *C. longa* effect on the toxoplasmosis<sup>18</sup>. Hence, this study aimed to determine the effectiveness of *C. longa* extract compared to spiramycin, especially in preventing cell damage on early pregnant mice with acute toxoplasmosis by analyzing levels of TNF- $\alpha$  and histopathology examination of placental tissue.

## MATERIALS AND METHODS

This study was carried out from February, 2017-September, 2017 in Molecular Biology and Immunology Laboratory, Faculty of Medicine, Hasanuddin University, Makassar, Indonesia.

**Subjects:** The study was conducted on 20 Balb/c female mice that were conditioned into 1-3 day(s) pregnancy that fulfill inclusion criteria (mice age 11-13 weeks, weigh 16- 20g, active movement, no physical defect and willing to eat and drink). The early pregnant mice were divided into five groups (G1-G5) randomly, 4 mice each group. G1-G4 were injected with

10 tachyzoites of *T. gondii* RH strain intra-peritoneal and G5 without infection. At the end of the study, the mice were sacrificed then buried in specified places. This research has been approved by the animal ethics research committee of the Faculty of Medicine, University of Hasanuddin, Makassar, Indonesia (Number: 535/114.8.4.5.31/PP36-KOMITEK/20160), dated 2 May, 2016.

**Preparation and modeling of experimental animals:** Mice were conditioned into pregnancy by bringing together female and male mice in one cage. Every morning, signs of pregnancy were evaluated in the form of a plug in the vagina (reddish and swollen vagina). If plug is found, the mice were considered pregnant and the gestational age is day 0. The *C. longa* extract use was obtained by maceration and the curcuminoid compound was evaluated using KLT densitometry and spectrophotometry. Curcuminoid level in *C. longa* extract obtained were at 25.5%. Tachyzoites used in this study were from the *T. gondii* strain RH (strain pathogen; SRA: ERS670498).

**Intervention of experimental animals:** Three days after injection of tachyzoites, G1 and G2 were each given *C. longa* extract dose of 125 and 500 mg kg<sup>-1</sup>/day, respectively, G3 (positive control) was given spiramycin dose of 60 mg kg<sup>-1</sup>/day and G4 (negative control/placebo) was given 0.2 mL distilled water. Each intervention was administered orally using cannulas for 7 days. G5 was not infected nor intervened with.

**Taking and examination of sample:** Blood samples were taken from the tail vein serially (1 day before tachyzoites injection, 3 days after tachyzoites injection, 3 and 7 days after the intervention). Examination of anti-toxoplasma IgG-IgM antibody levels and TNF- $\alpha$  level were examined using Enzyme-Linked Immunosorbent Assay (ELISA).

Seven days after the intervention, the mice were sacrificed by breaking the cervical vertebrae and then surgery was performed to remove the uterus containing the placenta. Examination of placental histopathology in all samples was done to study and assessed the degree of damage of placental tissue in the form of the congestive capillary, extracellular edema, hemorrhagic and necrotic cells, all of which were histopathology findings.

**Statistical analysis:** The data obtained were statistically analyzed using paired t-test to determine the TNF- $\alpha$  level before and after intervention. One-way ANOVA test was

conducted to determine the difference of TNF- $\alpha$  level between the five groups. Histopathology presentation was reported in percentage and chi-square test was performed to identify cells damage between groups. The  $p < 0.05$  is used.

### RESULTS

The results of TNF- $\alpha$  level are reported in Table 1. The TNF- $\alpha$  level increased significantly 3 days after tachyzoites injection ( $p < 0.05$ ). Three and 7 days after intervention with

*C. longa* extract dose of 125 mg kg<sup>-1</sup>/day, *C. longa* dose of 500 mg kg<sup>-1</sup>/day and spiramycin dose of 60 mg kg<sup>-1</sup>/day, the TNF- $\alpha$  level decreased significantly ( $p < 0.05$ ) (Table 2). The decrease of TNF- $\alpha$  level among the three groups (G1-G3) was not significant (Table 3 and 4). The TNF- $\alpha$  level in negative control (G4) increased significantly during the study, while in the non-infected group (G5), TNF- $\alpha$  level during the study fluctuated insignificantly ( $p > 0.05$ ) (Table 2).

The results of the histopathology presentation are shown in Fig. 1. Hemorrhagic and necrotic cells were not present

Table 1: TNF- $\alpha$  level before and after the injection of tachyzoites and post-intervention

Groups (G)	TNF- $\alpha$ level (pg mL <sup>-1</sup> )			
	A	B	C	D
G1	36.738 $\pm$ 0.015	301.708 $\pm$ 0.025	130.230 $\pm$ 0.013	81.976 $\pm$ 0.010
G2	31.310 $\pm$ 0.013	285.244 $\pm$ 0.018	144.102 $\pm$ 0.013	88.610 $\pm$ 0.015
G3	38.219 $\pm$ 0.013	305.425 $\pm$ 0.017	137.139 $\pm$ 0.013	85.870 $\pm$ 0.013
G4	35.814 $\pm$ 0.013	292.432 $\pm$ 0.020	352.750 $\pm$ 0.019	558.436 $\pm$ 0.020
G5	36.517 $\pm$ 0.008	36.517 $\pm$ 0.007	34.410 $\pm$ 0.010	36.517 $\pm$ 0.005

Groups G1-G4: Early pregnant mice were injected tachyzoites. Interventions: G1 and G2 (mice given *C. longa* extract dose of 125 and 500 mg kg<sup>-1</sup>/day, respectively), G3 (positive control and G4 (negative control/placebo), each group is administered for 7 days, G5 (normal group). Blood sampling times: A (1 day before tachyzoites injection), B (3 days after tachyzoites injection), C (3 days after the intervention) and D (7 days after the intervention)

Table 2: Statistic analysis of TNF- $\alpha$  levels before and after intervention

Groups	Pairs	Mean	Standard deviation	Standard error mean	95% confidence interval of the difference		T	df	Significant (2-tailed)
					Lower	Upper			
<b>G1</b>									
1	TNFA-TNFB	-244.886	29.516	14.758	-291.853	-197.918	-16.593	3	0.000
2	TNFB-TNFC	151.395	32.985	16.492	98.907	203.882	9.179	3	0.003
3	TNFB-TNFD	199.648	32.749	16.374	147.537	251.759	12.193	3	0.001
4	TNFC-TNFD	48.253	33.948	16.974	-5.766	102.273	2.843	3	0.066
<b>G2</b>									
1	TNFA-TNFB	-253.934	23.004	11.502	-290.539	-217.328	-22.076	3	0.000
2	TNFB-TNFC	141.141	15.573	7.786	116.360	165.922	18.126	3	0.000
3	TNFB-TNFD	196.633	16.540	8.270	170.314	222.951	23.777	3	0.000
4	TNFC-TNFD	55.491	12.917	6.458	34.936	76.046	8.592	3	0.003
<b>G3</b>									
1	TNFA-TNFB	-267.206	38.065	19.032	-327.778	-206.635	-14.039	3	0.001
2	TNFB-TNFC	168.286	26.750	13.370	125.719	210.852	12.582	3	0.001
3	TNFB-TNFD	219.555	3.409	1.704	214.130	224.981	128.784	3	0.000
4	TNFC-TNFD	51.269	30.029	15.010	3.485	99.053	3.415	3	0.042
<b>G4</b>									
1	TNFA-TNFB	-256.617	43.327	21.663	-325.560	-187.673	-11.846	3	0.001
2	TNFB-TNFC	-60.318	31.887	15.943	-111.057	-9.578	-3.783	3	0.032
3	TNFB-TNFD	-266.003	58.518	29.259	-359.118	-172.888	-9.091	3	0.003
4	TNFC-TNFD	-205.685	57.951	28.975	-297.899	-113.470	-7.098	3	0.006
<b>G5</b>									
1	TNFA-TNFB	0	5.131	2.565	-8.164	8.166	0	3	1.000
2	TNFB-TNFC	2.107	5.319	2.659	-6.356	10.571	0.792	3	0.486
3	TNFB-TNFD	0	7.255	3.627	-11.544	11.544	0	3	1000
4	TNFC-TNFD	-2.107	3.535	1.767	-7.733	3.518	-1.192	3	0.319

Groups: G1 and G2 (mice given *C. longa* extract dose of 125 and 500 mg kg<sup>-1</sup>/day respectively), G3 (positive control), G4 (negative control/placebo), G5 (Normal group). Tumor Necrosis Factor (TNF), TNFA (TNF- $\alpha$  levels 1 day before tachyzoites injection), TNFB (TNF- $\alpha$  levels 3 days after tachyzoites injection), TNFC (TNF- $\alpha$  days 3 after the intervention) and TNFD (TNF- $\alpha$  levels 7 days after the intervention) ( $p < 0.05$ )

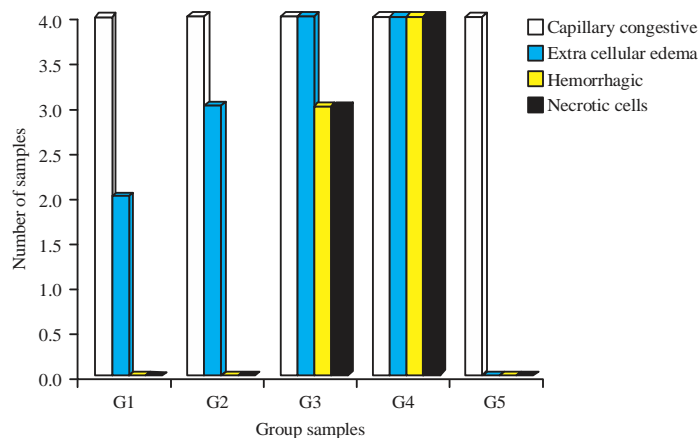


Fig. 1: Histopathology presentation of placental tissue sort by group (G1-G5). G1-G4 were injected 10 tachyzoites to intra-peritoneal space. Interventions: G1 and G2 (mice given *C. longa* extract dose of 125 and 500 mg kg<sup>-1</sup>/day respectively), G3 (positive control), G4 (negative control/placebo), 7days each and G5 (normal group)

Table 3: Statistic analysis of TNF-α levels after 3 days intervention among five groups

Dependent variable	(I) Groups	(J) Groups	Mean difference (I-J)	Standard error	Significant	95% confidence interval	
						Lower bound	Upper bound
TNFC	Curcumin (125 mg)	Curcumin (500 mg)	-13.873000	14.421981	0.868	-58.40699	30.66099
		Spiramycin (60 mg)	-6.909750	14.421981	0.988	-51.44374	37.62424
		Placebo	-222.521000*	14.421981	0.000	-267.05499	-177.98701
		Normal	95.819500*	14.421981	0.000	51.28551	140.35349
	Curcumin (500 mg)	Curcumin (125 mg)	13.873000	14.421981	0.868	-30.66099	58.40699
		Spiramycin (60 mg)	6.963250	14.421981	0.988	-37.57074	51.49724
		Placebo	-208.648000*	14.421981	0.000	-253.18199	-164.11401
		Normal	109.692500*	14.421981	0.000	65.15851	154.22649
	Spiramycin (60 mg)	Curcumin (125 mg)	6.909750	14.421981	0.988	-37.62424	51.44374
		Curcumin (500 mg)	-6.963250	14.421981	0.988	-51.49724	37.57074
		Placebo	-215.611250*	14.421981	0.000	-260.14524	-171.07726
		Normal	102.729250*	14.421981	0.000	58.19526	147.26324
Placebo	Curcumin (125 mg)	222.521000*	14.421981	0.000	177.98701	267.05499	
	Curcumin (500 mg)	208.648000*	14.421981	0.000	164.11401	253.18199	
	Spiramycin (60 mg)	215.611250*	14.421981	0.000	171.07726	260.14524	
	Normal	318.340500*	14.421981	0.000	273.80651	362.87449	
Normal (no intervention)	Curcumin (125 mg)	-95.819500*	14.421981	0.000	-140.35349	-51.28551	
	Curcumin (500 mg)	-109.692500*	14.421981	0.000	-154.22649	-65.15851	
	Spiramycin (60 mg)	-102.729250*	14.421981	0.000	-147.26324	-58.19526	
	Placebo	-318.340500*	14.421981	0.000	-362.87449	-273.80651	

TNFC: TNF-α levels after 3 days intervention, p<0.05

in the group intervened with *C. longa* extract dose of 125 mg kg<sup>-1</sup>/day and dose of 500 mg kg<sup>-1</sup>/day but in the group intervened with spiramycin, 75% of the samples obtained had hemorrhagic and necrotic cells and in the negative control group, the hemorrhagic and necrotic features were obtained in all samples (100%). The occurrence of hemorrhagic and necrotic cells between *C. longa* and spiramycin intervention were significantly different (p<0.05).

## DISCUSSION

In this study, 3 days after the injection of tachyzoites, the anti-toxoplasma IgG-IgM antibody levels increased significantly. Increased levels of anti-toxoplasma IgG-IgM antibodies in this study proves that mice in this study have occurred acute toxoplasmosis. Simanjuntak *et al.*<sup>6</sup> reported that injecting 10 tachyzoites intra-peritoneal in mice during early pregnancy caused the anti-toxoplasma IgM antibody

Table 4: Statistic analysis of TNF- $\alpha$  levels after 7 days intervention among five groups

Dependent variable	(I) groups	(J) groups	Mean difference (I-J)	Standard error	Significant	95% confidence interval	
						Lower bound	Upper bound
TNFD	Curcumin (125 mg)	Curcumin (500 mg)	-6.635000	16.050344	0.993	-56.19725	42.92725
		Spiramycin (60 mg)	-3.893750	16.050344	0.999	-53.45600	45.66850
		Placebo	-476.459750*	16.050344	0.000	-526.02200	-426.89750
		Normal	45.458500	16.050344	0.080	-4.10375	95.02075
	Curcumin (500 mg)	Curcumin (125 mg)	6.635000	16.050344	0.993	-42.92725	56.19725
		Spiramycin (60 mg)	2.741250	16.050344	1.000	-46.82100	52.30350
		Placebo	-469.824750*	16.050344	0.000	-519.38700	-420.26250
		Normal	52.093500*	16.050344	0.037	2.53125	101.65575
	Spiramycin (60 mg)	Curcumin (125 mg)	3.893750	16.050344	0.999	-45.66850	53.45600
		Curcumin (500 mg)	-2.741250	16.050344	1.000	-52.30350	46.82100
		Placebo	-472.566000*	16.050344	0.000	-522.12825	-423.00375
		Normal	49.352250	16.050344	0.051	-0.21000	98.91450
	Placebo	Curcumin (125 mg)	476.459750*	16.050344	0.000	426.89750	526.02200
		Curcumin (500 mg)	469.824750*	16.050344	0.000	420.26250	519.38700
		Spiramycin (60 mg)	472.566000*	16.050344	0.000	423.00375	522.12825
		Normal	521.918250*	16.050344	0.000	472.35600	571.48050
	Normal (No intervention)	Curcumin (125 mg)	-45.458500	16.050344	0.080	-95.02075	4.10375
		Curcumin (500 mg)	-52.093500*	16.050344	0.037	-101.65575	-2.53125
		Spiramycin (60 mg)	-49.352250	16.050344	0.051	-98.91450	0.21000
		Placebo	-521.918250*	16.050344	0.000	-571.48050	-472.35600

TNFD: TNF- $\alpha$  levels after 7 days intervention,  $p < 0.05$

level increased significantly 24 h after the tachyzoites injection and IgG antibody level increased significantly 72 h after the injection. The elevated level of anti-toxoplasma IgM antibody after *T. gondii* infection is a marker that can be considered as an acute infection<sup>19,20</sup>.

In this study, TNF- $\alpha$  levels increased significantly after 3 days injections of 10 tachyzoites *T. gondii* strains of RH. Some previous investigators also reported elevated TNF- $\alpha$  levels in *T. gondii*<sup>21-24</sup>. Increased level of TNF- $\alpha$  commences with the detection of toxoplasma parasite protein/glycosylphosphatidylinositol (GPI)-anchored by toll-like receptors (TLRs). TLRs especially TLR2 and TLR4 that are activated by GPI will trigger macrophages to produce TNF- $\alpha$  and IL-1221. The *T. gondii* infection also specifically stimulates TNF type 1 receptors (p55), so TNF- $\alpha$  can work as a pro-inflammatory<sup>25</sup>.

Seven days after intervention with *C. longa* extract, the TNF- $\alpha$  levels decreased significantly compared with the negative control group. The decreased in levels of TNF- $\alpha$  in this study occurred because curcumin which is the main component of *C. longa*, can inhibit the production and action of TNF- $\alpha$  in various ways<sup>15</sup>. It primarily suppresses the expression of TNF- $\alpha$  through the down-regulation of NF- $\kappa$ B, causing TLR2 and TLR 4 being unable to induce macrophages to produce TNF- $\alpha$ <sup>25</sup>. Curcumin will also bind to myeloid differentiation protein-2 (MD-2). This MD2-curcumin compound will inhibit MyD 88, consequently inhibiting TLR2, TLR 4, which results in inhibiting TLRs that stimulates macrophages to produce TNF- $\alpha$ <sup>26</sup>.

The excessive TNF- $\alpha$  level can cause cells damage such as ischemic, hemorrhagic and necrotic cells<sup>9</sup>. If the TNF- $\alpha$  excess levels happen in early pregnancy it can cause abortion<sup>9</sup>. This study discovered that hemorrhagic and necrotic cells is not found in intervention groups with *C. longa* extract dose of 125 and 500 mg kg<sup>-1</sup>/day but in intervention groups with spiramycin dose of 60 mg<sup>-1</sup>/day (positive control), it was found 75% and intervention groups with 0.2 mL distilled water it was found 100%. The different incidence of hemorrhagic and necrotic cells among groups intervened with *C. longa* and spiramycin although TNF- $\alpha$  levels in these two groups did not differ significantly, the researchers suspected to be associated with antioxidant effects possessed by curcuma but need to be further proven.

## CONCLUSION

*Curcuma longa* extract dose of 125 mg kg<sup>-1</sup>/day for 7 days was effective to decrease the TNF- $\alpha$  levels and it was effective to prevent the hemorrhagic and necrotic cells of placental tissue of early pregnant mice with acute toxoplasmosis. *Curcuma longa* extract dose of 125 mg kg<sup>-1</sup>/day can be considered as an alternative therapy in early pregnant women with acute toxoplasmosis but further research is needed for the effectiveness and toxicity of the first trimester pregnancy.

## SIGNIFICANCE STATEMENT

This study discovers that *C. longa* extract dose of 125 mg kg<sup>-1</sup>/day during 7 days effective to decrease TNF- $\alpha$  level and to prevent cells damage placental tissue in early pregnancy with acute toxoplasmosis. This investigation will facilitate the researchers to obtain an alternative drug for early pregnancy with acute toxoplasmosis that many researchers were not able to explore.

## ACKNOWLEDGMENTS

We thanks Prof. Irawan Yusuf, Dr. Andi Mardiah Tahir, Prof. Nurpudji A. Taslim, Prof. Nusratuddin, Dr. Burhanuddin, Hasnawati Ph.D and the laboratory staffs of Molecular Biology and Immunology Laboratory, Faculty of Medicine, Hasanuddin University, Makassar and also to Phytochemistry Laboratory, Faculty of Pharmacy, Hasanuddin, Makassar, for their help in this study.

## REFERENCES

1. Tonter, A.M., A.R. Heckerth and L.M. Weiss, 2000. *Toxoplasma gondii*: From animal to human. Int. J. Parasitol., 30: 1217-1258.
2. Furtado, J.M., J.R. Smith, R. Belfort, Jr., D. Gattey and K.L. Winthrop, 2011. Toxoplasmosis: A global threat. J. Global Infect. Dis., 3: 281-284.
3. Cunningham, F.G., K.J. Leveno and S.L. Bloom, 2014. Infectious Diseases: Toxoplasmosis. In: Williams Obstetrics, Cunningham, F.G., K.J. Leveno, S.L. Bloom, C.Y. Spong and J.S. Dashe *et al.* (Eds.). 24th Edn., Chapter 64, McGraw-Hill Education, New York, USA., ISBN-13: 978-0071798938, pp: 1254-1256.
4. Alvarado-Esquivel, C., S.J. Pacheco-Vega, J. Hernandez-Tinoco, M.M. Centeno-Tinoco and I. Beristain-Garcia *et al.*, 2014. Miscarriage history and *Toxoplasma gondii* infection: A cross-sectional study in women in Durango city, Mexico. Eur. J. Microbiol. Immunol., 4: 117-122.
5. Villard, O., B. Cimon, C. L'Ollivier, H. Fricker-Hidalgo and N. Godineau *et al.*, 2016. Serological diagnosis of *Toxoplasma gondii* infection. Diagn. Microbiol. Infect. Dis., 84: 22-33.
6. Simanjuntak, T.P., M. Hatta, R.H. Sirait, M.B. Karo and L.I. Sirait *et al.*, 2017. Analysis concentration of *Toxoplasma gondii* on anti-toxoplasma IgG-IgM antibody levels and the outcomes of pregnancy in mice Balb/c. Open J. Obstet. Gynecol., 7: 281-289.
7. Belloni, A., I. Villena, J.E. Gomez, H. Pelloux and A. Bonhomme *et al.*, 2003. Regulation of tumor necrosis factor alpha and its specific receptors during *Toxoplasma gondii* infection in human monocytic cells. Parasitol. Res., 89: 207-213.
8. Chaouat, G., N. Ledee-Bataille, S. Dubanchet, S. Zourbas, O. Sandra and J. Martal, 2004. TH1/TH2 paradigm in pregnancy: Paradigm lost? Int. Arch. Allergy Immunol., 134: 93-119.
9. Clark, D.A., J.W. Ding, G. Chaouat, C.B. Coulam, C. August and G.A. Levy, 1999. The emerging role of immunoregulation of fibrinogen related procoagulant Fgl2 in the success or spontaneous abortion of early pregnancy in mice and humans. Am. J. Reprod. Immunol., 42: 37-43.
10. Serranti, D., D. Buonsenso and P. Valentini, 2011. Congenital toxoplasmosis treatment. Eur. Rev. Med. Pharmacol. Sci., 15: 193-198.
11. Valentini, P., D. Buonsenso, G. Barone, D. Serranti and R. Calzedda *et al.*, 2015. Spiramycin/cotrimoxazole versus pyrimethamine/sulfonamide and spiramycin alone for the treatment of toxoplasmosis in pregnancy. J. Perinatol., 35: 90-94.
12. Haider, S. and M. Knofler, 2009. Human tumour necrosis factor: Physiological and pathological roles in placenta and endometrium. Placenta, 30: 111-123.
13. Aggarwal, B.B. and K.B. Harikumar, 2009. Potential therapeutic effects of curcumin, the anti-inflammatory agent, against neurodegenerative, cardiovascular, pulmonary, metabolic, autoimmune and neoplastic diseases. Int. J. Biochem. Cell Biol., 41: 40-59.
14. Guimaraes, M.R., L.S. Coimbra, S.G. de Aquino, L.C. Spolidorio, K.L. Kirkwood and C. Rossa, 2011. Potent anti inflammatory effects of systemically administered curcumin modulate periodontal disease *in vivo*. J. Periodontal Res., 46: 269-279.
15. Aggarwal, B.B., S.C. Gupta and B. Sung, 2013. Curcumin: An orally bioavailable blocker of TNF and other pro-inflammatory biomarkers. Br. J. Pharmacol., 169: 1672-1692.
16. Moghadamtousi, S.Z., H. Abdul Kadir, P. Hassandarvish, H. Tajik, S. Abu Bakar and K. Zandi, 2014. A review on antibacterial, antiviral and antifungal activity of curcumin. BioMed Res. Int. 10.1155/2014/186864.
17. Tyagi, P., M. Singh, H. Kumari, A. Kumari and K. Mukhopadhyay, 2015. Bactericidal activity of curcumin I is associated with damaging of bacterial membrane. PLoS One, Vol. 10. 10.1371/journal.pone.0121313.
18. Grujic, J., O. Djurkovic-Djakovic, A. Nikolic, I. Klun and B. Bobic, 2005. Effectiveness of spiramycin in murine models of acute and chronic toxoplasmosis. Int. J. Antimicrob. Agents, 25: 226-230.
19. Liu, Q., Z.D. Wang, S.Y. Huang and X.Q. Zhu, 2015. Diagnosis of toxoplasmosis and typing of *Toxoplasma gondii*. Parasit. Vect., Vol. 8. 10.1186/s13071-015-0902-6.
20. Begeman, I.J., J. Lykins, Y. Zhou, B.S. Lai and P. Levigne *et al.*, 2017. Point-of-care testing for *Toxoplasma gondii* IgG/IgM using *Toxoplasma* ICT IgG-IgM test with sera from the United States and implications for developing countries. PLoS Neglect. Trop. Dis., Vol. 11. 10.1371/journal.pntd.0005670.

21. Guo, Y.Z., P. He and A.M. Feng, 2017. Effect of curcumin on expressions of NF- $\kappa$ Bp65, TNF- $\alpha$  and IL-8 in placental tissue of premature birth of infected mice. *Asian Pac. J. Trop. Med.*, 10: 175-178.
22. Prigione, I., S. Chiesa, P. Taverna, R. Ceccarelli and R. Frulio *et al.*, 2006. T cell mediated immune responses to *Toxoplasma gondii* in pregnant women with primary toxoplasmosis. *Microbes Infect.*, 8: 552-560.
23. Krishnan, L., L.J. Guilbert, T.G. Wegmann, M. Belosevic and T.R. Mosmann, 1996. T helper 1 response against *Leishmania major* in pregnant C57BL/6 mice increases implantation failure and fetal resorptions. Correlation with increased IFN-gamma and TNF and reduced IL-10 production by placental cells. *J. Immunol.*, 156: 653-662.
24. Zenclussen, A.C., K. Gerlof, M.L. Zenclussen, A. Sollwedel and A.Z. Bertoja *et al.*, 2005. Abnormal T-cell reactivity against paternal antigens in spontaneous abortion: Adoptive transfer of pregnancy-induced CD4<sup>+</sup>CD25<sup>+</sup> T regulatory cells prevents fetal rejection in a murine abortion model. *Am. J. Pathol.*, 166: 811-822.
25. Singh, S. and B.B. Aggarwal, 1995. Activation of transcription factor NF- $\kappa$ B is suppressed by curcumin (diferuloylmethane). *J. Biol. Chem.*, 270: 24995-25000.
26. Tu, C.T., B. Han, Q.Y. Yao, Y.A. Zhang, H.C. Liu and S.C. Zhang, 2012. Curcumin attenuates Concanavalin A-induced liver injury in mice by inhibition of Toll-like receptor (TLR) 2, TLR4 and TLR9 expression. *Int. Immunopharmacol.*, 12: 151-157.