

# The Progression of Craniofacial Growth and Development: An Anthropological Study Applicable to the Forensic and Identity Sciences

A. Midori Albert\* and Charissa L. Wright

*Department of Anthropology, University of North Carolina Wilmington, 601 S. College Road, Wilmington, NC 28403-5944*

**Abstract:** The purpose of this study is to provide a description of the progression of craniofacial growth and development from infancy through adulthood. Whereas much of the diverse published literature provides information specific to separate dimensions and or components of the craniofacial skeleton, unique to particular populations, our aim, through compiling these disparate findings, was to capture and convey the overall appearance of the craniofacial complex at various ages. This was accomplished through an intensive review and amalgamation of the published literature, mostly from the recent five years, which addresses various aspects of craniofacial growth and development. Key findings suggest that at birth, craniofacial bones have attained approximately 45% of their total growth.

Most rapid growth is complete by age 7 with facial development largely complete (82 to 92%) by age 5. Specific sexual dimorphism (shape differences in females and males) begins to appear around age 9. Final size maturity is attained between 13 and 15 years in females and 17 and 25 years in males. Although technically craniofacial growth is continuous, after 20 years of age the rate of growth appears insignificant. These findings, and this integrated anthropological research approach provides essential information for individuals working at the frontier of forensic science technologies inclusive of age progression, age regression, and facial identification.

**Keywords:** Craniofacial growth, Craniofacial development, Facial skeleton growth changes, Facial identification, Facial age progression.

## INTRODUCTION

Previous studies encompassing variation within the craniofacial complex tended to focus on separate components of the face. The purpose of this article is to provide a holistic description of how the juvenile craniofacial complex changes from infancy to adulthood that includes separate components *in relation to the entirety of the face*. The specific aim of this research was to identify and provide an in-depth understanding of key features of juvenile facial morphological growth and development in order to help researchers in the forensic and identity sciences in the areas of computer automated age-progression, age-regression, and face recognition techniques. This work demonstrates the applicability of an anthropological inquiry-based approach to the fields of forensic science and technology, which continue to expand globally.

The craniofacial complex was divided into seven singular features (mandible, maxilla, orbit, nasal, cranial width, facial height, and forehead) and then researched as a comprehensive composite. Provided here is the essence of a review of the literature and

subsequent consolidation of information on the growth of several facial components relative to the entirety of the face, parsed and distilled into a single compendium. Characteristics of juvenile craniofacial maturation are explained and summarized from birth through maturation in females and males, with an attempt to create an average craniofacial complex that spans ethnicities.

## METHODS

Growth and development information was compiled according to the Cochrane Criteria, which dictates formulating myriad key word phrases, casting numerous wide search “nets,” retrieving data, and synthesizing findings to aid in reducing bias [1].

The literature review consisted of 46 search iterations using the ScienceDirect database search engine. These searches yielded 4,238 publications between the years 2010-2015 and resulted in 81 sources that were most potentially relevant. Additionally, there were seven sources that were subsequently found, in various references, to contain pertinent data directly related to this research inquiry; and although they pre-date 2010, they were included as they aided in rounding out the overall findings. Thus, of the 88 sources reviewed and analyzed, 36 final sources provided the most complete, recent and best

\*Address correspondence to this author at the Department of Anthropology, University of North Carolina Wilmington, 601 S. College Road, Wilmington, NC 28403-5944; Tel: (910) 962-7078; Fax: (910) 962-3543; E-mail: [albertm@uncw.edu](mailto:albertm@uncw.edu)

information for a thorough understanding of craniofacial morphological growth and development from birth through maturation.

Since exact time of adult maturation is considerably variable across individuals, components, and in some cases never complete, 18 years was used as the age of maturation in most of the articles that were searched through and thus continued in this paper. As such, "adult percentage" is herein defined as the measurements taken at an average age of 18 years.

The published literature on juvenile craniofacial growth and development is characterized by studies predominantly reporting on specific and expansive dimensions, sizes, and percentages of *separate* craniofacial components by nature of the focus of the research inquiry, such as corrective or plastic reconstructive surgery related to developmental anomalies, trauma, and or pathology. Thus, each focalized segment of craniofacial complex was further studied on an individual level to complete the greater composite understanding of normal growth and development.

As previously mentioned, the craniofacial complex was divided into seven separate features based on results of the literature searches: mandible, maxilla, orbit, nasal dimensions, cranial width, facial height, and forehead. Regarding the mandible, several studies discussed its growth as a whole [2-6], and additional studies revealed information according to five separate aspects: mandibular width [2, 4, 7-11], mandibular depth [3-5, 7, 8, 12-14], mandibular body length [3-5, 9, 15], ramus height [5, 9, 12, 16], and mandibular body height [7, 12, 17].

The maxilla was researched as a whole [2, 4, 8, 13, 18] and also examined as five separate dimensions: bizygomatic width [2, 4, 7, 10-11], maxillary width [8-10, 13], antero-posterior palate growth [8, 13], vault depth [8, 13, 19], and vertical growth [4, 7, 20-22].

The orbits were researched as a whole [4, 23-24] and as four different features: orbital height [4, 25], intercanthal width [4, 21, 25, 26], orbital width [9, 12, 25-26], and orbital volume [4, 23, 27, 28].

A search for publications on the nasal aspect of craniofacial growth and development yielded limited published studies; and due to its petite nature was researched as a singular component [29-31]. The last three features (*i.e.*, cranial width, face height, and forehead) were first visualized altogether under the

umbrella-term of facial planes [10, 16] and then split into their respective factions: cranial width [2, 4, 10, 12], face height (which also has references in mandibular body height and maxillary vertical growth) [2, 7, 11, 21, 22, 32, 33], and forehead [12, 21].

Data (*e.g.*, dimensions, sizes, percentages, etc. of craniofacial features at various ages, in both sexes, across populations) were mined for each reference among the final 38 sources deemed pertinent to the aim of the study, which was to provide a *synergistic* (*i.e.*, integrated) description of craniofacial growth and development. The data were evaluated, grouped, and assessed by feature/dimension, age, sex, and population. From this analysis a synergistic description, in narrative form, of craniofacial growth and development was established. The next section conveys the characteristics and progressive changes of craniofacial growth and development from birth through adulthood.

## RESULTS

At birth, craniofacial bones have attained approximately 45% of their total growth [2]. Compared to an adult skull, a newborn has a large cranial vault and enormous eye orbits in relation to the diminutive mandible and maxilla in concordance with the swift growth of the brain and eyes; in fact, early development is concomitant with the surrounding tissues in order to accommodate them [4, 16, 24, 32]. The cranial vault experiences its most rapid growth in the first year of life with a velocity plateau until area growth is complete between ages 5 and 7 years [4]. This is enforced by the rapidity of head circumference enlargement with 86% of growth complete at age 1 year and attaining 94% by around age 5 years [4]. The cranial volume is much larger in comparison to facial volume early on, but as age progresses the ratios of cranial volume to facial volume decrease [24]. The face continues to expand during primary tooth eruption with an even greater increase in length during the mixed dentition stages, with the face lengthening twice comparatively to width between the ages of 4 and 13 years [20, 24].

Additionally, the mandible and maxilla have both reached approximately 85% of their adult size at age 5 years. To be sure, most rapid growth is complete by age 7 years with facial development largely complete (82 to 92%) by age 5 years [7, 27, 34]. Concordantly, at age 7 years, the craniofacial bones have reached around 70%; at this age, ideally, the soft tissue facial profile measured from the Glabella to the Subnasale

(midway between the eyebrows to below the nose) is equal in length to the Subnasale to the Menton (below the nose to the chin) [2]. Specific sexual dimorphism (shape differences in females and males) begins to appear around age 9 years [11]. Passive growth is from around age 7 years until puberty [34]. Puberty is around 10 to 12 years old in females and 12 to 14 years in males; this time period is marked by an increased growth velocity that peaks about two years after onset [2]. For growth spurts, males are found to lag behind females by one to three years yet be larger in their dimensions, especially after puberty [10-11]. Although technically craniofacial growth is continuous, after 20 years of age the rate of growth appears insignificant [11, 32].

Children's faces do not merely grow in volume to attain adult morphology and size; they are more than a small-scale adult, even though at age 3 years there is already a significant correlation to their adult morphology [13, 34]. The brain case is rapidly expanded after birth followed by the mid-facial projection and elongation [2]. Children's faces flatten, deepen, widen, and lengthen to achieve adult status [2, 16, 28, 34-35]. The adult length is about twice the length of the child's face [2]. The total transverse growth reaches maturity around 15 years in females and 17 years in males; total vertical growth continues beyond 15 years of age in both sexes; mid-facial projection, measured from Tragus to Stomion (about mid-ear to the antero-medial point between the upper and lower lip), reaches maturity at 14 years in males and 13 years in females; and final size maturity is attained between 13 and 15 years in females and 17 and 25 years in males [4, 10-11, 14].

Figure 1 depicts the growth percentages of adult size attained at certain ages for four specific craniofacial components: mandible, maxilla, orbits, and total/composite face. Female percentages are shown on the left and male percentages on the right. Noteworthy are the maturation percentages in the graphs reached around age five years. The resounding significance of age five years in the graphs is visually represented by the images on the left-comparing skeletal components at age five years on the left with a mature skeleton on the right.

## DISCUSSION AND CONCLUSION

In Figure 1, one can begin to see how individualized facial parts develop in tandem with one another. Darwin *et al.* [11] suggest that simply uniting the distinct

sections to create a picture of the whole falls short of the realistic growth and development rate and pattern. However, by further understanding the growth velocities and peak growth spurts of singular aspects, one can better comprehend how each of the moving parts creates the greater whole. This study synthesized the percentages of the key components of the developing facial complex into a fluid description in order to display the full pattern of craniofacial growth and development from birth through maturation at 18 years.

Growth and development of sub-adults follows a general pattern; however, determining specific individual growth patterns is complicated because children's faces grow at different velocities and may mature at a pace that is either delayed or advanced

Compared to other children of the same age [6, 36]. In addition, whenever prediction comes into play there is an element of uncertainty involved. Nevertheless, tracking which parts of the face change and their time of change can make us better understand their growth and development, and may improve the validity of age-progressing (or regressing) according to the minute changes occurring in the growing and developing craniofacial complex.

By determining facial maturational changes, researchers can develop technologies accordingly for use in the Identity Sciences through age-progression, age-regression, and identification. Age-progression has been explored in order to project known images of missing children to create a relevant depiction that reflects their current age rather than the age at the time of disappearance. Fine-tuning the stages of growth and development will improve accuracy. Age-regression may enable photographic comparisons for investigating adults believed to be former missing children, or in cases of human trafficking where identities were changed. Further, Facial Identification technology has been on the rise in congruence with enhanced security systems. Looking forward, this area of study is expanding into individual access on personal devices and even facial analytics-the ability to derive useful identification/authentication information from the face. These applications have been adult-focused and it remains to be seen how juvenile faces will be integrated into such arenas. In summation, the research provided within offers a description of sub-adult craniofacial morphological growth and development-from a synergistic perspective-relevant for advancing face recognition technologies within the

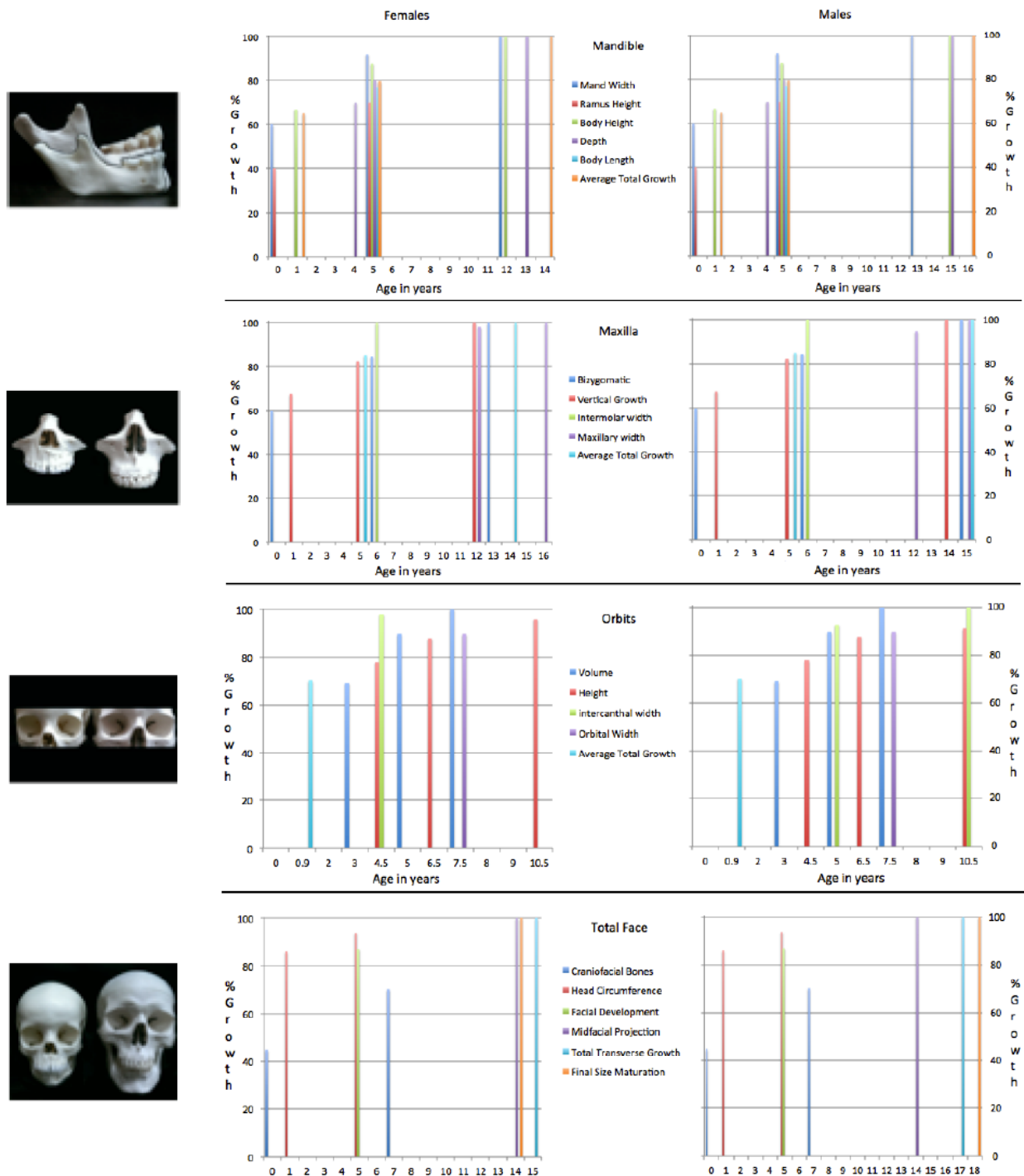


Figure 1: Female and Male Growth Percentages of Adult Size Attained.

forensic and identity sciences. This study demonstrates the applicability of anthropological research to forensic science and technology, areas that continue to expand globally.

REFERENCES

[1] Higgins JPT, Green S, editors. Cochrane Handbook for Systematic Reviews of Interventions; 2011, Version 5.1.0, The Cochrane Collaboration. www.cochrane-handbook.org

[2] Ferguson DJ. Growth of the face and dental arches. In: Dean JA, Avery DR, McDonald RE, editors. McDonald and Avery's Dentistry for the child and adolescent. 10th ed. Mosby, Elsevier 2016; 375-89. <http://www.sciencedirect.com.liblink.uncw.edu/science/article/pii/B978032328745600020X>

[3] Hutchinson EF, L'Abbé EN, Oettlé AC. An assessment of early mandibular growth. For Sci Int 2012; 217: 233.e1-233.e6. <http://www.sciencedirect.com.liblink.uncw.edu/science/article/pii/S0379073811005494>

- [4] Costello BJ, Rivera RD, Shand J, Mooney M. Growth and development considerations for craniomaxillofacial surgery. *Oral Maxillofacial Surg Clin N Am* 2012; 24: 377-96. <http://www.sciencedirect.com.liblink.uncw.edu/science/article/pii/S1042369912000921>
- [5] Liu YP, Behrents RG, Buschang PH. Mandibular growth, remodeling, and maturation during infancy and early childhood. *Angle Orthod* 2010; 80: 97-105. <http://dx.doi.org/10.2319/020309-67.1>
- [6] Suri S, Prasad C, Tompson B, Lou W. Longitudinal comparison of skeletal age determined by the Greulich and Pyle method and chronologic age in normally growing children, and clinical interpretations for orthodontics. *Am J Orthod Dentofacial Orthop* 2013; 143: 50-60. <http://dx.doi.org/10.1016/j.ajodo.2012.08.027>
- [7] Farkas LG, Posnick JC, Hreczko TM. Growth patterns of the face: A morphometric study. *Cleft Palate Craniofac J* 1992; 29: 308-15. [http://dx.doi.org/10.1597/1545-1569\(1992\)029<0308:GPOTFA>2.3.CO;2](http://dx.doi.org/10.1597/1545-1569(1992)029<0308:GPOTFA>2.3.CO;2)
- [8] Brahim JS. Dental implants in children. *Oral Maxillofacial Surg Clin N Am* 2005; 17: 375-381. <http://www.ncbi.nlm.nih.gov/pubmed/18088793>
- [9] Xu Y, Yang C, Schreuder WH, Shi J, Shi B, Zheng Q, *et al.* Cephalometric analysis of craniofacial morphology and growth in unrepaired isolated cleft palate patients. *J Craniomaxillofac Surg* 2014; 42: 1853-60. <http://dx.doi.org/10.1016/j.jcms.2014.07.003>
- [10] Nanda R, Snodell SF, Bollu P. Transverse growth of maxilla and mandible. *Semin Orthod* 2012; 18: 100-17. [http://www.semortho.com/article/S1073-8746\(11\)00104-6/abstract?cc=y](http://www.semortho.com/article/S1073-8746(11)00104-6/abstract?cc=y) <http://dx.doi.org/10.1053/j.sodo.2011.10.007>
- [11] Darwis WE, Messer LB, Thomas CDL. Assessing growth and development of the facial profile. *Pediatr Dent* 2003; 25: 103-08. <http://www.aapd.org/assets/1/25/Darwis2-03.pdf>
- [12] Humphrey LT. Growth patterns in the modern human skeleton. *Am J Phys Anthropol* 1998; 105: 57-72. [http://dx.doi.org/10.1002/\(SICI\)1096-8644\(199801\)105:1<57::AID-AJPA6>3.0.CO;2-A](http://dx.doi.org/10.1002/(SICI)1096-8644(199801)105:1<57::AID-AJPA6>3.0.CO;2-A)
- [13] Glowacki J, Christoph K. Gender differences in the growing, abnormal, and aging jaw. *Dent Clin N Am* 2013; 57: 263-80. <http://www.ncbi.nlm.nih.gov/pubmed/23570805>
- [14] Chvatal BA, Behrents RG, Ceen RF, Buschang PH. Development and testing of multilevel models for longitudinal craniofacial growth prediction. *Am J Orthod Dentofacial Orthop* 2005; 128: 45-56. <http://dx.doi.org/10.1016/j.ajodo.2004.03.035>
- [15] Subramaniam P, Naidu P. Mandibular dimensional changes and skeletal maturity. *Contemp Clin Dent* 2010; 1: 218-22. <http://www.ncbi.nlm.nih.gov/pmc/articles/PMC3220140/>
- [16] Buschang P, Hinton R. A gradient of potential for modifying craniofacial growth. *Semin Orthod* 2005; 11: 219-26. <http://dx.doi.org/10.1053/j.sodo.2005.07.006>
- [17] Pecora NG, Baccetti T, McNamara Jr. JA. The aging craniofacial complex: A longitudinal cephalometric study from late adolescence to late adulthood. *Am J Orthod Dentofacial Orthop* 2008; 134: 496-505. <http://www.sciencedirect.com/science/article/pii/S0889540608006744>
- [18] Angelieri F, Cevidanes LHS, Franchi L, Gonçalves JR, Benavides E, McNamara Jr. JA. Midpalatal suture maturation: Classification method for individual assessment before rapid maxillary expansion. *Am J Orthod Dentofacial Orthop* 2013; 144: 759-69. <http://dx.doi.org/10.1016/j.ajodo.2013.04.022>
- [19] Kato M, Kajimoto Y, Matsuo H, Ikemoto H, Kunimoto A, Kato S, *et al.* Three dimensional measurements of the palate using the semiconductor laser 3. Changes in the palate section areas, palate projection areas and palate volumes in the early permanent dentition according to age. *Ped Dent J* 2010; 20: 165-70. [http://www.pediatric-dental-journal.com/article/S0917-2394\(10\)70208-1/abstract](http://www.pediatric-dental-journal.com/article/S0917-2394(10)70208-1/abstract)
- [20] Castelo PM, Pereira LJ, Bonjardim LR, Gavião MBD. Changes in bite force, masticatory muscle thickness, and facial morphology between primary and mixed dentition in preschool children with normal occlusion. *Ann Anat* 2010; 192: 23-6. <http://dx.doi.org/10.1016/j.aanat.2009.10.002>
- [21] Sforza C, Dolci C, Tommasi DG, Pisoni L, De Menezes M, Elamin F. Three-dimensional facial distances of Northern Sudanese persons from childhood to young adulthood. *J Craniomaxillofac Surg* 2014; 42: e318-26. <http://dx.doi.org/10.1016/j.jcms.2013.10.013>
- [22] Moreira I, Suri S, Tompson B, Fisher D, Lou W. Soft-tissue profile growth in patients with repaired complete unilateral cleft lip and palate: A cephalometric comparison with normal controls at ages 7, 11, and 18 years. *Am J Orthod Dentofacial Orthop* 2014; 145: 341-58. <http://dx.doi.org/10.1016/j.ajodo.2013.11.018>
- [23] Berger AJ. Growth and development of the orbit. *Oral Maxillofacial Surg Clin N Am* 2012; 24: 545-55. <http://www.ncbi.nlm.nih.gov/pubmed/23107427>
- [24] Cohen Jr. MM. The new perspectives on the face. In Posnick JC, editor. *Orthognathic surgery: Principles & practice*. St. Louis, MO: Elsevier Saunders 2014; 1-17. <http://dx.doi.org/10.1016/B978-1-4557-2698-1.00001-0>
- [25] Sforza C, Grandi G, Catti F, Tommasi DG, Ugolini A, Ferrario VF. Age- and sex-related changes in the soft tissues of the orbital region. *Forensic Sci Int* 2009; 185: (115.e1-8). <http://dx.doi.org/10.1016/j.forsciint.2008.12.010>
- [26] Sforza C, Elamin F, Tommasi DG, Dolci C, Ferrario VF. Morphometry of the soft tissues of the orbital region in Northern Sudanese persons. *Forensic Sci Int* 2013; 228: 180.e1-11. <http://www.sciencedirect.com.liblink.uncw.edu/science/article/pii/S0379073813000686>
- [27] Yang G, Wang J, Chang Q, Wang Z, Geng Y, Li D. Digital evaluation of orbital development in Chinese children with congenital microphthalmia. *Am J Ophthalmol* 2012; 154: 601-9. <http://www.sciencedirect.com.liblink.uncw.edu/science/article/pii/S0002939412002383>
- [28] Boyette JR. Facial fractures in children. *Otolaryngol Clin N Am* 2014; 47: 747-61. <http://www.sciencedirect.com.liblink.uncw.edu/science/article/pii/S0030666514000644>
- [29] Park SW, Choi J, Park HO, Lim YS, Lee KD, Kim NG *et al.* Are gender differences in external noses caused by differences in nasal septal growth? *J Craniomaxillofac Surg* 2014; 42: 1140-7. <http://www.sciencedirect.com.liblink.uncw.edu/science/article/pii/S1010518214000572>
- [30] Sforza C, Grandi G, De Menezes M, Tartaglia GM, Ferrario VF. Age- and sex-related changes in the normal human external nose. *Forensic Sci Int* 2010; 204(205): e1-9. <http://www.sciencedirect.com.liblink.uncw.edu/science/article/pii/S0379073810003762>
- [31] Chen F, Chen Y, Yu Y, Qiang Y, Liu M, Fulton D *et al.* Age and sex related measurement of craniofacial soft tissue thickness and nasal profile in the Chinese population. *Forensic Sci Int* 2011; 212: 272.e1-6. <http://dx.doi.org/10.1016/j.forsciint.2011.05.027>
- [32] Fudalej P, Kokich VG, Leroux B. Determining the cessation of vertical growth of the craniofacial structures to facilitate placement of single-tooth implants. *Am J Orthod Dentofacial Orthop* 2007; 131: s59-67. <http://dx.doi.org/10.1016/j.ajodo.2006.07.022>
- [33] Vieira BB, Itikawa CE, de Almeida LA, Sander HS, Fernandes RMF, WT, *et al.* Cephalometric evaluation of facial pattern and hyoid bone position in children with

- obstructive sleep apnea syndrome. *Int J Pediatr Otorhinolaryngol* 2011; 75: 383-6. <http://www.sciencedirect.com.liblink.uncw.edu/science/article/pii/S0165587610005823>
- [34] Taylor KT. *Forensic art and illustration*. Boca Raton, FL: CRC Press LLC; 2001. Murakami D, Inada E, Saitoh I, Takemoto Y, Morizono K, Kubota N *et al.* Morphological differences of facial soft tissue contours from child to adult of Japanese males: A three-dimensional cross-sectional study. *Arch Oral Biol* 2014; 59: 1391-9. <http://www.sciencedirect.com.liblink.uncw.edu/science/article/pii/S0003996914002118>
- [35] Mellion ZJ, Behrents RG, Johnston Jr. LE. The pattern of facial skeletal growth and its relationship to various common indexes of maturation. *Am J Orthod Dentofacial Orthop* 2013; 143: 84 5-84 <http://dx.doi.org/10.1016/j.ajodo.2013.01.019>

---

Received on 15-06-2016

Accepted on 30-06-2016

Published on 12-07-2016

<http://dx.doi.org/10.15379/2410-2806.2016.03.01.03>

© 2016 Albert and Wright; Licensee Cosmos Scholars Publishing House.

This is an open access article licensed under the terms of the Creative Commons Attribution Non-Commercial License

(<http://creativecommons.org/licenses/by-nc/3.0/>), which permits unrestricted, non-commercial use, distribution and reproduction in any medium, provided the work is properly cited.