

Transarterial Radionuclide Therapy with ^{188}Re -Labelled Lipiodol

N. Lepareur^{1,2,*} and E. Garin^{1,2}

¹*Comprehensive Cancer Centre Eugène Marquis, F-35042 Rennes, Cedex France*

²*Institut NuMeCan U1241 Inserm/Inra/Université Rennes 1, F-35033 Rennes Cedex France*

Abstract: Hepatocellular carcinoma (HCC) is usually detected late, in patients with advanced disease, who are thus not eligible for radical therapy. Despite this grim scenario, new treatment options for intermediate to advanced stages hold great promise, such as internal radionuclide therapy. Several techniques have been developed for radionuclide therapy of HCC. Among these, use of transarterial injection of a radiolabelled embolizing agent, such as microspheres or Lipiodol, has led to very encouraging results. Over the last few years, efforts to label Lipiodol with rhenium-188, an attractive beta-emitter, have led to a very active area of research. Lipiodol has been labelled either directly or by solubilisation of a lipophilic ^{188}Re -labelled complex. Preliminary clinical findings indicate the feasibility of using ^{188}Re -labelled Lipiodol, which has shown good tolerance and good response rates in the treatment of unresectable HCC as well as in adjuvant or neo-adjuvant settings.

Keywords: Hepatocellular carcinoma, Lipiodol, Radionuclide therapy, Rhenium-188.

INTRODUCTION

Primary liver cancers, 75 % of which are hepatocellular carcinoma [1, 2], are among the most common tumours worldwide. In terms of mortality, HCC ranks second in cancer-related deaths worldwide for men [3]. China accounts for half of the number of cases and deaths. In the vast majority of cases, HCC develops on an underlying liver disease, mostly cirrhosis, whose nature varies according to geographical region or ethnic group. 73.4 % of HCC cases are attributable to hepatitis B virus (HBV) and hepatitis C virus (HCV) [4, 5]. In India, for instance, 70 % to 80 % of all HCCs are related to HBV, approximately 15 % are related to HCV, and 5 % to both HBV and HCV. Alcohol alone accounts for approximately 8 % of all HCCs; in about 10 %, no direct etiology is seen. Iron overload and aflatoxin may also have a role in some geographical areas in India [6]. On the contrary, in Japan, HCV-related HCCs are predominant [7]. In Western countries, the main risk factors are alcohol and non-alcoholic fatty liver diseases, such as obesity and diabetes [8], though an increase in HCV is to be noticed [9]. HCC prognosis remains very poor, despite a large range of treatment options [10, 11]. The heterogeneity in terms of aetiology and underlying disease further complicates the management of HCC. Treatment decisions are complex and dependent upon tumour staging, presence of portal hypertension, and the underlying degree of liver dysfunction, as well as local expertise,

as indicated by the National Comprehensive Cancer Network (NCCN), Asian Pacific Association for the Study of the Liver (APASL), American Association for the Study of Liver (AASLD), Barcelona-Clinic Liver Cancer (BCLC), European Association for the Study of the Liver (EASL), and Italian Association of Study of the Liver (AISF) guidelines [9] (Figure 1). Due to generally late detection and pre-existing hepatopathy, 5-year survival is less than 5 %, and curative treatments, such as surgical resection or liver transplantation, are usually not possible. Less than 25 % of patients are candidates for these treatments. Furthermore, even for such patients, recurrence rates are high (10 to 40 % for transplantation and up to 50 % at 2 years for resection) [12]. For the vast majority of patients not eligible for curative treatments, liver-directed therapies can be proposed [13]. Until now, no systemic treatment has shown real effectiveness [14]. Progresses in external beam radiotherapy methods have recently improved the efficacy and tolerance of this technology for liver cancers [15, 16], but the method is still not considered as a standard of care.

HCC being a richly vascularised tumour, mainly irrigated via the hepatic artery, while the healthy liver is supplied at 80 % by the portal vein, intra-arterially delivered treatments, such as transarterial chemoembolisation (TACE) and transarterial radioembolisation (TARE), represent two promising therapeutic approaches for patients without an advanced form of HCC. Currently, the most widely used treatment involves TACE coupled with intra-arterial injection of an emulsion of Lipiodol and a chemotherapeutic drug, followed by the occlusion of the feeding artery. TACE is currently considered as the standard of care for

*Address correspondence to this author at the Nuclear Medicine Department, Centre Eugene Marquis, Avenue de la Bataille Flandres-Dunkerque, CS 44229, F-35042 Rennes, France;
Tel: +33-2-99-25-31-44; Fax: +33-2-99-25-32-60;
E-mail: n.lepareur@rennes.unicancer.fr

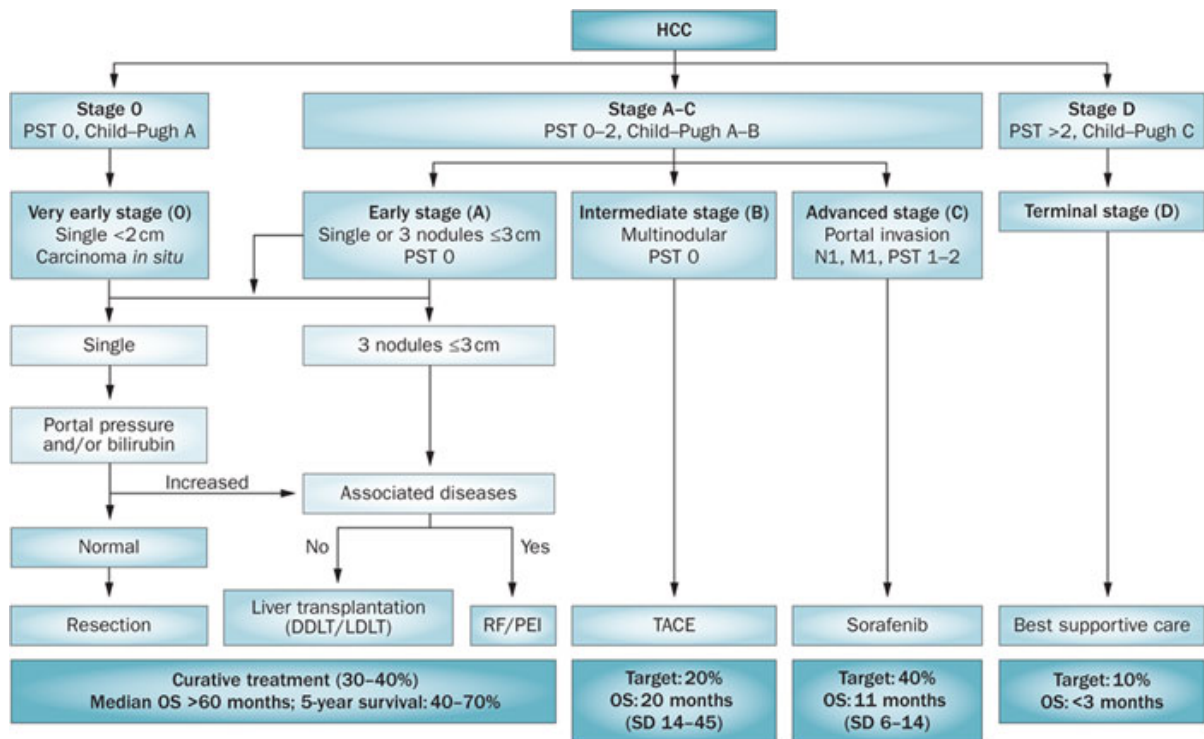


Figure 1: BCLC staging system and therapeutic strategy according to EASL-EORTC guidelines.

Staging classification comprises five stages that select the best candidates for the best therapies currently available. Patients with asymptomatic early tumours (stage 0-A) are candidates for radical therapies (resection, transplantation or local ablation). Asymptomatic patients with multinodular HCC (stage B) are suitable for chemoembolization (TACE), whereas patients with advanced symptomatic tumours and/or an invasive tumoural pattern (stage C) are candidates to receive sorafenib. End-stage disease (stage D) includes patients with grim prognosis that should be treated by best supportive care. Abbreviations: BCLC, Barcelona Clinic Liver Cancer; DDLT, deceased donor liver transplantation; EASL, European Association for the Study of Liver Disease; EORTC, European Organisation for Research and Treatment of Cancer; GRADE, grading of recommendations assessment, development and evaluation; HCC, hepatocellular carcinoma; LDLT, living donor liver transplantation; PEI, percutaneous ethanol injection; RF, radiofrequency ablation; TACE, transcatheter arterial chemoembolization; OS, overall survival; PST, performance status. ©European Association for the Study of the Liver; European Organisation for Research and Treatment of Cancer. (European Association for the Study of the Liver, European Organisation for Research and Treatment of Cancer. EASL-EORTC Clinical Practice Guidelines: Management of hepatocellular carcinoma. J Hepatol 2012; 56: 908-43).

intermediate stage HCCs, achieving partial response in 20-50 % of patients and an expansion of median survival for up to 20 months [17], but its therapeutic efficacy is still disputed. Though not yet fully integrated into treatment decision schemes, transarterial radioembolisation, or selective internal radiation therapy (SIRT), is one of the most promising treatment modalities for intermediate stage HCCs [18, 19]. This strategy consists in the selective delivery of radiation directly to the tumour cells, while preserving healthy liver and minimizing systemic irradiation. Various materials (Lipiodol, glass, resin or polymer microspheres) and various radioisotopes have been used. The radioisotopes used in these preparations are beta-emitters, such as ^{166}Ho , ^{131}I , ^{177}Lu , ^{32}P , $^{186/188}\text{Re}$ and ^{90}Y .

Lipiodol is a mixture of iodinated ethyl esters of poppy seed oil, which contains approximately 38 % iodine by weight and has been used as a CT contrast

agent and as a carrier for TACE. When injected through the hepatic artery, it has been shown to be selectively trapped in tumour cells (HCC and some hepatic metastases) and to display prolonged retention within the tumour [20, 21]. Historically, Lipiodol was first labelled with iodine-131, by exchange with “cold” iodine [22], with encouraging results in HCC management [23, 24]. However, the high energy gamma emission and long half-life of iodine-131 ($E_{\beta\text{max}} = 0.81 \text{ MeV}$; $E_{\gamma} = 364 \text{ keV}$ (81 %); $t_{1/2} = 8.02 \text{ d}$), as well as its high production cost have hindered its more widespread use. Yttrium-90, a pure beta-emitter ($E_{\beta\text{max}} = 2.28 \text{ MeV}$; $t_{1/2} = 64.0 \text{ h}$, max tissue penetration = 12 mm) [25], and rhenium-188 ($E_{\beta\text{max}} = 2.12 \text{ MeV}$; $E_{\gamma} = 155 \text{ keV}$ (15 %); $t_{1/2} = 16.9 \text{ h}$, max tissue penetration = 11 mm) [26] have been proposed as an advantageous alternative to iodine-131. As highlighted in this special issue, rhenium-188 appears promising, and several approaches have been proposed to label Lipiodol with this isotope, some of them being under clinical evaluation.

LIPIODOL RADIOLABELLING

Lipiodol labelling with iodine-131 is accomplished by simple isotopic exchange. This method is however not feasible for radiolabelling with rhenium-188, since a chelate is necessary to bind the metal. ¹⁸⁸Re attached to the covalently bound EDTB (*N, N, N', N'*-tetrakis-(2-benzimidazolmethyl)-1,2-ethanediamine)chelate led to biodistribution results similar to ¹³¹I-labelled Lipiodol, but the radiolabelling method was awkward, as it was difficult to achieve a reaction between the aqueous [¹⁸⁸Re]-perrhenate and the water-insoluble Lipiodol [27, 28]. A simpler and more elegant approach was then proposed by Jackson *et al.* [29]. This approach consists in the preparation of a strongly lipophilic rhenium complex, which would be then solubilised in strongly hydrophobic Lipiodol. The labelling is thus not attained through a covalent bond but through hydrophobic interactions. It is thus of prime importance that the rhenium complex possesses sufficient lipophilicity to be dissolved into the Lipiodol phase and sufficient stability to remain firmly trapped in this substance. Soon after, Jeong *et al.* proposed the first "labelling" of Lipiodol with rhenium-188 chelated by an N₂S₂ ligand, ¹⁸⁸Re-TDD (2,2,9,9-tetramethyl-4,7-diaza-1,10-decanedithiol) [30]. The radiotracer had an insufficient retention, owing to a continuous elimination of the chelate, which was in equilibrium with a hydrosoluble cationic species, so the same authors developed long-chain alkyl derivatives (from C₈ to C₁₆) with improved uptake and retention [31]. The longer the alkyl chain, the more lipophilic the compound, and, hence, the stronger the hydrophobic interactions between the fatty chains of the chelate and Lipiodol. Accordingly, the 4-hexadecyl derivative (¹⁸⁸Re-HDD) seemed the most promising, especially when compared with ¹⁸⁸Re-TDD [32]. Indeed, its tumour retention was increased 1.8-fold in tumour-bearing rabbit models. However, one limitation of ¹⁸⁸Re-HDD/Lipiodol is its relatively low labelling yield, between 50 and 70 %, which reduces the opportunity to obtain the highest therapeutic activities. Subsequently, a more efficient labelling approach (78 % yield), by replacing the HDD kit (containing the HDD ligand, tin chloride, tartaric acid and mannitol) by an AHDD kit, in which the two sulphhydryl groups of the dithiolate ligand are acetylated [33]. This protection enhances the ligand stability, without modifying the biodistribution pattern, as shown in mice, following injection through the tail vein, the final product being the same ¹⁸⁸Re-HDD/Lipiodol radioconjugate. More recently, the ¹⁸⁸Re-HDD complex was renamed ¹⁸⁸Re-HTDD, being more consistent with initial results with TDD, T standing for tetramethyl. A new HDD compound was then

developed, without the four methyl groups [34] (Figure 2). This new compound showed a significantly higher extraction yield into Lipiodol with 90.2 ± 2.6 %. Biodistribution was however only investigated through intravenous injection in healthy mice, thus tumour uptake or even liver uptake was not assessed.

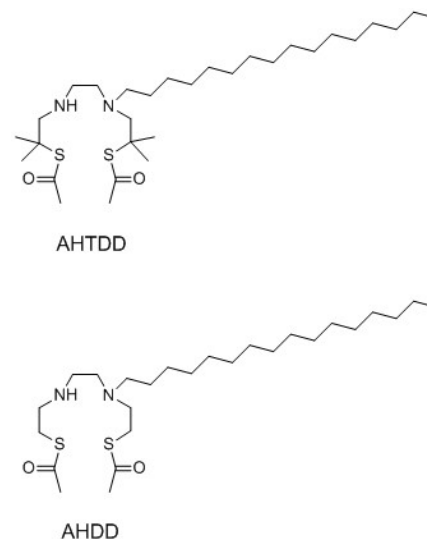


Figure 2: Structures of AHTDD and AHDD ligands.

Other N₂S₂ chelates have also been developed and investigated for Lipiodol labelling with ¹⁸⁸Re (Figure 3). ECD (ethyl cysteinyl dimer), labelled with technetium-99m, is well known as a brain perfusion agent. Labelled with rhenium-188, it has been proposed as a suitable compound to be solubilised in Lipiodol [35]. This radioconjugate was obtained with a radiochemical purity of over 94 % and an activity concentration ranging from 1 to 10 mCi per mL of Lipiodol, but no information was provided on the Lipiodol extraction yield. Following intra-arterial injection of ¹⁸⁸Re-ECD/Lipiodol in rats, the average tumour-to-liver ratio steadily decreased from 13.21 at 1 h to 6.84 at 48 h, with high lung uptake and high urinary extraction, due to the constant washout of the rhenium complex from Lipiodol. This can be explained by the fact that part of the chelate is rapidly converted to a water-soluble form and excreted through the urinary bladder, as already described with the ^{99m}Tc-analogue. To minimise these drawbacks, Luo *et al.* more recently described the intratumoural administration of this radioconjugate [36]. In a 60-day survival study, they demonstrated an improved survival for treated rats compared to control group (62 % and 20 % respectively). Wang *et al.* proposed another chelate based on the TDD moiety, the NEMPTDD, replacing the long alkyl chain with a 4'-methyl-β-piperidylethyl pendant arm [37]. (Figure 3) The radioconjugate was also based on a more stable rhenium-nitrido core, instead of the more classical

rhenium-oxo core. The $^{188}\text{ReN-NEMPTDD}$ complex was obtained in high-yield (> 95 %) and was stable *in vitro* and quickly eliminated *in vivo*. It was used to label Lipiodol – with no information on the extraction yield – and subsequently injected into VX2 tumour-bearing rabbits, with an estimated biological half-life of 12 h in the tumour. Another recently developed N_2S_2 ligand is the MN-16ET, developed by Tang *et al.* [38], in which the two sulphhydryls of the dithiolate ligand are protected by triphenylmethyl groups and the lipophilic chain is an ethylhexadecanoate moiety. (Figure 3) This radioconjugate was assessed for its therapeutic efficacy [39] and compared to TACE in another animal study [40]. Rats treated with ^{188}Re -labelled Lipiodol showed increased survival and decreased tumour size compared to Lipiodol alone, or Lipiodol + epirubicine.

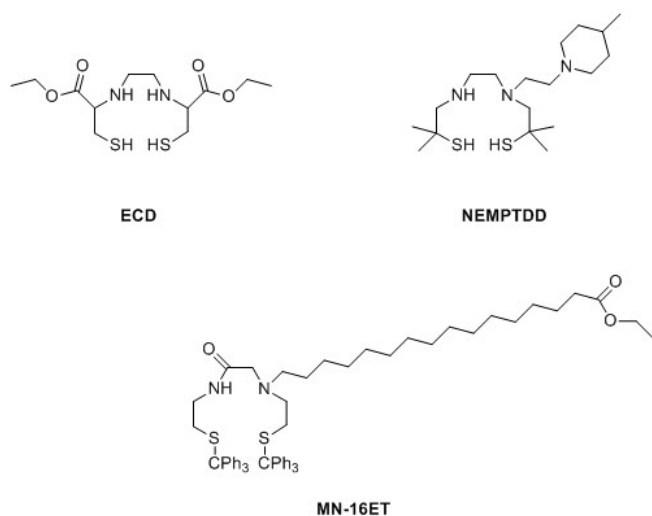


Figure 3: N_2S_2 chelates investigated with ^{188}Re for Lipiodol labelling.

As another key example, $^{188}\text{ReN(DEDCC)}_2$ (nitridorhenium-(diethylthiocarbamate) rhenium), based on the more stable nitridorhenium core, was prepared with high yield (> 95 %) [41] and was almost quantitatively extracted in Lipiodol (96 %). Biodistribution studies in non-tumour-bearing rats have shown promising results, with high uptake in the liver (2.3 % ID/g at 6 h), without prolonged retention due to the absence of tumour (0.3 % ID/g at 72 h). However, at high activities (7.7-12.0 GBq in 2.5 mL Lipiodol), there is a significant radiolysis of $^{188}\text{ReN-DEDCC/Lipiodol}$, which can be limited by dilution with cold Lipiodol.

Since rhenium (V) is easily reoxidised to rhenium (VII), rhenium-188 radioconjugates at lower oxidation states have been proposed to label Lipiodol. $^{188}\text{Re-SSS}$ [42], a rhenium (III) complex, has been used to label Lipiodol with high yield and high radiochemical purity

(> 90 %). This agent demonstrated very high *in vivo* stability and preferential tumour uptake in hepatoma-bearing rats [43]. Rhenium (I), based on a tricarbonyl core, was also proposed, but only described with rhenium-186 [44]. Even lower oxidation states have been proposed, since labelling of Lipiodol with elemental ^{188}Re , simply reduced from ^{188}Re -perrhenate and without any chelating agent has been described [45].

The whole preparation involves different steps and complex manipulation of high activities of ^{188}Re that dramatically increases radiation exposure of the operator, particularly at the finger tips [46]. Automation of the process was therefore developed by several teams for their respective radioconjugates [47, 48]. Current advantages of automation include the elimination of the aqueous solvent and of any residual hydrophilic species such as ^{188}Re -perrhenate, through a C18 Sep-Pak cartridge, sterilisation by passing the resulting solution through a 0.22 μm filter, thus complying with radiopharmacy standards, and, most of all, reduced operator assistance during the production process resulting in a dramatic reduction of radiation exposure [49].

Direct comparison between the different radioconjugates is not possible, because different animals were used (rats, mice, rabbits and pigs), with or without tumour, and with different tumour strains (VX2, N1-S1) in the first case, or with different injection modalities (intra-arterial or intra-venous) in the second case.

CLINICAL RESULTS

In the last few years, transarterial metabolic radiotherapy has gained a central role in the management of patients with primary and metastatic liver malignancies [50, 51]. In particular, the efficacy of these locoregional radiation-based treatments has been demonstrated in HCC. A summary of clinical trials involving TARE in HCC management – with emphasis on radiolabelled Lipiodol – is given in Table 1. The first agent to be developed has been ^{131}I -labelled Lipiodol, in the mid-80's [52, 53]. Very encouraging results with Phase III trials showed it was effective in patients with HCC and portal vein thrombosis (PVT) and in prevention of post-resection recurrence, and it was equivalent to chemoembolization in patients with HCC without PVT [24, 54]. However, its development was hindered by the characteristics of iodine-131. Indeed, beside its high production cost, iodine-131 has a long

Table 1: Clinical Trials Involving TARE

Year	Therapy	Findings	Reference
1988	¹³¹ I-Lipiodol	50 % tumour size reduction, 60 % response rate	[93]
1991	¹³¹ I-Lipiodol	88.9 % response rate – 25 % according to tumour size	[94]
1992	¹³¹ I-Lipiodol	Decrease of pain in 33 % – 66 %	[95]
1994	¹³¹ I-Lipiodol vs. BSC	Survival benefit; 48 % vs. 0 % at 6 months	[96]
1997	¹³¹ I-Lipiodol vs. TACE	¹³¹ I Lipiodol and TACE equally effective; better tolerance, lower side-effects	[97]
1999	¹³¹ I-Lipiodol after surgery	Increased TTP and survival.	[98]
1999	¹³¹ I-Lipiodol	Median survival time: 147 days; Side-effects not rare for patients with PVT	[99]
2002	¹³¹ I-Lipiodol plus cisplatin	Increased response rate: 90 % combined therapy vs. 40 % ¹³¹ I Lipiodol alone	[79]
2003	¹³¹ I-Lipiodol prior to liver transplantation	1-year recurrence free survival rate: 91 % 3-year recurrence free survival rate: 83 %	[72]
2003	¹³¹ I-Lipiodol after surgery	3-year survival rates: 91.7 % vs. 49.9 % without adjuvant treatment	[100]
2006	¹³¹ I-Lipiodol	6 cm tumour diameter is the limit for reasonable therapy; comparable with other methods.	[101]
2006	¹³¹ I-Lipiodol plus cisplatin	Survival rate: 73 % at 1 year; 48 % at 2 years; 43 % at 3 years	[80]
2007	¹³¹ I-Lipiodol	Response rate: 47.5 % Median survival: 27 months	[102]
2009	¹³¹ I-Lipiodol vs. TACE/TAE	In patients with unresectable HCC, no difference in survival. In patients with advanced clinical staging or PVT, significant survival advantage for those treated with ¹³¹ I-Lipiodol.	[103]
2010	¹³¹ I-Lipiodol	Median survival time: 14 months Median TTP: 6 months	[104]
2013	¹³¹ I-Lipiodol	Median survival 32 weeks vs. 8 weeks for untreated group	[23]
2013	¹³¹ I-Lipiodol after surgery	Lipiodol group showed a small, and nonsignificant, improvement over control in recurrence free survival rate	[105]
2001	⁹⁰ Y-microspheres plus chemotherapy vs. chemotherapy	Tumour response 44 % combined therapy versus 17.6 % chemotherapy alone	[106]
2006	⁹⁰ Y-microspheres	Disease control rate 100 % and response rate 23.8 %	[107]
2012	⁹⁰ Y-microspheres	Favourable median survival time	[108]
2014	⁹⁰ Y-microspheres plus sorafenib	Potential efficacy and manageable toxicity	[109]
2015	⁹⁰ Y-microspheres	Safe and effective treatment modality in intermediate to advanced-stage HCC	[110]
2015	⁹⁰ Y-microspheres vs. DEB-TACE	No significant differences in PFS, OS, and TTP	[111]
2015	⁹⁰ Y-microspheres plus sorafenib	⁹⁰ Y-microspheres plus sorafenib well-tolerated as sorafenib alone	[112]
2016	⁹⁰ Y-microspheres vs. sorafenib	⁹⁰ Y-microspheres more effective than sorafenib in patients with PVT	[113]
2009	¹⁶⁶ Ho-microspheres	78 % response rate	[114]
2005	¹⁸⁸ Re-Lipiodol	Tolerance and preliminary response rates encouraging; high urinary excretion	[61]
2006	¹⁸⁸ Re-Lipiodol	Treatment well tolerated at all activity levels	[60]
2007	¹⁸⁸ Re-Lipiodol	Objective response rate: 25 % 2-year survival: 23 %	[65]

half-life and high-energy gamma emission, requiring a 7-day hospitalization in a radioprotection room. ⁹⁰Y-microspheres, either glass or resin-based, are currently the most used modality for TARE [55], but are prohibitively expensive, especially for low-income countries. In this context, rhenium-188 has a role to

play, as it can be obtained at a lower cost thanks to its generator mode of production, could be used in an outpatient setting, like yttrium-90, but with the advantage of a low energy gamma emission, enabling visualisation of the injected tracer.

Preliminary and Feasibility Studies

To date, four ^{188}Re -chelates used to label Lipiodol have been evaluated in human, *i.e.* ^{188}Re -TDD [30], ^{188}Re -(A)HDD/HTDD [34], ^{188}Re N-DEDC [41] and ^{188}Re -SSS [42] (Figure 4). ^{188}Re -TDD/Lipiodol was the first agent to be investigated, in a pilot trial with one patient [56], showing high thyroid and bowel uptake. It was quickly abandoned in favour of the more suitable ^{188}Re -HDD/Lipiodol, which had demonstrated significantly longer half-life and residence time. Indeed, based on estimated dosimetry in a rabbit liver cancer model [57], it has been calculated that, for a 100 Gy tumour irradiation, a 1.85-GBq dose of ^{188}Re -TDD/Lipiodol would be necessary with a 5.27-cm tumour, while a 1.07-GBq dose of ^{188}Re -HDD/Lipiodol would be sufficient. Most studies up to now have been performed using ^{188}Re -HDD/Lipiodol. Preliminary findings by Keng *et al.* [58] in a small group of patients showed a stabilisation of the disease after treatment, but were not fully conclusive due to the small number of patients (5) and the limited period of follow-up (0.8-6.9 months). Under the auspices of the International Atomic Energy Agency (IAEA), a multicentre multinational study was launched, including 70 patients over a period of 18 months [59]. 16 patients were treated in the dose escalation phase of the study, where the activities administered started at 1.8 GBq and rose to 7.7 GBq. In the efficacy phase of the study,

a further 54 patients were treated. The treatment activity of ^{188}Re -HDD/Lipiodol ranged from 1.8 GBq to 9.8 GBq (mean activity 4.6 GBq), with some patients receiving up to four cures, for a cumulative dose of 25.6 GBq. Only moderate adverse events (mild anorexia, right hypochondrial discomfort, low-grade fever, 2 pleural effusions) were recorded in 35 out of 70 patients. Results were 13 progressions (PR), 34 stabilised disease (SD) and 23 disease progression (DP). Another dose-escalation study has been undergone by Lambert *et al.*, in Ghent [60], in 28 patients with well-compensated cirrhosis (Child A). Activities from 4.8 to 7.0 GBq were administered in 35 treatments without severe adverse events at all activities. Symptoms were reported in 19 out of 32 treatment sessions, and all organ dose estimates were below adverse radiation-induced effects. Treatment response was 1 PR, 28 SD and 2 DP. The authors also noticed high urinary excretion ($44.1 \pm 11.7\%$ within 76 h), for a calculated whole-body effective half-life of 14.3 ± 0.9 h [61]. In both studies, further escalation was not possible because of the low yields of ^{188}Re -HDD labelling [33]. A further escalation study with ^{188}Re -Lipiodol, with SSS as chelate, is currently going on (<https://clinicaltrials.gov/show/NCT01126463>), but results have not yet been published. Only preliminary results on pharmacokinetics have been described [62], showing the high *in vivo* stability of the radiotracer, since only a faint – and mainly urinary – elimination

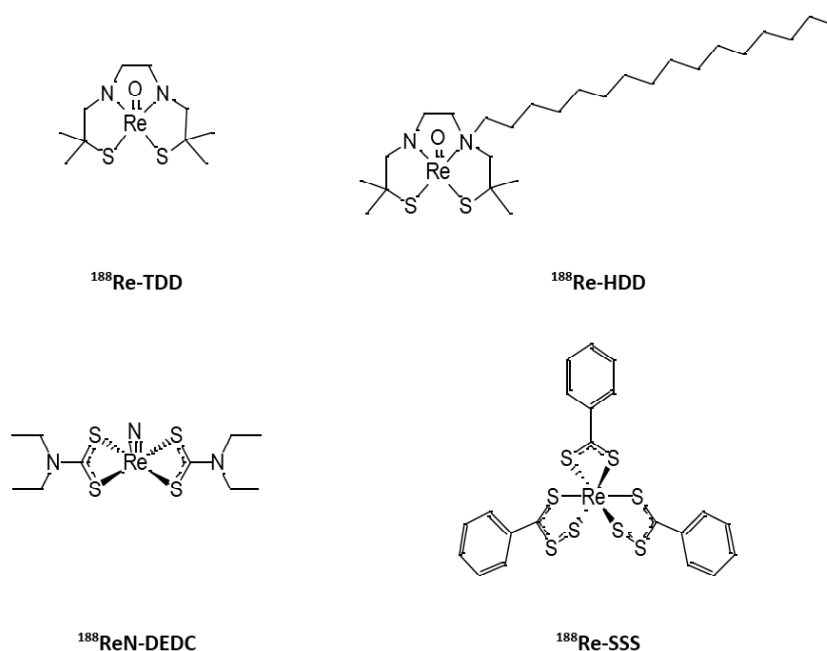


Figure 4: ^{188}Re -chelates used to label Lipiodol and evaluated in human.

occurs at 72 h (Figure 5). In a preliminary study with DEDC as chelate [41], including 11 patients, treated with activities ranging from 2.5 to 5 GBq, no treatment related adverse events were noted. However, an additional patient, treated with 6 GBq of ¹⁸⁸Re-Lipiodol, developed grade IV myelosuppression, successfully treated with platelet transfusion and granulocyte colony-stimulating factor (GCSF) therapy.

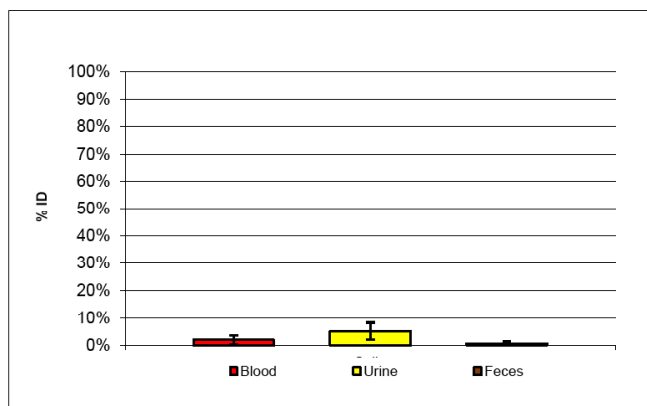


Figure 5: Elimination of ¹⁸⁸Re-Lipiodol: mean activity in blood, urine, and feces (decay corrected).

Activity escalation study by Lambert *et al.* [60], was on Child A patients. The same team also reported a feasibility study on Child B patients, with advanced underlying cirrhosis [63]. 12 patients, 4 of which with portal vein thrombosis (PVT), were treated with a mean injected activity of 3.7 ± 0.2 GBq. Adverse events were reported for 6 patients in 2 weeks, with 3 patients dropping out of the study because of deterioration of their general condition. 7 patients had a stabilised disease, and 1 had a partial response and was subsequently transplanted. The conclusion of the study was that 3.7 GBq in the proper artery or both lobes was too aggressive and that supraselective injection might preserve liver function and enhance antitumoural activity.

Another feasibility study on dosimetry-guided treatment of patients with extensive PVT was reported on one patient with a large tumour extending in the right branch and main portal vein [64]. The patient was Child A status and had an HBV-related underlying cirrhosis and received 2 doses ($4.29 + 4.17$ GBq), based on dosimetry after injection of a scout dose of ¹⁸⁸Re-Lipiodol (185 MBq). The doses to the tumour were respectively 127 and 123 Gy. The authors noted a complete disappearance of tumour and thrombus after the 2nd injection. Unfortunately, the patient died of liver failure due to progression of his cirrhosis, after 14 months.

Phase II Study

Since preliminary results seemed promising, a Phase II trial was sponsored by the IAEA, including 185 patients from 8 countries, over a period of 5 years [65, 66]. Among these patients, 134 were treated only once, while 51 were treated up to 4 times. Total injected doses ranged from 0.78 to 13.45 GBq (including the scout dose used to calculate the patient specific dosimetry to critical organs). The mean administered dose was 4 GBq, representing a mean tumour absorbed dose of 63.4 Gy. Upon a median 455 days follow-up, findings were 25 % objective response (among which 3 % of complete response), 53 % stable disease and 22 % tumour progression. The 1-year survival reached 46 %, and 2-year survival was 23 %. Factors affecting survival were: country of origin, existence of a cirrhosis, CLIP score, tumour dose, absence of progression, and post-treatment decrease in α -Fetoprotein level. Overall, treatment was well tolerated, with less than 20 % severe adverse events. The authors therefore called for a phase-III clinical trial.

In the 93 patients from India and Vietnam, from the IAEA Phase II study, as reported by Kumar *et al.* [67], mean activity was 5.3 ± 1.6 GBq which delivered 88 Gy to the tumour. Treatment was well tolerated and response rates were 33 % objective response (among which 8 % of complete response), 35 % stable disease and 32 % tumour progression. While overall survival rates at 6, 12, 24, and 36 months were 75 %, 50 %, 30 %, and 20 %, respectively, with a median survival of 356 days, corresponding survival rates among patients with objective tumour response were 100 %, 90 %, 58 %, and 30 %, with a median survival of 980 days.

Adjuvant and Neo-Adjuvant Treatments

¹³¹I-Lipiodol has shown encouraging results as adjuvant treatment, with an increase in overall and disease-free survivals [68]. ¹⁸⁸Re-Lipiodol has thus been investigated for this indication. In 2006, one patient, with 2 small lesions in the left lobe after surgery, was administered one dose of 4.58 MBq of ¹⁸⁸Re-Lipiodol: 90 % of the activity (4.122 MBq) was injected selectively in the artery feeding the tumour, delivering 82.9 Gy of radiation dose to the tumour and 26.8 Gy to the normal liver parenchyma; while 10 % of the activity (458 MBq) was injected in the left hepatic artery, which, even if it had gone completely to the normal liver parenchyma, would have delivered 2.98 Gy of radiation to it, thereby keeping the total radiation to the normal liver parenchyma less than 30 Gy [69].

Therapy was well tolerated, and the lesions were completely ablated with a single dose. The patient was disease-free for the time of follow-up (14 months); to compare to the 4-month median survival with post-surgical recurrences. Another patient with multiple intrahepatic recurrences after radiofrequency ablation was treated with an injection of 7.03 GBq, delivering 100.03 Gy to the tumour [70]. The patient remained disease-free 18 months after treatment (time of follow-up), without any adverse effect.

For patients awaiting liver transplantation, preliminary studies on intra-arterial injection of ^{131}I -labelled Lipiodol have demonstrated encouraging results [71, 72]. A study by Lambert *et al.* compared ^{131}I -Lipiodol with ^{188}Re -Lipiodol [73]. 21 patients received 2.1 GBq of ^{131}I -Lipiodol and 5 patients received 4.1 GBq of ^{188}Re -Lipiodol. 20 patients underwent transplantation and the other 2 died while on the waiting list. 20 % of transplanted patients suffered recurrent disease with a mean recurrence-free survival of 19.7 months (mean follow-up of 20.1 months). In this study ^{188}Re compared favorably to ^{131}I , thanks to its shorter half-life. Patients were eligible for transplantation after only 1 week, as compared with the 4-week interval with ^{131}I , due to radioprotection issues. These results advocate for larger trials, involving more patients.

DOSIMETRY

Main organs at risk in transarterial radionuclide therapy are liver (68 %), lungs (32 %) and bone marrow with their respective maximum-tolerated doses of: 30, 12 and 1.5 Gy. To avoid reaching these limits, and calculate the dose to the tumour, some authors used a scout dose of ^{188}Re -Lipiodol of 185 MBq and injected a patient-specific dosimetry-based therapeutic dose, while other used a fixed-activity dose. In their feasibility study with advanced cirrhotic patients, Lambert *et al.* administered a 3.7 ± 0.2 GBq ^{188}Re -Lipiodol dose in the hepatic artery to 12 patients; the absorbed doses to the liver, lungs, kidney, and thyroid were 7.6 ± 2.9 , 4.8 ± 2.6 , 0.8 ± 0.7 , and 0.2 ± 0.1 Gy (mean \pm SD), respectively [63]. 36.2 ± 5.7 % of the activity was excreted in the urine 52 h after injection. Moreover, the dose rate at 1 m was less than $20 \mu\text{Sv/h}$, enabling outpatient treatment.

Regarding the dose to the tumour, Bernal *et al.* found that a threshold dose of 30 Gy might lead to enhance survival [66]. Indeed, patients receiving a dose lower than 30 Gy (median 18Gy) had a median

survival of less than 5 months, when patient receiving a higher dose than 30 Gy (median 56.8 Gy) had a median survival of 15 months. It has also been postulated that rhenium-188 might be more efficient for the treatment of small tumours of millimeter through centimeter dimensions, but would be relatively less effective in the treatment of very small micro-metastases as well as larger macroscopic tumours [74]. A mathematical model determined the optimal diameter of the tumour to be 26 mm, to reach the maximal cure probability [75].

Comparing the various therapeutic isotopes, rhenium-188 is said to be equal to or even superior to yttrium-90 or lutetium-177 [76]. In a rat liver dosimetry model, comparing ^{131}I , ^{90}Y , ^{188}Re and ^{166}Ho , the last two seem to be safer and more effective for radionuclide therapy of HCC compared to ^{131}I and ^{90}Y [77].

In patients [78], when compared with ^{131}I -Lipiodol, ^{188}Re -Lipiodol induces fewer cytotoxic effects and shows significantly lower total patient body doses (1.04 Gy vs. 1.46 Gy) for an expected higher tumour-killing effect. According to MIRDose calculations, ^{188}Re -Lipiodol and ^{131}I -Lipiodol may be expected to have the same biological effect on the tumour with an ^{188}Re activity 60 % higher than the ^{131}I activity.

Another important point concerning the dose to the tumour and the whole liver is the way to inject radiolabelled Lipiodol. Some authors [59] are in favour of a supra-selective injection, as close to the feeding artery as possible, while others [61] advocate for a non-selective injection. Advantage of the first modality would be a higher dose to the tumour and limiting dose to the healthy liver, but the second modality would enable the targeting of occult (metachronous) tumours, at the expense of an irradiation of non-tumorous tissues. This second approach should be reserved for patients with sufficient liver function.

FUTURE DEVELOPMENTS

Combined Treatments

Combining treatment modalities could be a way to increase efficacy and/or decrease side effects, and appears to be highly attractive. In a clinical trial with ^{131}I -Lipiodol, combination with low dose cisplatin was shown to improve response rate compared to ^{131}I -Lipiodol alone, 90 % vs. 40 % respectively [79]. In a phase II trial, combination of ^{131}I -Lipiodol and cisplatin

was proven to be effective with an objective response rate of 57 % and a 1-year survival of $73 \pm 7\%$ [80].

With rhenium-188, there is still no clinical trial investigating the combination with cytotoxic drugs, but there are highly promising results *in vitro* and in animal models. In different HCC cell lines, Pracht *et al.* demonstrated additivity or even synergy between ¹⁸⁸Re and sorafenib, a multikinase inhibitor, which is the gold-standard for advanced stage HCC [81]. In another study with HepG2 cells, a transient mild supra-additive effect was demonstrated with 5-FU, while no effect was obtained with topotecan or gemcitabine [82]. On the contrary, in cholangiocarcinoma (CCA) cells, gemcitabine increased the efficacy of ¹⁸⁸Re irradiation [83]. Interestingly, with yttrium-90, gemcitabine showed synergistic effect both for HCC and CCA cell lines, while oxaliplatin showed synergy only on CCA, and sorafenib and paclitaxel had antagonist effects in all cell lines [84].

In hepatoma-bearing rats, it has been shown that pretreatment with dexamethasone and tamoxifen could lead to a significant increase (+ 44 %) in tumour uptake [85].

Other Indications

Hepatocellular carcinoma is the main primary tumour of the liver, but other tumours may occur within the liver - either primary, such as cholangiocarcinoma (CCA) or metastases from various primary tumours [2] – and could be potential target for transarterial radionuclide therapy with ¹⁸⁸Re-Lipiodol. ⁹⁰Y-microspheres have been investigated with success in both primary and secondary liver tumours [55]. Lipiodol has shown predominant accumulation and longer retention in HCC and in hyperarterialized liver metastases, such as gastroenteropancreatic neuroendocrine tumours, and has thus been widely used in TACE in these indications [86]. TACE with Lipiodol has also been demonstrated to be safe and efficient in intrahepatic cholangiocarcinomas [87], but similar data with ¹³¹I-Lipiodol are scarce. Concerning CCA, results are contradictory. In a study including a large CCA patient, Risse *et al.* obtained a stabilisation of the disease [88], while a pilot study including 8 CCA led to poor results, with only one CCA retaining ¹³¹I-Lipiodol [89]. Regarding metastases, in the same study, Risse *et al.* also treated one patient with multiple breast cancer metastases leading to significant reduction in number and size [88]. A case report on ¹³¹I-Lipiodol treatment of renal cell carcinoma hepatic metastases also

suggests a possible interest in this indication [90]. *In vitro* efficacy in colorectal metastatic cell lines was also demonstrated [91]. With all these preliminary results, ¹³¹I-Lipiodol was thus not recommended for CCA therapy, but could be used for liver metastases [92]. Based on these data, ¹⁸⁸Re-Lipiodol could be of potential use for some of these indications. Clinical trials are therefore required to assess its interest.

CONCLUSIONS

There have been many methods under preclinical and clinical investigation to treat patients with secondary or primary liver cancer, and particularly hepatocellular carcinoma. Transarterial radionuclide therapy with ¹⁸⁸Re-Lipiodol is a relatively inexpensive, safe and a promising treatment for HCC. Preliminary encouraging findings have now to be confirmed in large randomised trials, being compared with other approaches, such as trans-arterial chemoembolization, ⁹⁰Y-microspheres and/or targeted therapies, to assess the place of ¹⁸⁸Re-Lipiodol in the therapeutic armamentarium. Future treatment strategies may rely on the combination of these modalities.

ACKNOWLEDGMENTS

The authors thank Labex IRON (Grant no. ANR-11-LABX-0018) for financial support.

REFERENCES

- [1] London WT, McGlynn KA. Liver cancer. In: Schottenfeld D, Fraumeni J Jr, eds. Cancer Epidemiology and Prevention. 3rd ed. New York: Oxford University Press 2006; 763-86. <https://doi.org/10.1093/acprof:oso/9780195149616.003.0039>
- [2] Ahmed I, Lobo DN. Malignant tumours of the liver. *Surgery (Oxford)* 2009; 27: 30-7. <https://doi.org/10.1016/j.mpsur.2008.12.005>
- [3] Torre LA, Bray F, Siegel RL, Ferlay J, Lortet-Tieulent J, Jemal A. Global cancer statistics, 2012. *CA Cancer J Clin* 2015; 65: 87-108. <https://doi.org/10.3322/caac.21262>
- [4] Plummer M, de Martel C, Vignat J, Ferlay J, Bray F, Franceschi S. Global burden of cancers attributable to infections in 2012: a synthetic analysis. *Lancet Glob Health* 2016; 4: e609-16. [https://doi.org/10.1016/S2214-109X\(16\)30143-7](https://doi.org/10.1016/S2214-109X(16)30143-7)
- [5] De Martel C, Maucourt-Boulch D, Plummer M, Franceschi S. Worldwide relative contribution of hepatitis B and C viruses in hepatocellular carcinoma. *Hepatology* 2015; 62: 1190-200. <https://doi.org/10.1002/hep.27969>
- [6] Bhattacharyya GS, Babu KG, Malhotra H, Ranade AA, Murshed S, Datta D. Hepatocellular carcinoma in India. *Chin Clin Oncol* 2013; 2: 41-5.
- [7] Ikeda M, Mitsunaga S, Shimizu S, Ohno I, Takahashi H, Okuyama H, *et al.* Current status of hepatocellular carcinoma in Japan. *Chin Clin Oncol* 2013; 2: 40-9.
- [8] Baffy G, Brunt EM, Caldwell SH. Hepatocellular carcinoma in non-alcoholic fatty liver disease: an emerging menace, J

- Hepatol 2012; 56: 1384-91.
<https://doi.org/10.1016/j.jhep.2011.10.027>
- [9] Bertino G, Demma S, Ardiri A, Proiti M, Gruttadauria S, Toro A, *et al.* Hepatocellular carcinoma: novel molecular targets in carcinogenesis for future therapies. *Biomed Res Int* 2014; 2014: 203693. doi: 10.1155/2014/203693.
<https://doi.org/10.1155/2014/203693>
- [10] Goulté N, Sogni P, Bendersky N, Barbare JC, Bruno Falissard B, Farges O. Geographical variations in incidence, management and survival of hepatocellular carcinoma in a Western country. *J Hepatol* 2017; 66: 537-44.
<https://doi.org/10.1016/j.jhep.2016.10.015>
- [11] Schwartz M, Roayaie S, Konstadoulakis M. Strategies for the management of hepatocellular carcinoma. *Nat Clin Pract Oncol* 2007; 4: 424-32.
<https://doi.org/10.1038/ncponc0844>
- [12] Thomas MB, Zhu AX. Hepatocellular carcinoma: the need for progress. *J Clin Oncol* 2005; 23: 2892-99.
<https://doi.org/10.1200/JCO.2005.03.196>
- [13] Arciero CA, Sigurdson ER. Liver-directed therapies for patients with primary liver cancer and hepatic metastases. *Curr Treat Options Oncol* 2006; 7: 399-409.
<https://doi.org/10.1007/s11864-006-0008-7>
- [14] Wörns MA, Weinmann A, Schuchmann M, Galle PR. Systemic therapies in hepatocellular carcinoma. *Dig Dis* 2009; 27: 175-88.
<https://doi.org/10.1159/000218351>
- [15] Keane FK, Wo JY, Zhu AX, Hong TS. Liver-directed radiotherapy for hepatocellular carcinoma. *Liver Cancer* 2016; 5: 198-209.
- [16] Gallicchio R, Nardelli A, Mainenti P, Nappi A, Capacchione D, Simeon V, *et al.* Therapeutic strategies in HCC: radiation modalities. *Bio Med Res Int* 2016, 2016: 1295329.
<https://doi.org/10.1155/2016/1295329>
- [17] Giunchedi P, Maestri M, Gavini E, Dionigi P, Rassa G. Transarterial chemoembolization of hepatocellular carcinoma-agents and drugs: an overview. Part 2. *Expert Opin Drug Deliv* 2013; 10: 799-810.
<https://doi.org/10.1517/17425247.2013.796359>
- [18] Raoul JL, Boucher E, Rolland Y, Garin E. Treatment of hepatocellular carcinoma with intra-arterial injection of radionuclides. *Nat Rev Gastroenterol Hepatol* 2010; 7: 41-49.
<https://doi.org/10.1038/nrgastro.2009.202>
- [19] Burrill J, Hafeli U, Liu DM. Advances in radioembolization - embolics and isotopes. *J Nucl Med Radiat Ther* 2011; 2: 107-12.
<https://doi.org/10.4172/2155-9619.1000107>
- [20] Nakakuma K, Tashiro S, Hiraoka T, Ogata K, Ootsuka K. Hepatocellular carcinoma and metastatic cancer detected by iodized oil. *Radiology* 1985; 154: 15-7.
<https://doi.org/10.1148/radiology.154.1.2981111>
- [21] Fairlie NC, Adam AN. Case report: persistence of Lipiodol for 13 months in metastatic deposits in the liver on computed tomography. *Clin Radiol* 1991; 44: 273-74.
[https://doi.org/10.1016/S0009-9260\(05\)80196-5](https://doi.org/10.1016/S0009-9260(05)80196-5)
- [22] Liebster J, Kocandrlje V. Exchange labelling of 'Lipiodol' ultra fluids with Iodine-131 and its intra-lymphatic administration with a fistula on the thoracic duct. *Nature* 1964; 203: 777-8.
<https://doi.org/10.1038/203777a0>
- [23] Lintia-Gaultier A, Perret C, Ansquer C, Eugène T, Kraeber-Bodéré F, Frampas E. Intra-arterial injection of 131I-labeled Lipiodol for advanced hepatocellular carcinoma: a 7 years' experience. *Nucl Med Commun* 2013; 34: 674-81.
<https://doi.org/10.1097/MNM.0b013e32836141a0>
- [24] Raoul JL, Boucher E, Roland Y, Garin E. 131-iodine Lipiodol therapy in hepatocellular carcinoma. *Q J Nucl Med Mol Imaging* 2009; 53: 348-55.
- [25] Lopez A, Noiret N, Garin E, Lepareur N. Mixed-ligand complexes of yttrium-90 dialkylthiocarbamates with 1,10-phenanthroline as a possible agent for therapy of hepatocellular carcinoma. *Appl Radiat Isot* 2014; 94: 241-46.
<https://doi.org/10.1016/j.apradiso.2014.08.015>
- [26] Lambert B, Bacher K, Defreyne L. Rhenium-188 based radiopharmaceuticals for treatment of liver tumours. *Q J Nucl Med Mol Imaging* 2009; 53: 305-10.
- [27] Wang SJ, Lin WY, Chen MN, Hsieh BT, Shen LH, Tsai ZT, *et al.* Radiolabelling of Lipiodol with generator-produced ¹⁸⁸Re for hepatic tumor therapy. *Appl Radiat Isot* 1996; 47: 267-71.
[https://doi.org/10.1016/0969-8043\(95\)00300-2](https://doi.org/10.1016/0969-8043(95)00300-2)
- [28] Wang SJ, Lin WY, Chen MN, Hsieh BT, Shen LH, Tsai ZT, *et al.* Biodistribution of Rhenium-188 Lipiodol infused via the hepatic artery of rats with hepatic tumours. *Eur J Nucl Med* 1996; 23: 13-7.
<https://doi.org/10.1007/BF01736984>
- [29] Jackson TW, Koshima M, Lambrecht RM. Rhenium diaminedithiol complexes. III Lipophilic ligands for endoradiotherapeutic radiopharmaceuticals. *Aust J Chem* 2000; 53: 983-87.
<https://doi.org/10.1071/CH96073>
- [30] Jeong JM, Kim YJ, Lee YS, Ko JI, Son M, Lee DS, *et al.* Lipiodol solution of a lipophilic agent, ¹⁸⁸Re-TDD, for the treatment of liver cancer. *Nucl Med Biol* 2001; 28: 197-204.
[https://doi.org/10.1016/S0969-8051\(00\)00208-0](https://doi.org/10.1016/S0969-8051(00)00208-0)
- [31] Lee YS, Jeong JM, Kim YJ, Chung JW, Park JH, Suh YG, *et al.* Synthesis of ¹⁸⁸Re-labelled long chain alkyl diaminedithiol for therapy of liver cancer. *Nucl Med Com* 2002; 23: 237-42.
<https://doi.org/10.1097/00006231-200203000-00006>
- [32] Paeng JC, Jeong JM, Yoon CJ, Lee YS, Suh YG, Chung JW, *et al.* Lipiodol solution of ¹⁸⁸Re-HDD as a new therapeutic agent for transhepatic arterial embolization in liver cancer: preclinical study in a rabbit liver cancer model. *J Nucl Med* 2003; 44: 2033-8.
- [33] Lee YS, Jeong JM, Kim YJ, Chang YS, Lee HJ, Son M, *et al.* Development of acetylated HDD kit for preparation of ¹⁸⁸Re-HDD/Lipiodol. *Appl Radiat Isot* 2007; 65: 64-9.
<https://doi.org/10.1016/j.apradiso.2006.07.008>
- [34] Banka VK, Moon SH, Jeong JM, Seelam SR, Lee YS, Kim YJ, *et al.* Development of 4-hexadecyl-4,7-diaza-1,10-decanedithiol (HDD) kit for the preparation of the liver cancer therapeutic agent Re-188-HDD/lipiodol. *Nucl Med Biol* 2015; 42: 317-22.
<https://doi.org/10.1016/j.nuclmedbio.2014.11.013>
- [35] Luo T, Hsieh BT, Wang SJ, Lin WY, Lee TW, Shen LH, *et al.* Preparation and biodistribution of rhenium-188 ECD/Lipiodol in rats following hepatic arterial injection. *Nucl Med Biol* 2004; 31: 671-77.
<https://doi.org/10.1016/j.nuclmedbio.2004.02.005>
- [36] Luo TY, Shih YS, Chen CY, Tang IC, Wu YL, Kung HC, *et al.* Evaluating the Potential of ¹⁸⁸Re-ECD/Lipiodol as a therapeutic radiopharmaceutical by intratumoral injection for hepatomatreatment. *Cancer Biother Radiopharm* 2009; 24: 535-41.
<https://doi.org/10.1089/cbr.2008.0603>
- [37] Wang GQ, Zhang J, Luo SZ, Wang N, Wei HY, Wang WJ, *et al.* Synthesis and primary biological evaluation of ¹⁸⁸Re-NEMPTDD. *J Radioanal Nucl Chem* 2008; 277: 365-9.
<https://doi.org/10.1007/s10967-007-7033-2>
- [38] Tang IC, Luo TY, Liu SW, Chan SH, Kung HC, Peng CL, *et al.* Synthesis and application of ¹⁸⁸Re-MN-16ET/Lipiodol in a hepatocellular carcinoma animal model. *Nucl Med Biol* 2011; 38: 1043-52.
<https://doi.org/10.1016/j.nuclmedbio.2011.03.005>
- [39] Huang PW, Tsai SC, Luo TY, Kao CH, Lin WY. Therapeutic efficacy of ¹⁸⁸Re-MN-16ET Lipiodol in an animal model of hepatocellular carcinoma. *Ann Nucl Med* 2013; 27: 532-7.
<https://doi.org/10.1007/s12149-013-0717-5>

- [40] Lin WY, Luo TY, Tsai SC, Kao CH, Tang IC, Huang PW. A comparison of Re-188-MN-16ET-Lipiodol and transcatheter arterial chemoembolization in the treatment of hepatoma: an animal study. *Nucl Med Biol* 2013; 40: 437-41. <https://doi.org/10.1016/j.nucmedbio.2012.11.007>
- [41] Boschi A, Uccelli L, Duatti A, Colamussi P, Cittanti C, Filice A, *et al.* A kit formulation for the preparation of ¹⁸⁸Re-Lipiodol: preclinical studies and preliminary therapeutic evaluation in patients with unresectable hepatocellular carcinoma. *Nucl Med Commun* 2004; 25: 691-9. <https://doi.org/10.1097/01.nmm.0000130241.22068.45>
- [42] Lepareur N, Garin E, Noiret N, Herry JY. A kit formulation for the labelling of Lipiodol with generator-produced ¹⁸⁸Re. *J Label Compd Radiopharm* 2004; 47: 857-67. <https://doi.org/10.1002/jlcr.863>
- [43] Lepareur N, Ardisson V, Noiret N, Garin E. 188Re-SSS/Lipiodol: development of a potential treatment for HCC from bench to bedside. *Int J Mol Imaging*, 2012, Article ID 278306, 9 pages. <https://doi.org/10.1155/2012/278306>
- [44] Saw MM, Kurz P, Agorastos N, Hor TSA, Sundram FX, Yan YK, *et al.* Complexes with the *fac*-[M(CO)₃]⁺ (M = ^{99m}Tc, Re) moiety and long alkyl chain ligands as Lipiodol surrogates. *Inorg Chim Acta* 2006; 359: 4087-94. <https://doi.org/10.1016/j.ica.2006.04.023>
- [45] Wang SJ, Luo TY, Hsieh BT, Cheng KY, Lin WY, Shen LH, *et al.* A new technique for labeling of Lipiodol with ¹⁸⁸Re in the treatment of hepatic tumor, *J Radioanal Nucl Chem* 2004; 261: 189-93. <https://doi.org/10.1023/B:JRNC.0000030955.44982.70>
- [46] Andreeff M, Wunderlich G, Behge K, Schönmath T, Kotzerke J. β -radiation exposure with ¹⁸⁸Re-labelled pharmaceuticals. *Nuklearmedizin* 2005; 44: 94-8.
- [47] Uccelli L, Pasquali M, Boschi A, Giganti M, Duatti A. Automated preparation of Re-188 Lipiodol for the treatment of hepatocellular carcinoma. *Nucl Med Biol* 2011; 38: 207-13. <https://doi.org/10.1016/j.nucmedbio.2010.08.011>
- [48] Lepareur N, Ardisson V, Noiret N, Boucher E, Raoul JL, Clément B, *et al.* Automation of labelling of Lipiodol with high-activity generator-produced ¹⁸⁸Re. *Appl Radiat Isot* 2011; 69: 426-30. <https://doi.org/10.1016/j.apradiso.2010.11.001>
- [49] Lepareur N, Laffont S, Ardisson V, Noiret N, Garin E. Reduction of β -radiation exposure during preparation of ¹⁸⁸Re-labelled Lipiodol for hepatocellular carcinoma treatment. *Nucl Med Commun* 2012; 33: 205-8. <https://doi.org/10.1097/MNM.0b013e32834e7580>
- [50] Bozkurt MF, Salanci BV, Ugur O. Intra-arterial radionuclide therapies for liver tumors. *Semin Nucl Med* 2016; 46: 324-39. <https://doi.org/10.1053/j.semnuclmed.2016.01.008>
- [51] Hilgard P, Muller S, Hamami M, Sauerwein WS, Haberkorn U, Gerken G, *et al.* Selective internal radiotherapy (radioembolization) and radiation therapy for HCC-current status and perspectives. *Z Gastroenterol* 2009; 47: 37-54. <https://doi.org/10.1055/s-2008-1028002>
- [52] Raoul JL, Duvauferrier R, Bourguet P, Bretagne JF, Coornaert S, Darnault P, *et al.* Lipiodolized angiography in hepatocellular carcinomas. Contribution of iodine-131-labelled Lipiodol. *J Radiol* 1986; 67: 797-801.
- [53] Park CH, Suh JH, Yoo HS, Lee JT, Kim DI. Evaluation of intrahepatic I-131 ethiodol on a patient with hepatocellular carcinoma. Therapeutic feasibility study. *Clin Nucl Med* 1986; 11: 514-7. <https://doi.org/10.1097/00003072-198607000-00015>
- [54] Ahmadzadehfar H, Sabet A, Wilhelm K, Biersack HJ, Risse J. Iodine-131-Lipiodol therapy in hepatic tumours. *Methods* 2011; 55: 246-52. <https://doi.org/10.1016/j.ymeth.2011.05.003>
- [55] Salem R, Thurston KG. Radioembolization with yttrium-90 microspheres: a State-of-the-Art brachytherapy treatment for primary and secondary liver malignancies Part 3: comprehensive literature review and future direction, *J Vasc Interv Radiol* 2006; 17: 1571-94. <https://doi.org/10.1097/01.RVI.0000236744.34720.73>
- [56] Sundram FX, Yu SWK, Jeong JM, Somanesan S, Premaraj J, Saw MM, *et al.* ¹⁸⁸Rhenium-TDD-Lipiodol in treatment of inoperable primary hepatocellular carcinoma – a case report. *Ann Acad Med Singapore* 2001; 30: 542-5.
- [57] Paeng JC, Jeong JM, Yoon CJ, Lee YS, Suh YG, Chung JW, *et al.* Lipiodol solution of ¹⁸⁸Re-HDD as a new therapeutic agent for transhepatic arterial embolization in liver cancer: preclinical study in a rabbit liver cancer model. *J Nucl Med* 2003; 44: 2033-8.
- [58] Keng GH, Sundram FX, Yu SW, Somanesan S, Premaraj J, Oon CJ, *et al.* Preliminary experience in radionuclide therapy of hepatocellular carcinoma using hepatic intra-arterial radioconjugates. *Ann Acad Med Singapore* 2002; 31: 382-6.
- [59] Sundram F, Chau TCM, Onkhuudai P, Bernal P, Padhy AK. Preliminary results of transarterial rhenium-188 HDD Lipiodol in the treatment of inoperable primary hepatocellular carcinoma. *Eur J Nucl Med Mol Imaging* 2004; 31: 250-7. <https://doi.org/10.1007/s00259-003-1363-2>
- [60] Lambert B, Bacher K, Defreyne L, Van Vlierberghe H, Jeong JM, Wang RF, *et al.* ¹⁸⁸Re-HDD/lipiodol therapy for hepatocellular carcinoma: an activity escalation study. *Eur J Nucl Med Mol Imaging* 2006; 33: 344-52. <https://doi.org/10.1007/s00259-005-1954-1>
- [61] Lambert B, Bacher K, Defreyne L, Gemmel F, Van Vlierberghe H, Jeong JM, *et al.* ¹⁸⁸Re-HDD/Lipiodol therapy for hepatocellular carcinoma: a phase I clinical trial. *J Nucl Med* 2005; 46: 60-6.
- [62] Ardisson V, Lepareur N, Laffont S, Garin E. ¹⁸⁸Re-SSS/Lipiodol for hepatocellular carcinoma: a phase 1 clinical trial. *Q J Nucl Med Mol Imaging* 2012; 56(Suppl. 1): 54.
- [63] Lambert B, Bacher K, De Keukeleire K, Smeets P, Colle I, Jeong JM, *et al.* ¹⁸⁸Re-HDD/Lipiodol for treatment of hepatocellular carcinoma: a feasibility study in patients with advanced cirrhosis. *J Nucl Med* 2005; 46: 1326-32.
- [64] Kumar A, Bal C, Srivastava DN, Acharya SK, Thulker SP, Sharma S, *et al.* Transarterial radionuclide therapy with Re-188-HDD-lipiodol in case of unresectable hepatocellular carcinoma with extensive portal vein thrombosis. *Eur J Radiology Extra* 2005; 56: 55-9. <https://doi.org/10.1016/j.ejrex.2005.07.016>
- [65] Bernal P, Raoul JL, Vidmar G, Sereegotov E, Sundram FX, Kumar A, *et al.* Intra-arterial Rhenium-188 Lipiodol in the treatment of inoperable hepatocellular carcinoma: results of an IAEA-sponsored multinational study. *Int J Radiat Oncol Biol Phys* 2007; 69: 1448-55. <https://doi.org/10.1016/j.ijrobp.2007.05.009>
- [66] Bernal P, Raoul JL, Stare J, Sereegotov E, Sundram FX, Kumar A, *et al.* International Atomic Energy Agency-sponsored multinational study of intra-arterial rhenium-188-labeled Lipiodol in the treatment of inoperable hepatocellular carcinoma: results with special emphasis on prognostic value of dosimetric study. *Semin Nucl Med* 2008; 38: S40-5. <https://doi.org/10.1053/j.semnuclmed.2007.10.006>
- [67] Kumar A, Srivastava DN, Chau TTM, Long HD, Bal C, Chandra P, *et al.* Inoperable hepatocellular carcinoma: transarterial ¹⁸⁸Re HDD-labeled iodized oil for treatment-prospective multicenter clinical trial. *Radiology* 2007; 243: 509-19. <https://doi.org/10.1148/radiol.2432051246>
- [68] Furtado R, Crawford M, Sandroussi C. Systematic review and meta-analysis of adjuvant ¹³¹I Lipiodol after excision of hepatocellular carcinoma. *Ann Surg Oncol* 2014; 21: 2700-7. <https://doi.org/10.1245/s10434-014-3511-2>

- [69] Kumar A, Srivastava DN, Bal C. Management of postsurgical recurrence of hepatocellular carcinoma with Rhenium 188–HDD labeled iodized oil. *J Vasc Interv Radiol* 2006; 17: 157-61. <https://doi.org/10.1097/01.RVI.0000195321.20579.F2>
- [70] Kumar A, Bal C, Srivastava DN, Thulkar SP, Sharma S, Acharya SK, *et al.* Management of multiple intrahepatic recurrences after radiofrequency ablation of hepatocellular carcinoma with rhenium-188–HDD-Lipiodol. *Eur J Gastroenterol Hepatol* 2006; 18: 219-23. <https://doi.org/10.1097/00042737-200602000-00016>
- [71] Brans B, De Winter F, Defreyne L, Troisi R, Vanlangenhove P, Van Vlierberghe H, *et al.* The anti-tumoral activity of neoadjuvant intra-arterial ¹³¹I-Lipiodol treatment for hepatocellular carcinoma: a pilot study. *Cancer Biother Radiopharm* 2004; 16: 333-8. <https://doi.org/10.1089/108497801753131417>
- [72] Raoul JL, Messner M, Boucher E, Bretagne JF, Campion JP, Boudjema K. Preoperative treatment of hepatocellular carcinoma with intra-arterial injection of ¹³¹I-labelled Lipiodol. *Br J Surg* 2003; 90: 1379-83. <https://doi.org/10.1002/bjs.4271>
- [73] Lambert B, Praet M, Vanlangenhove P, Troisi R, de Hemptinne B, Gemmel F, *et al.* Radiolabeled Lipiodol therapy for hepatocellular carcinoma in patients awaiting liver transplantation: pathology of the explant livers and clinical outcome. *Cancer Biother Radiopharm* 2005; 20: 209-14. <https://doi.org/10.1089/cbr.2005.20.209>
- [74] Unak P, Cetinkaya B, Unak I. Absorbed dose estimates at the cellular level for ¹⁸⁶Re and ¹⁸⁸Re. *Radiat Phys Chem* 2005; 73: 137-46. <https://doi.org/10.1016/j.radphyschem.2004.10.002>
- [75] O'Donoghue JA, Bardies M, Wheldon TE. Relationships between tumour size and curability for uniformly targeted therapy with beta-emitting radionuclides. *J Nucl Med* 1995; 36: 1902-9.
- [76] Ferro-Flores G, Arteaga de Murphy C. Pharmacokinetics and dosimetry of ¹⁸⁸Re-pharmaceuticals. *Adv Drug Deliv Reviews* 2008; 60: 1389-401. <https://doi.org/10.1016/j.addr.2008.04.008>
- [77] Xie T, Liu Q, Zaidi H. Evaluation of S-values and dose distributions for ⁹⁰Y, ¹³¹I, ¹⁶⁶Ho, and ¹⁸⁸Re in seven lobes of the rat liver. *Med Phys* 2012; 39: 1462-72. <https://doi.org/10.1118/1.3681009>
- [78] De Ruyck K, Lambert B, Bacher K, Gemmel F, De Vos F, Vral A, *et al.* Biologic dosimetry of ¹⁸⁸Re-HDD/Lipiodol versus ¹³¹I-Lipiodol therapy in patients with hepatocellular carcinoma. *J Nucl Med* 2004; 45: 612-8.
- [79] Brans B, van Laere K, Gemmel F, Defreyne L, Vanlangenhove P, Troisi R, *et al.* Combining iodine-131 Lipiodol therapy with low-dose cisplatin as a radiosensitizer: preliminary results in hepatocellular carcinoma. *Eur J Nucl Med* 2002; 29: 928-32. <https://doi.org/10.1007/s00259-002-0791-8>
- [80] Raoul JL, Boucher E, Olivier D, Guillygomarc'h A, Boudjema K, Garin E. Association of cisplatin and intra-arterial injection of ¹³¹I-Lipiodol in treatment of hepatocellular carcinoma: results of phase II trial. *Int J Radiat Oncol Biol Phys* 2006; 64: 745-50. <https://doi.org/10.1016/j.ijrobp.2005.09.007>
- [81] Pracht M, Edeline J, Lepareur N, Lenoir L, Ardisson V, Clément B, *et al.* *In vitro* demonstration of synergy/additivity between 188-Rhenium and Sorafenib on hepatoma lines: preliminary results. *Anticancer Res* 2013; 33: 3871-78.
- [82] Lambert B, De Ridder L, De Vos F, Slegers G, de Gelder V, Van de Wiele C, *et al.* Assessment of supra-additive effects of cytotoxic drugs and low dose rate irradiation in an *in vitro* model for hepatocellular carcinoma. *Can J Physiol Pharmacol* 2006; 84: 1021-8. <https://doi.org/10.1139/y06-055>
- [83] Wiesinger B, Farkas E, Kehlbach R, Bantleon R, Werner M, Wiskirchen J. Impact of rhenium-188, gemcitabine, and 5-fluorouracil on cholangiocellular carcinoma cells: an *in vitro* study. *Cardiovasc Intervent Radiol* 2009; 32: 737-44. <https://doi.org/10.1007/s00270-009-9563-1>
- [84] Edeline J, Coulouarn C, Crouzet L, Pracht M, Lepareur N, Clément B, *et al.* Gemcitabine and oxaliplatin, but not sorafenib or paclitaxel have a synergistic effect with Yttrium-90 in reducing primary liver cell viability. *J Vasc Interv Radiol* 2015; 26: 1874-8. <https://doi.org/10.1016/j.jvir.2015.06.032>
- [85] Becker S, Ardisson V, Lepareur N, Sergent O, Bayat S, Noiret N, *et al.* Increased Lipiodol uptake in hepatocellular carcinoma possibly due to increased membrane fluidity by dexamethasone and tamoxifen. *Nucl Med Biol* 2010; 37: 777-84. <https://doi.org/10.1016/j.nucmedbio.2010.03.013>
- [86] De Baere T, Arai Y, Lencioni R, Geschwind JF, Rilling W, Salem R, *et al.* Treatment of liver tumors with Lipiodol TACE: technical recommendations from experts' opinion. *Cardiovasc Intervent Radiol* 2016; 39: 334-43. <https://doi.org/10.1007/s00270-015-1208-y>
- [87] Herber S, Otto G, Schneider J, Manzl N, Kummer I, Kanzler S, *et al.* Transarterial chemoembolization (TACE) for inoperable intrahepatic cholangiocarcinoma. *Cardiovasc Intervent Radiol* 2007; 30: 1156-65. <https://doi.org/10.1007/s00270-007-9032-7>
- [88] Risse JH, Grünwald F, Strunk H, Kleinschmidt R, Bender H, Biersack HJ. I-131-Lipiodol therapy in liver neoplasms. *Hybridoma* 1999; 18: 83-5. <https://doi.org/10.1089/hyb.1999.18.83>
- [89] Novell JR, Green AJ, Hilson AJ, Dusheiko G, Dick R, Hobbs KE. Selective radionuclide localisation in primary liver tumours (pilot study). *HPB surgery: a world journal of hepatic, pancreatic and biliary surgery* 1994; 7: 185-200.
- [90] Stansby G, Bhattacharya S, Hilson AJ, Lane DM, Hobbs KE. Case report: localization of Lipiodol-radioiodine in hepatic metastases from renal cell carcinoma. *Br J Radiol* 1994; 67: 822-4. <https://doi.org/10.1259/0007-1285-67-800-822>
- [91] Al-Mufti RAM, Pedley RB, Marshall D, Begent RH, Hilson A, Winslet MC, *et al.* *In vitro* assessment of Lipiodol-targeted radiotherapy for liver and colorectal cancer cell lines. *Br J Cancer* 1999; 79: 1665-71. <https://doi.org/10.1038/sj.bjc.6690266>
- [92] Giammarile F, Bodei L, Chiesa C, Flux G, Forrer F, Kraeber-Bodere F, *et al.* EANM procedure guideline for the treatment of liver cancer and liver metastases with intra-arterial radioactive compounds. *Eur J Nucl Med Mol Imaging* 2011; 38: 1393-1406. <https://doi.org/10.1007/s00259-011-1812-2>
- [93] Bretagne JF, Raoul JL, Bourguet P, Duvauferrier R, Deugnier Y, Faroux R, *et al.* Hepatic artery injection of I-131-labeled Lipiodol. Part II. Preliminary results of therapeutic use in patients with hepatocellular carcinoma and liver metastases. *Radiology* 1988; 168: 547-50. <https://doi.org/10.1148/radiology.168.2.2839867>
- [94] Yoo HS, Lee JT, Kim KW, Kim BS, Choi HJ, Lee KS, *et al.* Nodular hepatocellular carcinoma. Treatment with subsegmental intraarterial injection of iodine 131-labeled iodized oil. *Cancer* 1991; 68: 1878-84. [https://doi.org/10.1002/1097-0142\(19911101\)68:9<1878::AID-CNCR2820680905>3.0.CO;2-D](https://doi.org/10.1002/1097-0142(19911101)68:9<1878::AID-CNCR2820680905>3.0.CO;2-D)
- [95] Raoul JL, Bretagne JF, Caucanas JP, Pariente EA, Boyer J, Paris JC, *et al.* Internal radiation therapy for hepatocellular carcinoma: results of a French multicenter Phase II trial of transarterial injection of iodine 131-labeled Lipiodol. *Cancer* 1992; 69: 346-52.

- [https://doi.org/10.1002/1097-0142\(19920115\)69:2<346::AID-CNCR2820690212>3.0.CO;2-E](https://doi.org/10.1002/1097-0142(19920115)69:2<346::AID-CNCR2820690212>3.0.CO;2-E)
- [96] Raoul JL, Guyader D, Bretagne JF, Duvauferrier R, Bourguet P, Bekhechi D, *et al.* Randomized controlled trial for hepatocellular carcinoma with portal vein thrombosis: intra-arterial iodine-131-iodized oil versus medical support. *J Nucl Med* 1994; 35: 1782-7.
- [97] Raoul JL, Guyader D, Bretagne JF, Heautot J, Duvauferrier R, Bourguet P, *et al.* Prospective randomized trial of chemoembolization versus intraarterial injection of ¹³¹I-labeled-iodized oil in the treatment of hepatocellular carcinoma. *Hepatology* 1997; 26: 1156-61.
- [98] Lau WY, Leung TWT, Ho SKW, Chan M, Machin D, Lau J, *et al.* Adjuvant intra-arterial iodine-131-labelled Lipiodol for resectable hepatocellular carcinoma: a prospective randomised trial. *Lancet* 1999; 353: 797. [https://doi.org/10.1016/S0140-6736\(98\)06475-7](https://doi.org/10.1016/S0140-6736(98)06475-7)
- [99] De Baere T, Taourel P, Tubiana JM, Kuoch V, Ducreux M, Lumbroso J, *et al.* Hepatic intraarterial ¹³¹I iodized oil for treatment of hepatocellular carcinoma in patients with impeded portal venous flow. *Radiology* 1999; 212: 665-8.
- [100] Boucher E, Corbinais S, Rolland Y, Bourguet P, Guyader D, Boudjema K, *et al.* Adjuvant intra-arterial injection of iodine-131-labeled Lipiodol after resection of hepatocellular carcinoma. *Hepatology* 2003; 38: 1237-41. <https://doi.org/10.1053/jhep.2003.50473>
- [101] Risse JH, Rabe C, Pauleit D, Reichmann K, Menzel C, Grünwald F, *et al.* Therapy of hepatocellular carcinoma with iodine-131-lipiodol. Results in a large German cohort. *Nuklearmedizin* 2006; 45: 185-92.
- [102] Boucher E, Garin E, Guyllygomarc'h A, Olivé D, Boudjema K, Raoul JL, Intra-arterial injection of iodine-131-labeled Lipiodol for treatment of hepatocellular carcinoma. *Radiation Oncol* 2007; 82: 76-82. <https://doi.org/10.1016/j.radonc.2006.11.001>
- [103] Marelli L, Shusang V, Buscombe JR, Cholongitas E, Stigliano R, Davies N, *et al.* Transarterial injection of ¹³¹I-Lipiodol, compared with chemoembolization, in the treatment of unresectable hepatocellular cancer. *J Nucl Med* 2009; 50: 871-77. <https://doi.org/10.2967/jnumed.108.060558>
- [104] Chua TC, Chu F, Butler P, Quinn RJ, Glenn D, Liauw W, *et al.* Intra-arterial iodine-131-Lipiodol for unresectable hepatocellular carcinoma. *Cancer* 2010; 116: 4069-77. <https://doi.org/10.1002/cncr.25283>
- [105] Chung AY, Ooi LL, Machin D, Tan SB, Goh BK, Wong JS, *et al.* Adjuvant hepatic intraarterial iodine-131-lipiodol following curative resection of hepatocellular carcinoma: a prospective randomized trial. *World J Surg* 2013; 37: 1356-61. <https://doi.org/10.1007/s00268-013-1970-4>
- [106] Gray B, Van Hazel G, Hope M, Burton M, Moroz P, Anderson J, *et al.* Randomised trial of SIR Spheres plus chemotherapy vs. chemotherapy alone for treating patients with liver metastases from primary large bowel cancer. *Ann Oncol* 2001; 12: 1711-20. <https://doi.org/10.1023/A:1013569329846>
- [107] Sangro B, Bilbao JI, Boan J, Martinez-Cuesta A, Benito A, Rodriguez J, *et al.* Radioembolization using ⁹⁰Y-resin microspheres for patients with advanced hepatocellular carcinoma. *Int J Radiat Oncol Biol Phys* 2006; 66: 792-800. <https://doi.org/10.1016/j.ijrobp.2006.05.065>
- [108] Ibrahim SM, Kulik L, Baker T, Ryu RK, Mulcahy MF, Abecassis M, *et al.* Treating and downstaging hepatocellular carcinoma in the caudate lobe with yttrium-90 radioembolization. *Cardiovasc Intervent Radiol* 2012; 35: 1094-101. <https://doi.org/10.1007/s00270-011-0292-x>
- [109] Chow PK, Poon DY, Khin MW, Singh H, Han HS, Goh AS, *et al.* Multicenter phase II study of sequential radioembolization-sorafenib therapy for inoperable hepatocellular carcinoma. *PLoS ONE* 2014; 9: e90909. <https://doi.org/10.1371/journal.pone.0090909>
- [110] Kim DY, Park BJ, Kim YH, Han KH, Cho SB, Cho KR, *et al.* Radioembolization with Yttrium-90 resin microspheres in hepatocellular carcinoma: a multicenter prospective study. *Am J Clin Oncol* 2015; 38: 495-501. <https://doi.org/10.1097/COC.0b013e3182a78dba>
- [111] Pitton MB, Kloeckner R, Ruckes C, Wirth GM, Eichhorn W, Wörns MA, *et al.* Randomized comparison of selective internal radiotherapy (SIRT) versus drug-eluting bead transarterial chemoembolization (DEB-TACE) for the treatment of hepatocellular carcinoma. *Cardiovasc Intervent Radiol* 2015; 38: 352-60. <https://doi.org/10.1007/s00270-014-1012-0>
- [112] Ricke J, Bulla K, Kolligs F, Peck-Radosavljevic M, Reimer P, Sangro B, *et al.* Safety and toxicity of radioembolization plus Sorafenib in advanced hepatocellular carcinoma: analysis of the European multicentre trial SORAMIC. *Liver Int* 2015; 35: 620-6. <https://doi.org/10.1111/liv.12622>
- [113] Edeline J, Crouzet L, Campillo-Gimenez B, Rolland Y, Pracht M, Guyllygomarc'h A, *et al.* Selective internal radiation therapy compared with sorafenib for hepatocellular carcinoma with portal vein thrombosis. *Eur J Nucl Med Mol Imaging* 2016; 43: 635-43. <https://doi.org/10.1007/s00259-015-3210-7>
- [114] Sohn JH, Choi HJ, Lee JT, Lee JD, Kim JH, Moon YM, *et al.* Phase II study of transarterial Holmium-166-chitosan complex treatment in patients with a single, large hepatocellular carcinoma. *Oncology* 2009; 76: 1-9. <https://doi.org/10.1159/000173735>

Received on 08-03-2017

Accepted on 24-03-2017

Published on 31-07-2017

<http://dx.doi.org/10.15379/2408-9788.2017.07>

© 2017 Lepareur and Garin; Licensee Cosmos Scholars Publishing House.

This is an open access article licensed under the terms of the Creative Commons Attribution Non-Commercial License (<http://creativecommons.org/licenses/by-nc/3.0/>), which permits unrestricted, non-commercial use, distribution and reproduction in any medium, provided the work is properly cited.