

Incidence of Incidental Finding of Mullerian Anomalies at Successful Term Pregnancies: A Three-Year Study in India

Suvarna Rai^{1,*}, Vijay Lakshmi Adapala², Nagaratna Kasukurti² and Tushara Bindu²

¹Department of Obstetrics and Gynecology, Malla Reddy Institute of Medical Sciences, Suraram Main Road, Quthubullapur, Hyderabad- 500055 India

²Department of OBG Malla Reddy Institute of Medical Sciences Hyderabad, India

Abstract: *Introduction:* Mullerian Anomalies are known to disturb the reproductive life of women immensely and adversely affect their obstetric outcomes too. Therefore, they get identified either during pubertal, early reproductive or antenatal period. Ultrasound diagnosis in pregnancy after first trimester is also very difficult. Very few anomalies get diagnosed after a successful term pregnancy incidentally during delivery. Their actual incidence varies from 1-10% but little is known about incidence of unidentified cases in successful term pregnancies. *Aim:* To determine the incidence of incidental finding of Mullerian Anomalies in successful term pregnancies

Methods: Over 3 year study period at a tertiary care centre we observed all women who delivered both by vaginal route and cesarean section for any Mullerian Anomaly. *Results:* Of the total 5124 women who delivered at our institute at term gestation, 3 women were excluded, as they were known cases of Mullerian anomalies on regular follow up at our institute. 11 women were identified with Mullerian Anomalies incidentally during delivery at term. 9 of them were referral cases. 5 cases of Arcuate Uterus, 2 cases of septate uterus, 2 cases of Unicornuate uterus, 1 case of bicornuate uterus and 1 case of agenesis of fallopian tube were found.

Conclusion: Mullerian Anomalies are seen occasionally incidentally in successful term pregnancies during delivery. They can be asymptomatic, silent and can have positive pregnancy outcomes. These incidences are crucial for counseling of patients and their families. Also, we must be on a look out for these diagnoses not only to identify co existing urological disturbances but also to help us improve their subsequent obstetric performances.

Keywords: Mullerian Anomalies, Incidental finding, Term Pregnancy, Incidence, Unicornuate Uterus.

INTRODUCTION

Mullerian anomalies are the commonest uterine anomalies and they are known to be associated with poor obstetric outcome. Most pregnancies are expected to complicate and only few of them reach term gestation. Of these, fewer go through pregnancy asymptotically and uneventfully and finally get identified incidentally during delivery.

The accuracy of ultrasound for the diagnosis of Mullerian Anomalies in gravid uterus is lesser as compared to the non gravid uterus. Thus, many mullerian anomalies go unnoticed in pregnancy despite serial ultrasound examinations. Also, because most other radiological methods are unsafe in pregnancy it is very difficult to identify them in patients who visit a hospital for the first time during antenatal period [1].

Most young girls with Mullerian anomalies present in early life with gynecological complaints like primary amenorrhea, dysmenorrhea and menorrhagia. Many others present in mid reproductive life with infertility

and recurrent pregnancy losses. A few more present during pregnancy with IUGR, preterm labor and pre eclampsia (due to associated renal anomalies) [2]. Very few miss these watershed areas and reach delivery uneventfully. Therefore, our aim was to find out how many patients with mullerian anomalies get diagnosed incidentally at successful term pregnancies.

METHODS

Our institute is a tertiary care hospital situated in urban Southern India receiving several referral cases from peripheral and rural primary and secondary health care centers in Telangana state.

We studied all women who delivered at our institute over a period of three years from January 2012 to January 2015 both by vaginal and cesarean route. Of these, all women who were known cases of Mullerian Anomalies taking regular treatment at our hospital were excluded. Those women who were diagnosed of mullerian anomalies incidentally during delivery were only included in the present study. American Society for Reproductive Medicine Classification System for Mullerian Anomalies [3] which is based on previous classification by Buttram and Gibbons [4] was followed to name and classify the Mullerian anomalies identified

*Address correspondence to this author at the Department of Obstetrics and Gynecology, Malla Reddy Institute of Medical Sciences, Suraram Main Road, Quthubullapur, Hyderabad- 500055 India; Tel: 091-9676945495; Fax: 040-64634232; E-mail: drsuvanarai@gmail.com

in these patients. Also, all cases underwent ultrasound of KUB region to look for associated renal anomalies.

We obtained the approval from Hospital Research Ethics Committee before commencing the study.

RESULTS

At our institute, we delivered 5124 patients over a three year study period from January 2012- January 2015 of which 3506 were delivered by vaginal route and 1618 were delivered by cesarean surgery. Of these, 328 deliveries were excluded from the present study in view of preterm deliveries, maternal mortalities, stillbirths, intrauterine deaths and neonatal deaths.

A total of 14 cases of Mullerian anomalies were identified of whom 3 were diagnosed of Mullerian anomalies earlier and were on regular treatment at our hospital. The remaining 11 Mullerian anomalies were found incidentally during vaginal and cesarean deliveries (Figure 1). These included 5 cases of Arcuate Uterus, 2 cases of septate uterus, 2 cases of Unicornuate uterus, 1 case of bicornuate uterus and 1 case of agenesis of fallopian tube. No cases of Uterus didelphus, DES related anomalies and agenesis/hypoplasia of cervical, vaginal and fundal region were identified (Table 1). 9 of these cases were unbooked patients and were first seen in late pregnancy. Neonatal outcome was also good in all these cases.

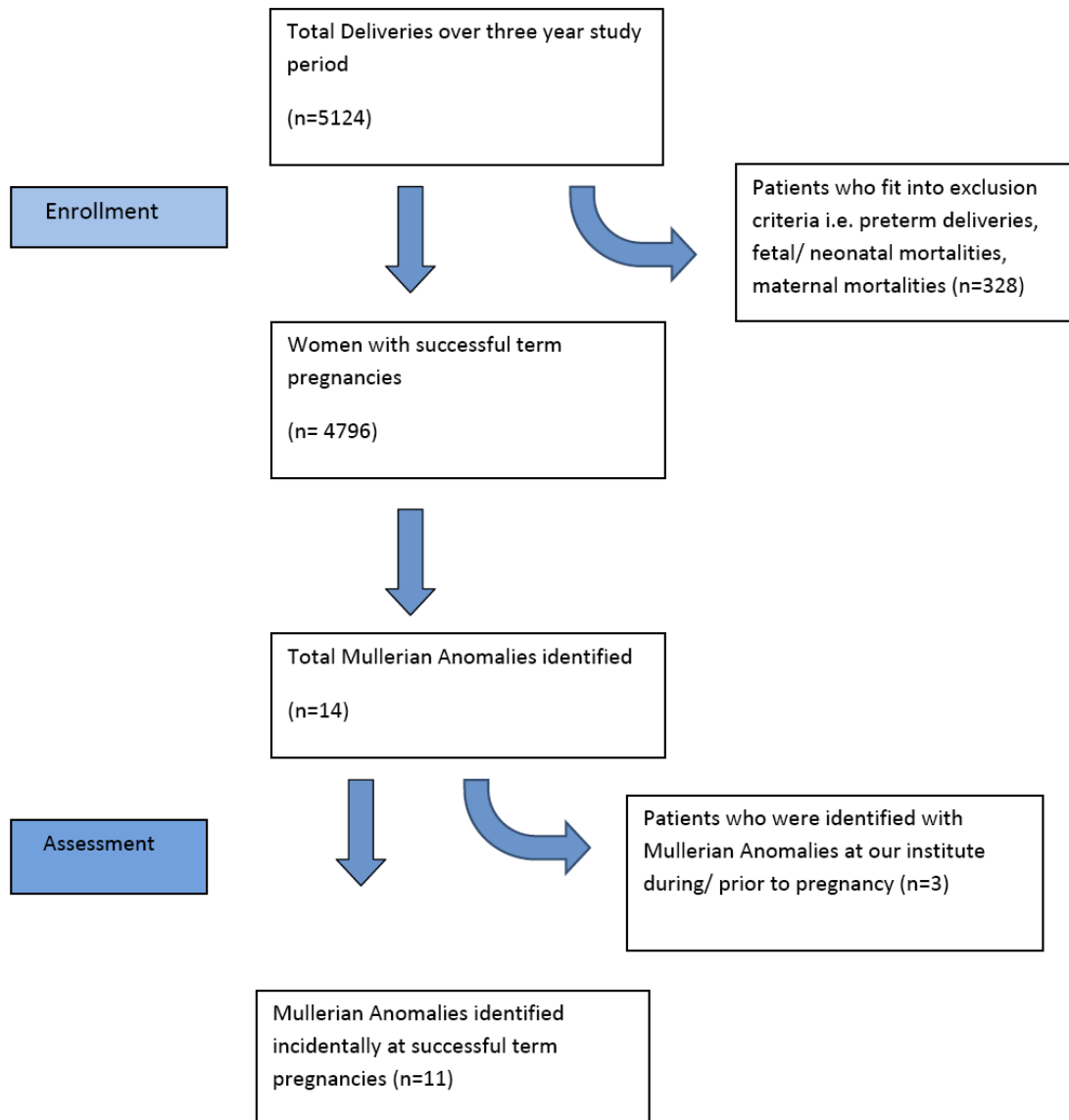


Figure 1: Flow of patients through the study.

Table 1: Distribution of Study Population and Outcome

| Mullerian Anomaly | Number of Cases (n=11) | Parity (weeks) | Mode of Delivery | Antenatal Events | Birth Weight (Kg) | Apgar (1 min, 5 min) |
|-----------------------------------|------------------------|----------------|-------------------|------------------------------|-------------------|----------------------|
| Hypoplasia/ Agenesis (n=1) | | | | | | |
| a) Vaginal | 0 | - | - | - | - | - |
| b) Cervical | 0 | - | - | - | - | - |
| c) Fundal | 0 | - | - | - | - | - |
| d) Tubal | 1 | 38.3 | Cesarean Delivery | Nil | 2.4 | 8, 9 |
| e) Combined | 0 | - | - | - | - | - |
| Unicornuate (n=2) | | | | | | |
| a) Communicating Rudimentary horn | 0 | - | - | - | - | - |
| b) Non Communicating horn | 1 | 37.6 | Cesarean Delivery | Nil | 2.1 | 8, 9 |
| c) No Cavity | 0 | - | - | - | - | - |
| d) No horn | 1 | 37.0 | Cesarean Delivery | IUGR, Oligohydramnios | 1.9 | 6,9 |
| Didelphus (n=0) | 0 | - | - | - | - | - |
| Bicornuate (n=1) | | | | | | |
| a) Complete | 1 | 37.1 | Vaginal delivery | Cervical Stitch | 2.3 | 8,9 |
| b) Partial | 0 | - | - | - | - | - |
| Septate (n=2) | | | | | | |
| a) Complete | 1 | 38.6 | Vaginal delivery | Retained Placenta | 2.7 | 7,9 |
| b) Partial | 1 | 38.2 | Cesarean Delivery | Cephalo Pelvic Disproportion | 2.9 | 8,9 |
| *Arcuate (n=5) | 5 | 38.23 | Cesarean Delivery | Breech | 2.6 | 8.50,9 |
| DES related (n=0) | 0 | - | - | - | - | - |

*Mean of values obtained for all 5 cases with Arcuate uterus for birth weight, gestational age, APGAR Score have been mentioned.

The prevalence of incidental finding of Mullerian anomalies at successful term pregnancies was 0.21%.

All of these cases completed their intrapartum and post partum period uneventfully and all mothers and babies were discharged from hospital well. Most patients are on regular follow up at our institute presently.

DISCUSSION

The true incidence of mullerian anomalies in the general population is not well known, although studies show varied incidences in different clinical backgrounds. Some studies quote their overall prevalence to be 1-10% [5] and others state 0.4% [6].

Mullerian anomalies are associated with adverse pregnancy outcomes due to small size of the cavity, poor endometrial- decidual development, and abnormal smooth muscle function of uterine myometrium. These anatomical and functional disturbance combined with

inadequate vascularity disturb the pregnancy complicating it in many aspects, mostly ending them early and adversely [7-11]. Thus, successful and uneventful pregnancies are few.

The prevalence of mullerian anomalies at term pregnancies is 0.28% in the present study and the incidence of their incidental finding in term pregnancies is 0.21%.

One case of agenesis of unilateral fallopian tube was noted during a cesarean delivery, which was done for arrest of descent.

Two cases of Unicornuate uterus were seen which were referred to our institute from other centers. Both were identified incidentally during cesarean delivery. The first patient had Unicornuate uterus with no horn (Figure 2) and was operated for moderate IUGR with oligohydramnios. Of a special mention is an intraoperative finding of a very thin and stretched out uterine wall due to which she suffered a posterior

extension of the uterine incision on the left side (Figure 3). A postoperative ultrasound abdomen also revealed absent left kidney. The other patient had a unicornuate uterus with a non-communicating rudimentary horn (Figure 4), which was noted during cesarean delivery which was performed for fetal distress.

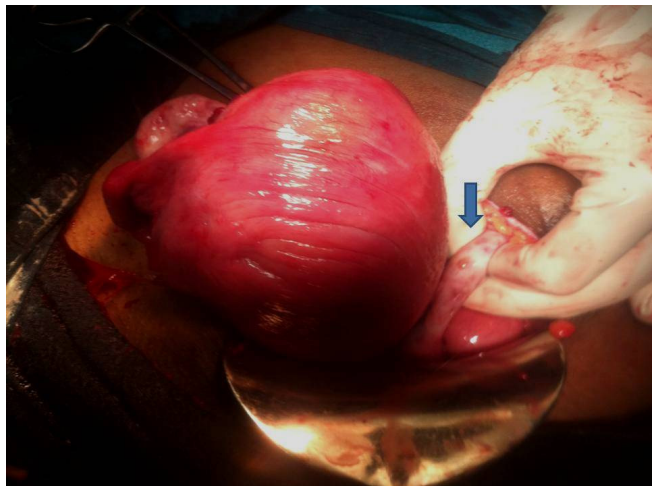

Figure 2: Intra operative image of Unicornuate uterus with no horn after delivery of the baby in cesarean section. Arrow pointing at left ovary attached to lateral pelvic wall and absence of left fallopian tube.

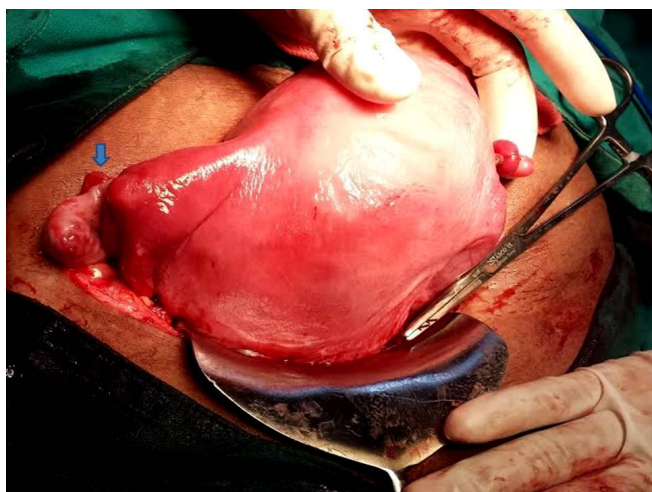


Figure 4: Intra operative image of Unicornuate uterus with non communicating rudimentary horn after delivery of the baby in cesarean section. Arrow pointing at right fallopian tube attachment to rudimentary horn.

One case of complete bicornuate uterus was identified after a vaginal delivery, which was referred from a rural centre for further management of oligohydramnios at 36 weeks gestation. Patient also had a cervical stitch insitu which was removed and labor was induced at term. A suspicion of uterine anomaly arose during delivery and a postpartum ultrasound at our centre revealed a bicornuate uterus.

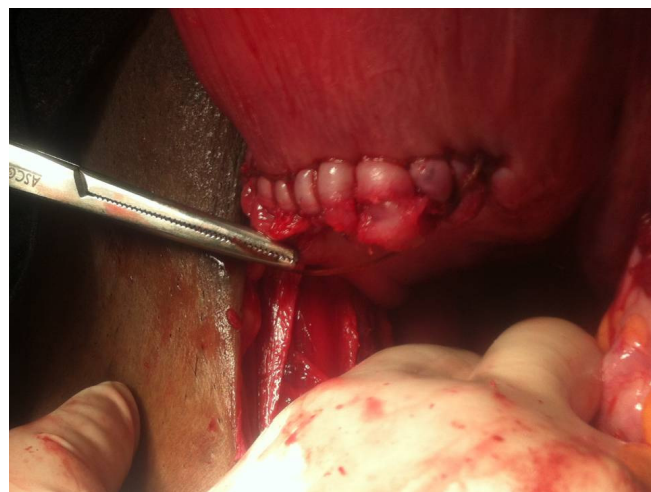

Figure 3: Intra operative image showing posterior extension of uterine incision in cesarean section of patient with Unicornuate uterus with no horn.

Two cases of septate uterus were seen, one during a vaginal delivery and one during a cesarean section. The former had a retained placenta for which manual removal of placenta was performed during which a complete septum was noted in the uterine cavity. The latter was a subseptate uterus which was noted during a term cesarean section which was done for cephalo pelvic disproportion.

5 cases of arcuate uterus were noted in term cesarean deliveries, two of which were operated for breech presentation.

Our results showed maximum cases of arcuate uterus reached term gestation uneventfully and no cases of uterus didelphus ended in successful term pregnancy.

The limitation of the present study is a probability of missing out on cases with asymptomatic mullerian anomalies involving the upper genital tract during full term normal vaginal deliveries. Patients who underwent cesarean deliveries had the obvious advantage of direct visualization of the entire upper genital tract thoroughly to note even minor anatomical variations.

CONCLUSION

Mullerian Anomalies are known to cause adverse pregnancy outcomes and gynecological disturbances. But some of them remain silent during entire early reproductive period and pregnancy, giving a positive pregnancy outcome and finally getting their diagnosis established incidentally. These incidences are crucial for counseling of patients and their families.

Also, we must be on a look out for these diagnoses not only to identify co existing urological disturbances but also to help us improve their subsequent obstetric performances.

ACKNOWLEDGEMENTS

Nil

CONFLICTS OF INTEREST

Nil

REFERENCES

- [1] Bega G, Lev- Toaff AS, Okanae P, Becker E Jr, Kurtz AB. Threedimensional ultrasonography in gynecology. Technical aspects and clinical applications. *J Ultrasound Med* 2003; 22: 1249-69
- [2] Green LK, Harris RE. Uterine anomalies; frequency of diagnosis and associated obstetric complications. *Obstet Gynecol* 1976; 47(4): 427-9
- [3] The American Fertility Society Classification of adnexal adhesions, distal tubal occlusion, tubal occlusion secondary to tubal ligation, tubal pregnancies, Mullerian anomalies and intrauterine adhesions. *Fertil Steril* 1988; 49: 944-55
- [4] Buttram VC Jr, Gibbons WE. Mullerian anomalies: A proposed classification (an analysis of 144 cases). *Fertil Steril* 1979; 32: 40-48.
- [5] Ashton D, Amin HK, Richart RM, Neuwirth RS. The Incidence of Asymptomatic Uterine Anomalies in Women Undergoing Transcervical Tubal Sterilization. *Obstet Gynecol* 1988 Jul; 72(1): 28-30.
- [6] Azen Salim *et al.* Pregnancy and Uterine Anomalies: Donald School of Ultrasound in Obstetrics and Gynecology, July-September 2011; 5930: 187-191
- [7] Rackow BW, Arici A Reproductive performance of women with mullerian anomalies. *Curr Opin Obstet Gynecol*. 2007 Jun; 19(3): 229-37.
- [8] Propst Am, Hill JA 3rd. Anatomic factors associated with recurrent pregnancy loss. *Semin Reprod Med* 200; 18: 341-350.
- [9] Raga F, Bauset C, Remohi J *et al.* Reproductive impact of congenital mullerian anomalies. *Hum Reprod* 1997; 12: 2277-2281.
- [10] Leible S, Munoz H, Walton R, *et al.* Uterine artery blood flowvelocity waveforms in pregnant women with mullerian duct anomaly: a biological model for uteroplacental insufficiency. *Am J Obstet Gynecol* 1998; 178: 1048-1053
- [11] Rock JA, Sclaff WD. The Obstetric consequences of uterovaginal anomalies. *Fert Steril* 1985; 43: 681-692

Received on 05-02-2015

Accepted on 02-03-2015

Published on March-2015

<http://dx.doi.org/10.15379/2408-9761.2015.02.01.1>

© 2015 Rai *et al.*; Licensee Cosmos Scholars Publishing House.

This is an open access article licensed under the terms of the Creative Commons Attribution Non-Commercial License

(<http://creativecommons.org/licenses/by-nc/3.0/>), which permits unrestricted, non-commercial use, distribution and reproduction in any medium, provided the work is properly cited.