

CLINICAL IMAGES

Meningioma presenting as an oropharyngeal mass – an unusual presentation

G Dekker, H B Louw, M Pienaar, K Naidu, S T Hlongwane, S Andronikou

A 53-year-old woman presented with a 5-year history of a sore throat, followed by dysphonia ('hot potato voice'), dysphagia, slurred speech and finally partial compromise of the airway due to a large oropharyngeal mass. Cranial nerves VIII, IX, X and XII were affected on the left side. Trans-oral biopsy of this mass revealed a meningioma. Computed tomography (CT) and magnetic resonance imaging (MRI) showed a characteristic lobulated meningioma at the apex of the left petrous temporal bone and adjacent skull base. It expanded into the sella turcica, eroded through the skull base into the left carotid space and extended down to the bifurcation of the left common carotid artery. A coronal T1-weighted post-gadolinium MRI (Fig. 1a) shows both the intracranial portion and the extracranial parapharyngeal spread of the tumour. An axial T1-weighted post-gadolinium MRI (Fig. 1b) shows the brightly and homogeneously enhancing meningioma in the left carotid space.

Extracranial extension of meningiomas is very rare and only a few cases have been reported.¹ In almost all of the reported cases, a large intracranial meningioma was simultaneously or previously reported.¹ Extracranial extension is more commonly to the orbits, external table of the calvarium, temporal bone and paranasal sinuses.² Less frequently it spreads to the parapharyngeal space via the base of the skull,³ as in this case.

1. Uchibori M, Odake G, Ueda S, *et al.* Parapharyngeal meningioma extending from the intracranial space. *Neuroradiology* 1990; 32(1): 53-55.
2. Thompson LD, Gyure KA. Extracranial sino nasal tract meningiomas: a clinicopathologic study of 30 cases with a review of the literature. *Am J Surg Pathol* 2000; 24: 640-650.
3. Weinberger JM, Birt BD, Lewis AJ, *et al.* Primary meningioma of the nasopharynx: case report and review of ectopic meningioma. *J Otolaryngol* 1985; 14: 317-322.

Drs G Dekker, H B Louw, M Pienaar and S T Hlongwane and Professor S Andronikou are in the Department of Radiology, Tygerberg Academic Hospital and Stellenbosch University. Dr K Naidu is currently in private practice. Most of the registrars and consultants in the Department are members of active research groups under the guidance of Professor Andronikou.

Corresponding author: G Dekker (geritdekker@mweb.co.za)

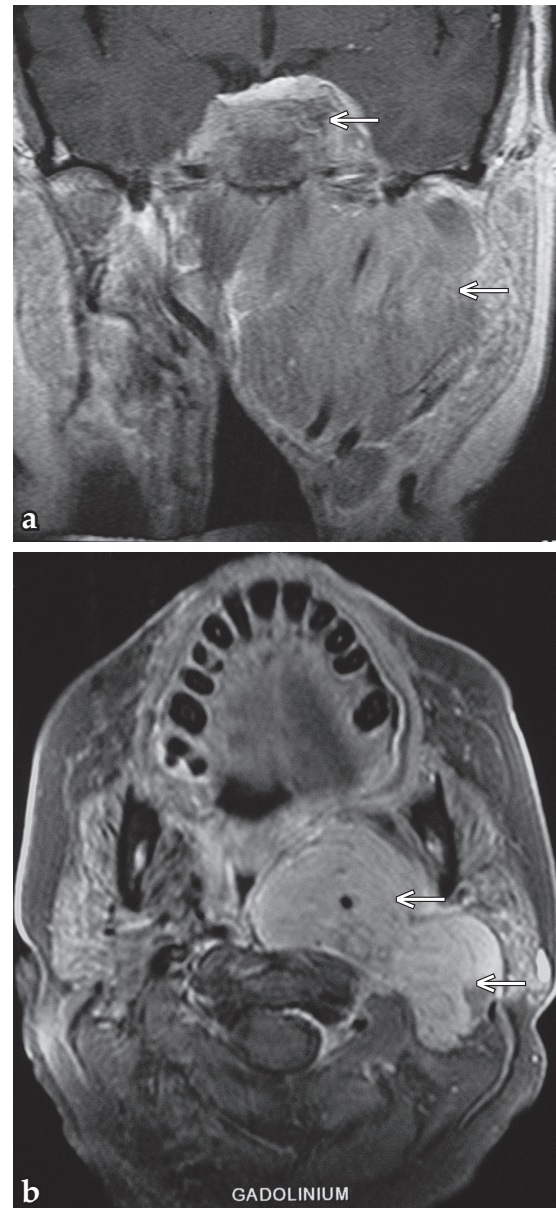


Fig. 1a and b. Coronal and axial post-gadolinium sequences: 53-year-old woman with a meningioma with parapharyngeal extension. The homogeneously enhancing mass has a bilobar appearance on the axial MRI and is seen involving the left nasopharynx on coronal MRI (arrows) (Fig. 1a). The mass projects into the nasopharynx anteriorly and extends posteriorly to occupy the left parapharyngeal space (arrows) (Fig. 1b).