

6-1-2018

Successful embolization of a enterocutaneous fistula tract with Onyx 34 following low anterior resection for rectal cancer.

Hamza Rahimi
George Washington University

Anthony C Venbrux
George Washington University

Vincent Obias
George Washington University

Follow this and additional works at: https://hsrc.himmelfarb.gwu.edu/smhs_rad_facpubs

 Part of the [Radiology Commons](#)

APA Citation

Rahimi, H., Venbrux, A., & Obias, V. (2018). Successful embolization of a enterocutaneous fistula tract with Onyx 34 following low anterior resection for rectal cancer. *Radiology Case Reports*, 13 (3). <http://dx.doi.org/10.1016/j.radcr.2017.09.007>

This Journal Article is brought to you for free and open access by the Radiology at Health Sciences Research Commons. It has been accepted for inclusion in Radiology Faculty Publications by an authorized administrator of Health Sciences Research Commons. For more information, please contact hsrc@gwu.edu.

Available online at www.sciencedirect.com
ScienceDirect
journal homepage: <http://Elsevier.com/locate/radcr>

Interventional Radiology

Successful embolization of a enterocutaneous fistula tract with Onyx 34 following low anterior resection for rectal cancer

Hamza Rahimi BA^{a,*}, Anthony C. Venbrux MD^b, Vincent Obias MD^c

^a Department of Radiology, The George Washington University School of Medicine and Health Sciences, Washington, DC

^b Department of Radiology, The George Washington University School of Medicine, Washington, DC

^c Department of Colorectal Surgery, The George Washington University School of Medicine, Washington, DC

ARTICLE INFO

Article history:

Received 22 March 2017

Received in revised form 8

September 2017

Accepted 8 September 2017

Available online

Keywords:

Rectal cancer

Embolization

Onyx

ABSTRACT

Enterocutaneous fistulas (ECFs) can be one of the complications found after surgical intervention for rectal cancer. Interventional modalities consisting of surgical, endoscopic, and radiological methods are often implemented to treat postoperative symptomatic complications. We present the case of 61-year-old Caucasian man who presented to us with a recent diagnosis of rectal cancer that had invaded the levators as well as anteriorly into the prostate, and who underwent low anterior resection with a diverting loop ileostomy. The patient was found to have a persistent presacral abscess due to an ECF tract. This case highlights the off-label use of ethylene-vinyl alcohol copolymer dissolved in dimethyl sulfoxide (Onyx 34) to seal an ECF.

© 2018 the Authors. Published by Elsevier Inc. under copyright license from the University of Washington. This is an open access article under the CC BY-NC-ND license (<http://creativecommons.org/licenses/by-nc-nd/4.0/>).

Case report

A 61-year-old Caucasian man presented with a recent diagnosis of rectal cancer that had invaded the levators as well as anteriorly into the prostate. Following neoadjuvant chemoradiation, the patient underwent robotic low anterior resection (LAR) with a diverting loop ileostomy on March 2015. Fourteen days following surgery, a computed tomography (CT) scan demonstrated that the patient had a presacral abscess. To drain the abscess, interventional radiology (IR) percutaneously placed an 8.5-French all-purpose drainage catheter

(Cook Inc, Bloomington, IN) from a right posterior transgluteal approach. The patient underwent an additional 8 weeks of chemotherapy and the abscess drainage catheter remained in place during this time. The drainage catheter was removed after output decreased to a minimal amount (ie, less than 10 cc/24 h for several days) and a follow-up CT scan that showed a resolution of the presacral abscess. However, the scan, performed with intravenous (IV) and rectal contrast, documented the presence of a rectal leak. The patient later underwent small bowel resection and anastomosis on Oct 30, 2015. Following the surgical procedure, the patient started having a foul-smelling diarrhea. The patient denied fevers, abdominal pain,

Competing Interests: The authors have declared that no competing interests exist.

* Corresponding author.

E-mail address: hrahimi@gwu.edu (H. Rahimi).

<https://doi.org/10.1016/j.radcr.2017.09.007>

1930-0433/© 2018 the Authors. Published by Elsevier Inc. under copyright license from the University of Washington. This is an open access article under the CC BY-NC-ND license (<http://creativecommons.org/licenses/by-nc-nd/4.0/>).

or rectal bleeding. Stool cultures were negative for both *Clostridium difficile* and *Escherichia coli*. The patient's vital signs remained stable. The patient experienced fevers and fatigue and was readmitted to the hospital in November 20, 2015, to receive IV fluids and antibiotics and to rule out recurrent infections or pelvic fluid collections.

During the hospital admission, the patient received IV fluids and antibiotics. A CT scan demonstrated a recurrent rim-enhancing 7.0 × 4.8 cm fluid collection within the presacral space extending along the levator ani muscles. IR replaced the 8.5-French drainage catheter (Cook Inc) through the right transgluteal tract to drain the purulent fluid in the presacral space. Two weeks later, a follow-up CT scan of the abdomen and pelvis showed that the size of the fluid collection had decreased. An injection of contrast through the tube documented a connection between the presacral abscess and the rectum consistent with a leak and a fistula. Five months later, the drain in the right transgluteal tract was removed. Two months later, the patient presented to the IR service after a CT scan of the abdomen and pelvis again demonstrated a rim-enhancing 5.4 × 2.0 cm perirectal abscess within the presacral space and extending along the levator ani muscles. From a left transgluteal approach, IR placed a 10.2-French Cook Dawson-Mueller drainage catheter (Cook Inc) within the presacral abscess collection. A sinogram showed a fistula in the upper rectum and the distal sigmoid that arose from the posterior-lateral wall. The patient was sent home on a 2-week course of ciprofloxacin and flagyl. Following the 2-week course, the patient returned to the clinic due to the drain not working properly (ie, occluded due to debris in the drainage catheter lumen). The patient's left transgluteal drainage catheter was upsized and the patient was started on oral augmentin. The patient returned to the clinic 14 days later due to continued drainage from the left drain as well as new drainage from the previously closed and healed right transgluteal tube tract. A dark brown material was noted from the skin drainage site. The patient also reported rectal incontinence. IR was consulted to assist with management of this patient. IR initially tried closing the old right tube tract with Gelfoam, which failed within days of the tube tract injection.

The patient returned to IR 7 days later. A Reliant balloon (Medtronic Reliant, Santa Rosa, CA) (soft and deformable and normally used for aortic stent grafts) was advanced over a Bentson guidewire (Cook Inc) through the rectum up to the level of the leak approximately 8 cm into the rectum. This was gently inflated with approximately 15 cc of dilute contrast. This large balloon was used to prevent Onyx 34 from spilling into the rectum. Through the previous patent transgluteal tube tract (now an enterocutaneous fistula [ECF]), a hydrophilic coated angled catheter was advanced over a hydrophilic guidewire and was used to negotiate and outline the presacral abscess space. Having outlined the anatomy and the precise location of the leak, the catheter was slowly withdrawn as 2.4 cc of Onyx 34 was injected into the right transgluteal tract. Through the left fistula tract, a Kumpe catheter (Cook Inc) was advanced over a Benton guidewire and Onyx 34 was injected, filling the rectal leak site, the abscess cavity, and the tube tract. Dimethyl sulfide was used to purge the catheters before injecting Onyx 34. Once Onyx 34 was injected, the rectal balloon was deflated and removed.

Post-treatment

Six hours following the use of Onyx 34 polymer for embolization of the fistula tracts, the patient reported no drainage from the previous transgluteal tracts. Follow-up CT scan 3 weeks later showed a closed left fistula tract but a mild recurrent drainage from the right transgluteal tract. The patient underwent 2 additional Onyx 34 embolizations of the rectal leak site and a closure of the persistently leaking right transgluteal tract.

At 1 point in the follow-up interval, the patient had a brief episode of right transgluteal tract drainage. This was treated with a course of oral augmentin therapy. While on antibiotic therapy, the tract sealed and rectal discomfort ceased. The patient is currently asymptomatic at 18 weeks after the last onyx treatment.

Discussion

ECFs are abnormal sinus tract formations between the alimentary system and the skin surface that can result from inflammatory bowel disease, abdominal surgery, abscesses, or iatrogenic causes [1]. The approach to management is focused on sepsis control, nutritional status, anatomic mapping, and treatment [1]. The morbidity and mortality rates from ECFs have been reported to be around 6%-33% [2]. Medical management is the initial route that is usually undertaken. Nonoperative closure rates for ECF tracts are around 5%-20% [3]. Even with low closure rates, medical management acts as a useful adjunct that allows control of the underlying inflammation, infection, and nutritional imbalances before an operative approach is undertaken [1]. Surgical closure rates, which involve resection and anastomoses, are anywhere between 75% and 85% [3]. Even with higher closure rates, complications from surgery, such as a recurrence of the fistula tract, can be debilitating for many patients. In a large series, the recurrence rate of ECF following operative repair was found to be around 20.5% [4]. Higher recurrence rates were associated specifically with the surgical oversewing method (36%) vs the resection (16%) of the ECF [4]. Because recurrences are associated with ECF surgery, alternative and interventional radiological methods in the community are undertaken in an attempt to adequately manage ECF without resorting to the operative route.

There have been reports of minimally invasive methods that have attempted to manage fistula closures. The use of collagen plugs is an alternative method that has been used for the closure of ECFs. A study by Lyon et al. [5] demonstrated closure in all fistulas within 2 weeks. The study reported on 6 patients who underwent treatment for an ECF with a Biodesign ECF plug, which is an extracellular matrix made of collagen and other materials that aid in tissue repair and closure of the fistula tract. Only 2 patients (33%) had a recurrence of a fistula 9 and 12 months, respectively [5]. The Biodesign ECF plug comes in 4- and 7-mm sizes and is delivered through 18- and 22-French sheaths, and is unlikely to work on tracts less than 3 cm [5]. Other noninvasive methods that have been used to manage fistula tracts are platelet-rich fibrin glue (PRFG) and vacuum-assisted wound closure.

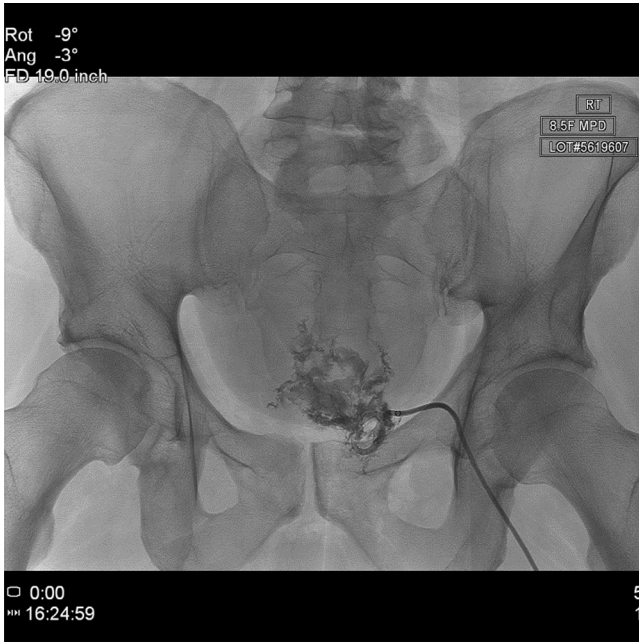


Fig. 1 – Anteroposterior (A/P) digital spot image after the right transgluteal abscess drainage catheter was placed.

PRFG, a fibrin gel containing high concentrations of human fibrinogen and thrombin, has been used to seal low-output ECF [6]. The study by Wu et al. examined the use of PRFG in low-output ECF, which showed a lesser median time for fistula closure (7 days) than those who just received supportive care [6]. Although fibrin glue has been previously used for low-output

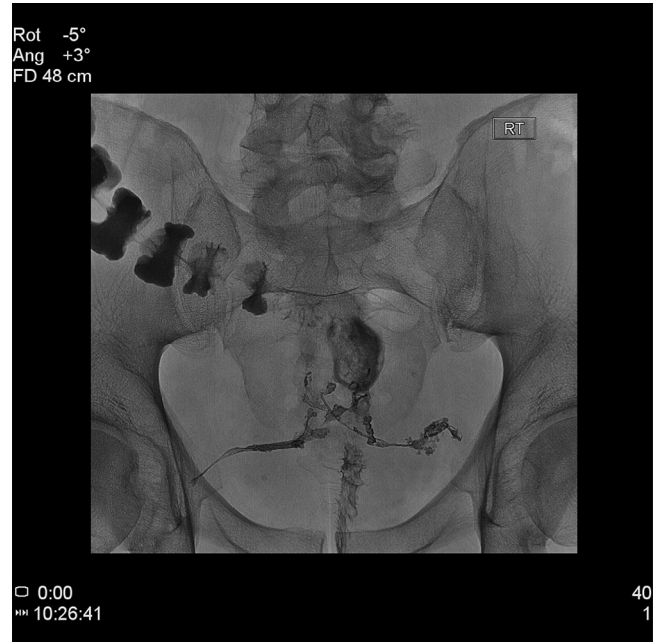

Fig. 3 – A/P digital spot image after transgluteal tract occlusion with onyx. Note the water-soluble contrast outlining the rectum and the remaining colon.

fistula tract closures, PRFG's lack of transmission of infections, high cost, and allergic reactions make it more versatile than other fibrin sealants used to seal fistula tracts [6]. Percutaneous embolization of low-output ECF tract with n-butyl-2-cyanoacrylate glue and Lipiodol [7]. In the small study performed

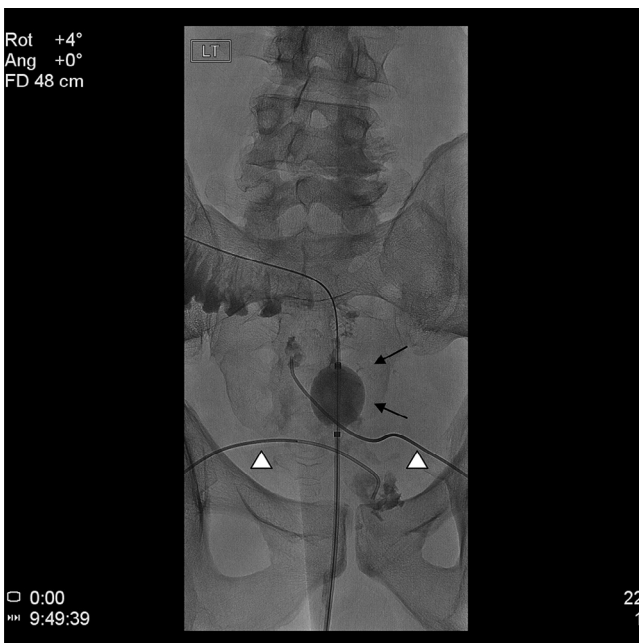


Fig. 2 – A/P digital spot image during transgluteal tract embolization. Note that the large rectal occlusion balloon has been inflated over the site of leakage. (←). Note the 2 different 5-French catheters (△) advanced through the transgluteal tracts.

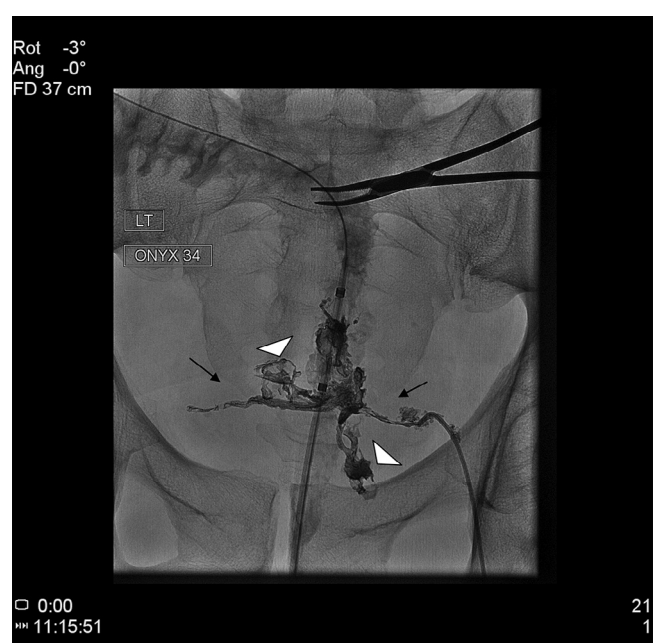


Fig. 4 – A/P distal spot image obtained during retreatment. Note the dense onyx in both transgluteal tracts (←) and perirectal abscess leak sites (△). Also, note onyx filling the anastomotic leak sites. Water-soluble contrast fills the rectum and the colon.

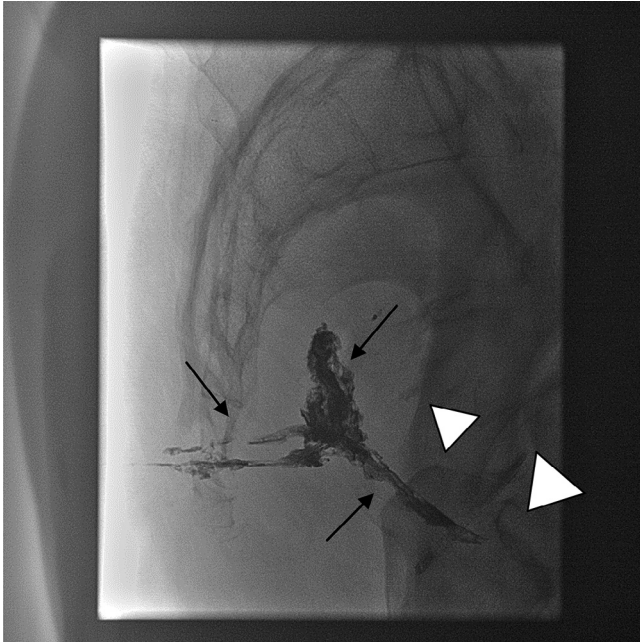


Fig. 5 – Completion digital spot image in lateral projection after final onyx treatment session. Onyx fills each transgluteal tube tract and the anastomotic leak sites (→). Note the faint pacification of the rectum with water-soluble contrast (△).

by Cambj Sapunar et al., 6 patients with 7 ECFs underwent embolization with butyl-2-cyanoacrylate glue and Lipiodol, and complete closure of all 7 fistulas was obtained [7]. During a follow-up period ranging from 1 to 18 months, 5 patients did not have a reoccurrence of ECF [7]. Only 1 patient required colostomy due to a reoccurrence of rectal cancer 2 months after embolization [7].

In our patient who had postsurgical complications following LAR, Onyx 34 was used to fill and close a residual presacral

abscess cavity and to close bilateral transgluteal tube tracts. To our knowledge, there have been no previous reported cases of using ethylene-vinyl alcohol polymer to seal a leak and a fistula tract causing persistent presacral abscess. Using Onyx may be an effective method in closing fistula tracts that develop following LAR in patients who fail conservative management and may defer surgical repair. However, further studies and long-term follow-up will be needed to determine efficacy (Figs. 1–5).

REFERENCES

- [1] Rahman FN, Stavas JM. Interventional radiologic management and treatment of enterocutaneous fistulae. *J Vasc Interv Radiol* 2015;26(1):7–19. doi:10.1016/j.jvir.2014.09.009.
- [2] Williams LJ, Zolfaghari S, Boushey RP. Complications of enterocutaneous fistulas and their management. *Clin Colon Rectal Surg* 2010;23(3):209–20. <http://doi.org/10.1055/s-0030-1263062>.
- [3] Owen RM, Love TP, Perez SD, Srinivasan JK, Sharma J, Pollock JD, et al. Definitive surgical treatment of enterocutaneous fistula: outcomes of a 23-year experience. *JAMA Surg* 2013;148(2):118–26.
- [4] Lynch A, Delaney C, Senagore A, Connor J, Remzi F, Fazio V. Clinical outcome and factors predictive of recurrence after enterocutaneous fistula surgery. *Ann Surg* (2004);240(5):825–31. doi:10.1097/01.sla.0000143895.17811.e3.
- [5] Lyon J, Hodde J, Hucks D, Changkuon D. First experience with the use of a collagen fistula plug to treat enterocutaneous fistulas. *J Vasc Interv Radiol* (2013);24(10):1559–65.
- [6] Ren J, Wu X, Ren J, Gu G, Wang G, Tou B, et al. Autologous platelet rich fibrin glue for sealing of low-output enterocutaneous fistulas: an observational cohort study. *Surgery* 2014;155(3):434–41.
- [7] Cambj Sapunar L, Sekovski B, Matić D, Tripković A, Grandić L, Družijanić N. Percutaneous embolization of persistent low-output enterocutaneous fistulas. *Eur Radiol* 2012;22(9):1991–7. doi:10.1007/s00330-012-2461-y.