

Himmelfarb Health Sciences Library, The George Washington University Health Sciences Research Commons

Radiology Faculty Publications

Radiology

6-2018

Ultrasound-guided introital drainage of pyometrocolpos

I Kim

Ranjith Vellody

George Washington University

Hans G. Pohl

George Washington University

Karun Sharma

George Washington University

Kabir Yadav

George Washington University

Follow this and additional works at: https://hsrc.himmelfarb.gwu.edu/smhs_rad_facpubs

 Part of the [Radiology Commons](#), and the [Surgery Commons](#)

APA Citation

Kim, I., Vellody, R., Pohl, H. G., Sharma, K., & Yadav, K. (2018). Ultrasound-guided introital drainage of pyometrocolpos. *Journal of Pediatric Surgery Case Reports*, 33 (). <http://dx.doi.org/10.1016/j.epsc.2017.10.006>

This Journal Article is brought to you for free and open access by the Radiology at Health Sciences Research Commons. It has been accepted for inclusion in Radiology Faculty Publications by an authorized administrator of Health Sciences Research Commons. For more information, please contact hsrc@gwu.edu.



Ultrasound-guided introital drainage of pyometocolpos

Il Kyoon Kim^a, Ranjith Vellody^b, Hans G. Pohl^c, Karun Sharma^b, Bhupender Yadav^{b,*}

^a University of Maryland Medical Center, Midtown Campus, Baltimore, MD, USA

^b Department of Radiology, Children's National Medical Center, Washington, DC, USA

^c Department of Urology, Children's National Medical Center, Washington, DC, USA



ARTICLE INFO

Keywords:

Pyometocolpos
Interventional radiology
Ultrasound guided
Introital drainage

ABSTRACT

Pyometocolpos can be caused by congenital malformations such as distal vaginal atresia and imperforate hymen. Patients usually present with obstructive urinary tract infections, acute kidney injury, or sepsis. Percutaneous drainage of the infected fluid can help treat the patient; however, recurrence is of concern. In this case report, we present a case of a child with recurrent pyometocolpos due to distal vaginal atresia despite initial percutaneous drainage. To our knowledge, this is the first report of ultrasound-guided introital drainage of pyometocolpos with relief of symptoms obviating the need for repeat drainage or immediate surgery.

1. Introduction

Pyometocolpos is defined as an infection of fluid within the vagina and uterus. It can occur as a result of an accumulation of cervicovaginal secretions due to congenital malformations including distal genital tract obstruction, imperforate hymen, or genitourinary sinus [1,2]. Patients may present in infancy, adolescence, or even as adults. The true incidence of these anomalies is unknown but is reported to be between 0.1 and 3.8% [3]. Usual presentations include, acute renal failure, urinary tract infection (UTI), and sepsis, and immediate drainage of the infected cystic mass is required to treat uropathy and septicemia until definitive corrective surgery can be performed [4–6]. For emergent treatment, minimally invasive ultrasound (US)-guided percutaneous drainage from an anterior abdominal wall approach has been used with successful outcomes [4,5,7]. The current case report describes the use of image-guided aspiration with drainage catheter placement of the infected vaginal fluid through the introitus in a child with recurrent pyometocolpos who presented with urosepsis. This patient had previously undergone subcutaneous drainage through a lower anterior abdominal approach at eleven months of age with corrective surgery deferred for later. Introital approach would allow for drainage of vaginal secretions via a natural route provided that the drainage catheter is kept in place for sufficient time that an epithelialized tract would form.

1.1. Case report

A 14-month-old healthy, ex-full term female initially presented with a three day history of high fever up to 40 °C, febrile seizure, vomiting,

and diarrhea. Abdominal exam was benign except for mild distention. The perineal examination revealed normal patent anus, urethral opening, labia with normal contour, normal perineal body, but no definitive hymen or identifiable vaginal opening. Laboratory findings were as follows: white blood cell count (WBC) 14,910/ μ L, Hb 9.2 g/dL. Urinalysis was as follows: nitrite positive, leukocyte esterase 3+, WBC 92/hpf, bacteria > 100,000 cfu/mL (Klebsiella oxytoca). Patient was placed on Bacterium 40mg/200mg/5 mL.

Ultrasound of the abdominopelvic region demonstrated a 9.6 × 6.2 × 5.7 cm pelvic cystic mass located to the right of midline below the uterine fundus. With heterogeneous moving internal echoes within the cyst in conjunction with the laboratory findings, the differential diagnosis was pyometocolpos or hematometocolpos. The urinary bladder was partially distended and displaced to the left of midline over the cystic mass. The ultrasound study also revealed right hydroureteronephrosis. Based on these findings, cystoscopy was performed under general anesthesia which revealed a bladder filled with foul smelling cloudy fluid lateralized by the cystic mass. The culture resulted in no growth. Upon fluid drainage, cystoscopy revealed normal appearing bladder mucosa without fistulae. Inspection of her vagina and rectum revealed a vaginal atresia with a normal urethral opening and normal anal opening. On rectal exam, the vaginal atresia was over 2 cm in length before the bulge in the vagina could be palpated. A laparoscopy was also performed to explore adjacent pelvic organs. It revealed a normal appearing uterus, and bilateral ovaries with significantly enlarged fallopian tubes, and a large dilated vagina. A 14-gauge angiocath was then placed through the anterior abdominal wall into the dilated vagina and used to evacuate foul smelling purulent material. Upon irrigation and evacuation, the vagina appeared

* Corresponding author.

E-mail address: byadav@childrensnational.org (B. Yadav).

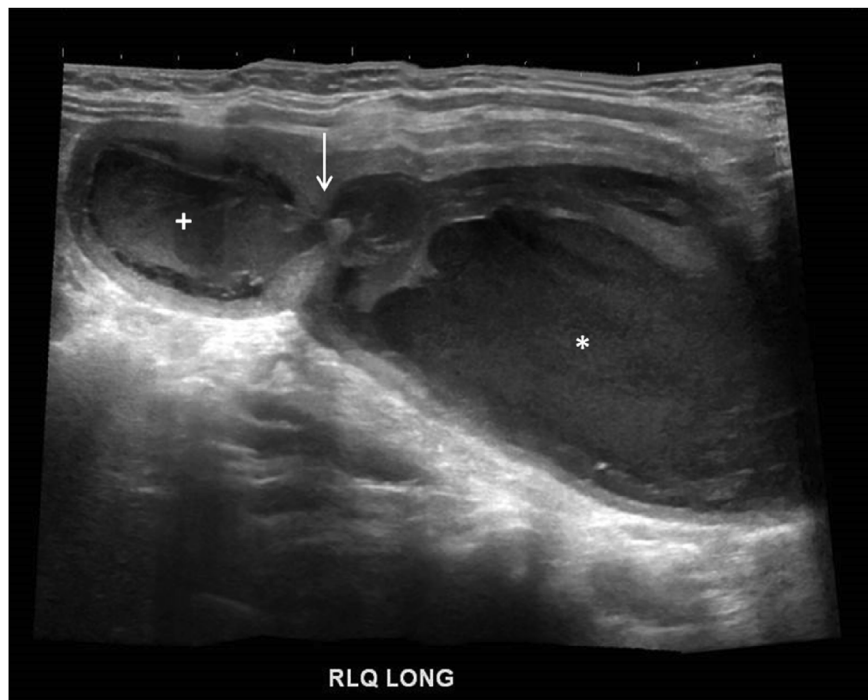


Fig. 1. Sagittal panoramic ultrasound image of right lower quadrant demonstrates a dilated vagina (white asterisk *) and uterus (white plus +) with thick echogenic material crossing the cervix (white arrow) which was confirmed as pus during drainage procedure.

decompressed laparoscopically. Vaginal fluid culture resulted in no growth.

The patient improved clinically and a one month post procedure follow-up ultrasound revealed significantly improved right hydronephrosis and decreased vaginal distention. At this time, it was elected to defer corrective vaginal surgery until just before she reaches puberty as early interventions commonly lead to vaginal stenosis and need for revision [8].

The patient was monitored for six months post-procedure, and her overall condition and laboratory parameters returned to baseline with the exception of a single episode of low-grade fever and culture positive urinary tract infection for which she was treated with Ciprofloxacin.

However, 25 months after the initial procedure (at three years of age), the patient was readmitted for three weeks of sporadic fevers, decreased energy and poor oral intake, urinary retention, and recurrent UTI. Abdominopelvic ultrasound revealed worsening hydronephrosis and a 9×5.7 cm midline pyometocolpos with echogenic debris within (Fig. 1). Patient was referred to the interventional radiology department for emergent image-guided drainage. Since the recurrence was despite prior percutaneous laparoscopic drainage, we planned to approach drainage from the introitus and use this access to form a mature epithelialized tract to prevent reaccumulation of secretions and any future recurrences.

Using standard sterile precautions, the vagina was accessed under ultrasound guidance with a 21-gauge needle via the introitus. Once pus was obtained, a guidewire was advanced through the needle under ultrasound guidance and the needle removed. After serial tract dilatation over the wire, a 10.2 French multipurpose pigtail drainage catheter (Cook Inc.) was placed. 10 ml of iodinated contrast was injected under fluoroscopy to confirm catheter position (Fig. 2). A total of 180 mL of pus was drained. Catheter was secured to inner thigh, and attached to a suction bag. Culture results were positive for *E. Coli*. The patient's post-procedure course was uneventful and she was discharged home after four days. The drain was removed three weeks later, after vaginostomy demonstrated an epithelialized tract around the drainage catheter. After six weeks, follow-up ultrasound demonstrated a complete resolution of pyometocolpos and right hydronephrosis. At one year

follow-up, the patient experienced recurrent UTI due to the voiding dysfunction which was treated with Ciprofloxacin; however, there was no reaccumulation of fluid within the vagina. The latest follow-up at five years of age (two and a half years post introital drainage), revealed that the patient was doing well without any repeat episodes of pyometocolpos and was taken off prophylactic antibiotics. She does not have any voiding dysfunction and has had no UTIs in the last year. No repeat vaginostomy has been performed to explore epithelialized tract as it was not clinically indicated.

2. Discussion

Distal vaginal atresia usually manifests as hydrometrocolpos in infancy and can also present as pyometocolpos due to infection of retained secretions. Pyometocolpos with septicemia is a surgical emergency and drainage is generally considered mandatory. Complex surgical drainage procedures are not recommended in the setting of infection as was in our case. Image guided percutaneous drainage of pyometocolpos through an anterior abdominal wall approach has been reported by several authors using various imaging modalities and shown to be a safe minimally invasive method [4,5,7].

Our patient underwent drainage from the introitus using ultrasound and fluoroscopic guidance with the plan to keep a relatively large sized pigtail drainage catheter in place for a few weeks to allow formation of an epithelialized tract that would allow vaginal secretions a natural drainage pathway. To our knowledge, this approach has not been described before. Using ultrasound guidance, traversing the distal atretic segment of vagina was possible as the distended upper vagina was pushing the urinary bladder and rectum away. Three weeks later, vaginostomy revealed an epithelialized tract and the catheter was removed. Epithelialized tract was explored with a cystoscope which showed normal appearing vagina and cervical os. Dilatation of the epithelialized tract then was not deemed necessary due to adequate drainage. Stool contamination was not an issue in our patient as the drainage catheter was secured to the inner thigh anteriorly so that the catheter coursed away from anal opening and our patient was toilet trained. At thirty-month follow-up, the patient has not had any reaccumulation of

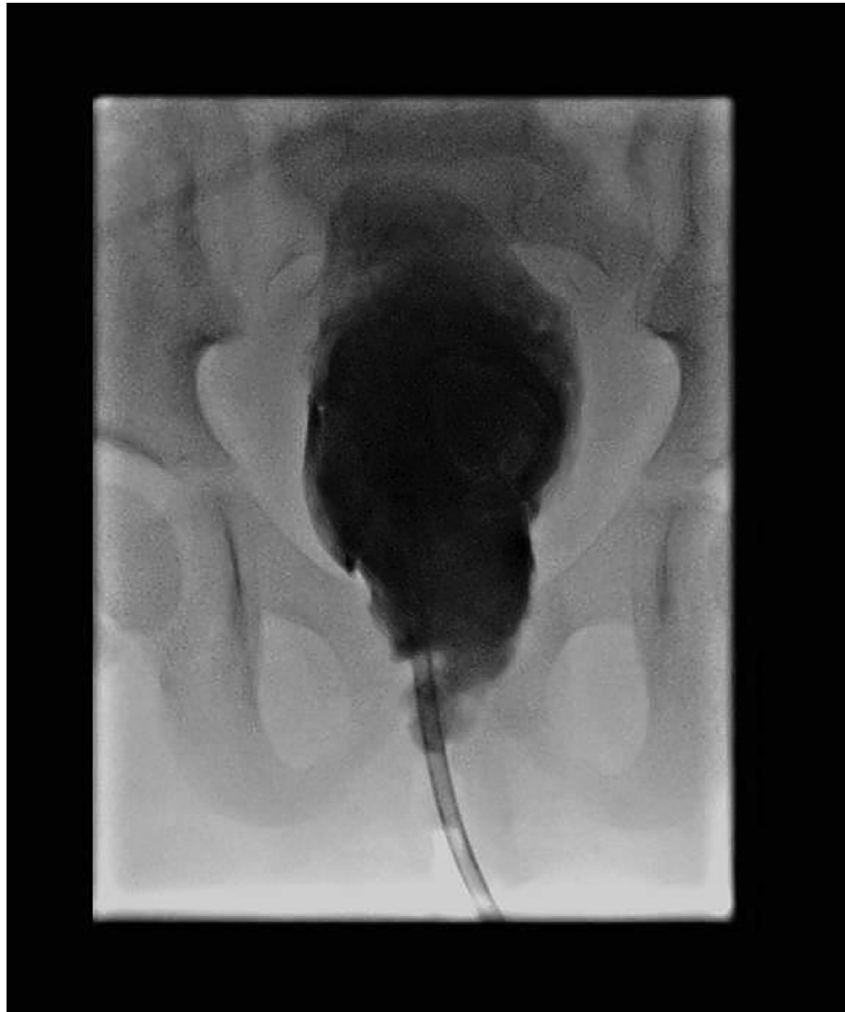

Fig. 2. Frontal fluoroscopic image of the pelvis demonstrating pigtail catheter within the vagina (opacified with contrast media). Note that the pigtail catheter is entering from below (from the introitus in this case).

fluid in the vagina as documented by multiple ultrasound studies. She may still require a formal reconstructive surgery later in life.

3. Conclusion

Percutaneous drainage is usually a temporary measure and does not prevent further accumulation of fluid. On the other hand, as seen from our patient, introital drainage and drain placement allowed formation of an epithelialized tract which provided immediate remediation and reaccumulation prevention. The epithelialized introital tract could also be utilized in the future for reconstruction in patients with distal vaginal atresia. For patients requiring deferred urogenital reconstructive surgery and immediate and semi-permanent epithelialized drainage passage of pyometocolpos, introital drainage approach should be considered.

Conflict of interest

The authors declare that they have no conflict of interest.

References

- [1] Liu YP, Chen CP. Fetal MRI of hydrometrocolpos with septate vagina and uterus didelphys as well as massive urinary ascites due to cloacal malformation. *Pediatr Radiol* 2009;39:877.
- [2] Sidatt M, Ould Sidi Mohamed Wedih A, Ould Boubaccar A, Ould Ely Litime A, Feil A, Ould Moussa A. Hydrocolpos and hydrometrocolpos in newborns. *Arch Pediatr* 2013;20:176–80.
- [3] Nazir Z, Rizvi RM, Qureshi RN, Khan ZS, Khan Z. Congenital vaginal obstructions: varied presentation and outcome. *Pediatr Surg Int* 2006;22:749–53.
- [4] Imamoğlu M, Cay A, Sarihan H, Koşucu P, Ozdemir O. Two cases of pyometocolpos due to distal vaginal atresia. *Pediatr Surg Int* 2005;21:217–9.
- [5] Algin O, Erdogan C, Kilic N. Ultrasound-guided percutaneous drainage of neonatal pyometocolpos under local anesthesia. *Cardiovasc Interv Radiol* 2011;34(Suppl 2):S271–6.
- [6] Lashley DB, Thomas RD, Silberberg PJ, Skoog SJ. Management of an infected hematometrocolpos in a patient with congenital adrenal hyperplasia and vaginal stenosis. *J Urol* 1998;160:508–9.
- [7] Dursun I, Gunduz Z, Kucukaydin M, Yildirim A, Yilmaz A, Poyrazoglu HM. Distal vaginal atresia resulting in obstructive uropathy accompanied by acute renal failure. *Clin Exp Nephrol* 2007;11:244–6.
- [8] Leslie JA, Cain MP, Rink RC. Feminizing genital reconstruction in congenital adrenal hyperplasia. *Indian J Urol* 2009;25:17–26.