

1-1-2016

# Ultrasound and Perforated Viscus; Dirty Fluid, Dirty Shadows, and Peritoneal Enhancement.

Hamid Shokoohi  
*George Washington University*

Keith S. Boniface  
*George Washington University*

Bruce M. Abell  
*George Washington University*

Ali Pourmand  
*George Washington University*

Mohammad Salimian  
*George Washington University*

Follow this and additional works at: [https://hsrc.himmelfarb.gwu.edu/smhs\\_emerg\\_facpubs](https://hsrc.himmelfarb.gwu.edu/smhs_emerg_facpubs)

 Part of the [Analytical, Diagnostic and Therapeutic Techniques and Equipment Commons](#), and the [Emergency Medicine Commons](#)

---

## APA Citation

Shokoohi, H., Boniface, K. S., Abell, B. M., Pourmand, A., & Salimian, M. (2016). Ultrasound and Perforated Viscus; Dirty Fluid, Dirty Shadows, and Peritoneal Enhancement. *Emergency (Tehran, Iran)*, 4 (2). Retrieved from [https://hsrc.himmelfarb.gwu.edu/smhs\\_emerg\\_facpubs/286](https://hsrc.himmelfarb.gwu.edu/smhs_emerg_facpubs/286)

This Journal Article is brought to you for free and open access by the Emergency Medicine at Health Sciences Research Commons. It has been accepted for inclusion in Emergency Medicine Faculty Publications by an authorized administrator of Health Sciences Research Commons. For more information, please contact [hsrc@gwu.edu](mailto:hsrc@gwu.edu).

## ORIGINAL RESEARCH

# Ultrasound and Perforated Viscus; Dirty Fluid, Dirty Shadows, and Peritoneal Enhancement

Hamid Shokoohi<sup>1\*</sup>, Keith S. Boniface<sup>1</sup>, Bruce M. Abell<sup>2</sup>, Ali Pourmand<sup>1</sup>, Mohammad Salimian<sup>1</sup>

1. Department of Emergency Medicine, George Washington University Medical Center, Washington DC, USA.

2. Department of Surgery, George Washington University Medical Center, Washington DC, USA.

Received: November 2015; Accepted: December 2015

**Abstract:** Early detection of free air in the peritoneal cavity is vital in diagnosis of life-threatening emergencies, and can play a significant role in expediting treatment. We present a series of cases in which bedside ultrasound (US) in the emergency department accurately identified evidence of free intra-peritoneal air and echogenic (dirty) free fluid consistent with a surgical final diagnosis of a perforated hollow viscus. In all patients with suspected perforated viscus, clinicians were able to accurately identify the signs of pneumoperitoneum including enhanced peritoneal stripe sign (EPSS), peritoneal stripe reverberations, and focal air collections associated with dirty shadowing or distal multiple reflections as ring down artifacts. In all cases, hollow viscus perforation was confirmed surgically. It seems that, performing US in patients with suspected perforated viscus can accurately identify presence of intra-peritoneal echogenic or "dirty" free fluid as well as evidence of free air, and may expedite patient management.

**Keywords:** Ultrasonography; Abdomen, Acute; Pneumoperitoneum; Emergency Department

© Copyright (2015) Shahid Beheshti University of Medical Sciences

**Cite this article as:** Shokoohi H, S. Boniface K, M. Abell B, Pourmand A, Salimian M. Ultrasound and Perforated Viscus; Dirty Fluid, Dirty Shadows, and Peritoneal Enhancement. *Emergency*. 2016; 4(2):101-105.

## 1. Introduction

Early detection of free air in the peritoneal cavity is vital in diagnosis of life-threatening emergencies, and can play a significant role in expediting treatment. Detection of free air is not currently considered a core bedside ultrasonography (US) application in emergency departments (ED) (1). Being familiar with the signs of intra-peritoneal free air and other evidence of a perforated hollow viscus would be particularly valuable to stratify patients with an undifferentiated acute abdomen. If US was able to detect free air in the peritoneum, it would expedite patient care, surgical consultation, and operative management. There have been several studies evaluating the efficacy of US in diagnosis of intra-peritoneal free air, in most of which US was performed by radiologists (2-5). However, there is little data regarding utility of US by emergency physicians (EP) in diagnosis of pneumoperitoneum (6-8). Here we present a case series of acute

perforated viscous that were sonographically diagnosed by EPs, illustrating free intra-peritoneal air and echogenic free fluid.

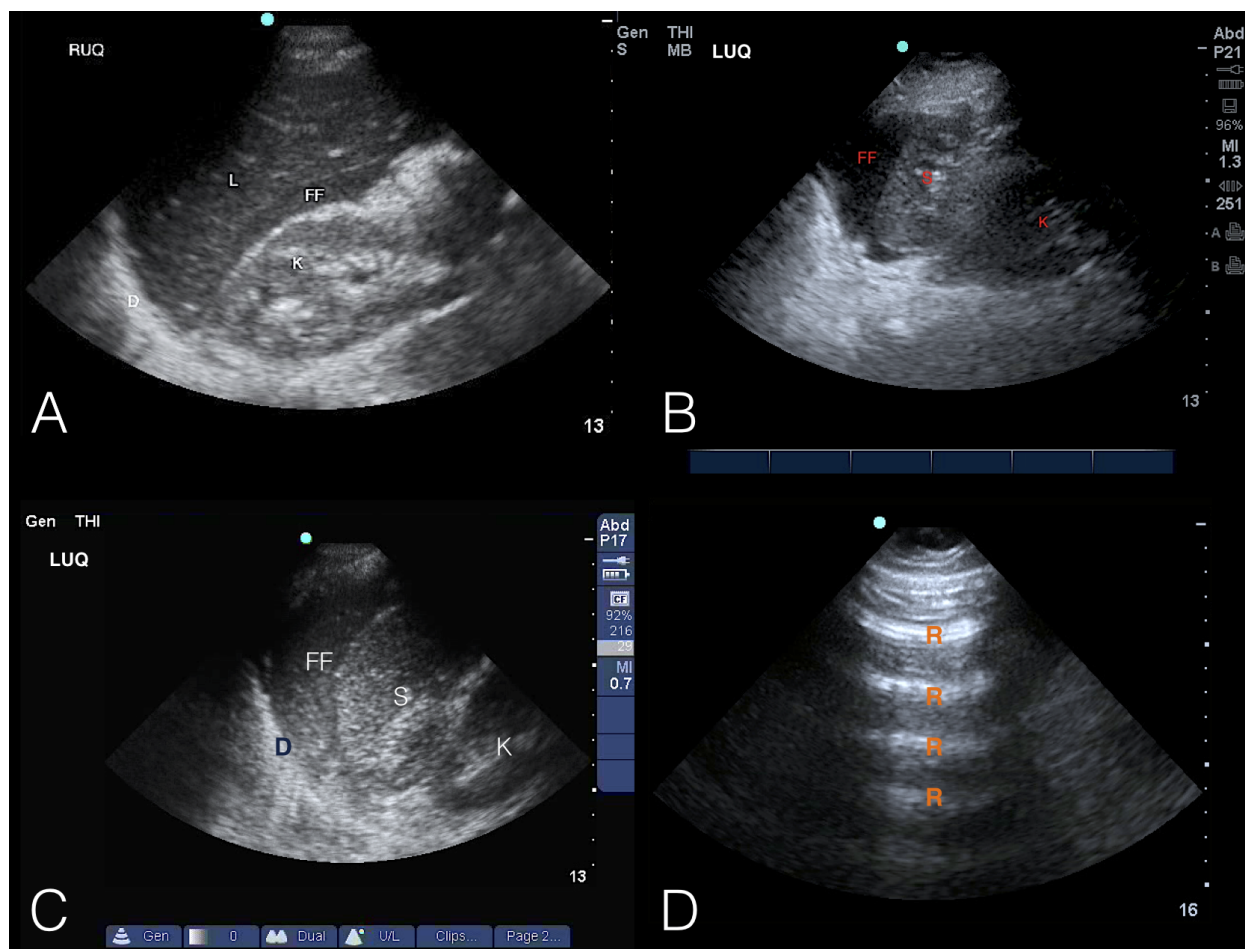
## 2. Case presentation

### 2.1. Chronic pancreatitis with abdominal and back pain

A 42-year-old man with history of chronic pancreatitis presented to the ED complaining of a sudden onset of upper abdominal pain associated with nausea and non-bloody vomiting. The patient also reported having had "indigestion" in the past that caused pain similar to what he was experiencing at the time, though much less in intensity. At presentation the patient was pale and in obvious severe discomfort, tachycardic and hypotensive. On exam, he had significant tenderness in the epigastric region. A bedside abdominal US was performed that revealed the presence of free air and free fluid in the abdomen (Figure 1 and 2). Abdominal X-ray confirmed the presence of free air under the diaphragm and intra-operative findings showed a perforated duodenal ulcer.

\*Corresponding Author: Hamid Shokoohi; 2120 L Street NW, Suite 450, Washington, DC 20037. Tel: 001202 741 2911 Fax: 001202 741-2921 E-mail: shokoohi@gwu.edu.





**Figure 1:** Ultrasonographic images in the coronal view of right and left upper quadrants (A, B, C) and a sagittal view of the anterior right upper quadrant (D). LUQ: left upper quadrant; RUQ: right upper quadrant; FF: echogenic (dirty) free fluid; K: kidney; S: spleen; L: liver; R: reverberation.

### 2.2. Severe abdominal and back pain with hypotension

A 56-year-old female patient presented to the ED with severe abdominal and back pain. Her pertinent medical history included hypertension, diabetes, coronary artery disease and chronic back pain. On arrival, the patient was hypotensive and tachycardic, with diffuse abdominal tenderness and rebound. The US revealed an unexplained collection of echogenic (dirty) free fluid in the left upper quadrant (Figure 1-B). Abdominal computed tomography (CT) identified the presence of pneumoperitoneum and a perforated duodenal ulcer was detected in surgery.

### 2.3. Abdominal pain after colonoscopy

A 57-year-old woman with history of diverticulosis presented to the ED in the evening, after having a colonoscopy earlier in the day, complaining of epigastric pain and obstipation.

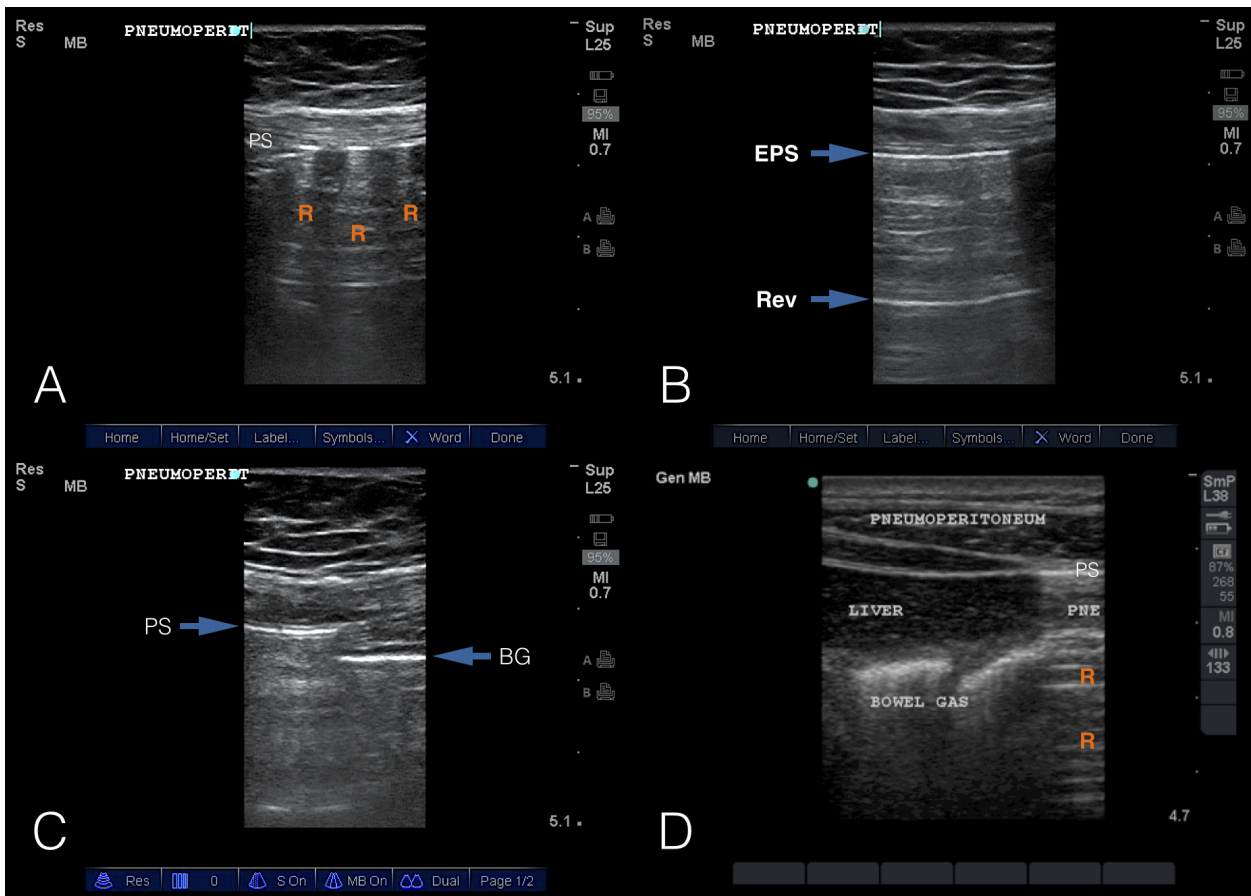
A flat and upright abdominal X-ray was obtained, which showed pneumoperitoneum. Bedside US (Figure 2 B), showed enhancement of the peritoneal stripe consistent with pneumoperitoneum, which were confirmed on surgery.

### 2.4. Alcoholism and upper GI bleeding

A 45-year-old male patient with prolonged history of alcoholism presented to ED with hematemesis. While he remained persistently hypotensive despite medical treatment, underwent US that revealed echogenic free fluid and evidence of pneumoperitoneum (Figure 2D). Surgery showed perforated posterior wall gastric ulcer.

### 2.5. Scanning protocol

The US images were obtained by EPs experienced in emergency US, using Sonosite Micro Maxx and M-turbo systems



**Figure 2:** Ultrasonographic images in the sagittal view of the anterior right upper quadrant and epigastric regions. PS: peritoneal stripe; EPS: enhancement of the peritoneal stripe; R or Rev: reverberation artifacts; BG: intraluminal bowel gas.

(Sonosite, Bothell, WA) and a multi-frequency (13-6 or 10-5 MHz) linear array transducer or 5-2 MHz phased array transducer. The patients were examined in a supine position to facilitate accumulation of free air at the anterior portion of the peritoneum (the least dependent area near the abdominal wall). The patients may also be positioned in the oblique and left lateral decubitus position (right side up), to allow free air to move between the liver and the abdominal wall, thereby facilitating differentiation between intra-peritoneal air from intra-luminal bowel gas (5, 6). The scanning protocol consists of scanning the abdomen from the epigastrium through the right upper quadrant (RUQ) along transverse and longitudinal axes. A transverse view will help determining the interface between pneumoperitoneum located medially and normal bowel typically located more laterally (due to the air from pneumoperitoneum rising to the highest point in the abdomen) (3, 5, 6). Ultrasound findings of free air are based on analysis of the echogenicity, reverberation artifact, location and relative mobility of the free air with respect to identified anatomical landmarks (5, 6).

### 3. Key US findings of perforated viscus

#### 3.1. Echogenic free fluid (dirty fluid)

This dependent fluid appears similar to the typical positive FAST examination in the trauma patient, with the exception of echogenic debris distributed throughout the fluid. This debris is a result of gastric or enteric contents that contain food particles that reflect the US beam, producing at times a swirling cloudy fluid (Figure 1).

#### 3.2. Ring-down or reverberation artifact (dirty shadows)

Air anti-dependently will show up as echogenic areas with posterior reverberation artifacts and “dirty” shadowing that are due to reflection of echoes at the air-soft tissue interface. These reverberations localize to the least dependent areas of the peritoneal cavity and shift with patient position (Figure 2 A and D).



### 3.3. Enhanced peritoneal stripe sign (EPSS)

Air inside the peritoneal cavity will tend to rise anteriorly in the supine patient until it contacts the anterior peritoneal lining. The resultant bright white stripe at the junction of the abdominal wall with the peritoneal cavity demonstrates an increased echogenicity compared with neighboring normal peritoneal stripe, due to immediately adjacent free air acting as a bright reflector. This is most easily seen between the liver and the abdominal wall of the right upper quadrant due to minimal bowel present at this location (Figure 2 B, C, and D).

### 3.4. Shifting phenomenon (Shifting Shadows)

The free intra-peritoneal air will move with patient movement to the most anti-dependent area of the peritoneal space. This is most easily seen as movement of the enhanced peritoneal stripe from the anterior epigastrium to the lateral aspect of the liver as the patient switches from the supine to the left lateral decubitus position.

## 4. Discussion

In patients with abdominal pain, US is often utilized to look for abdominal aortic aneurysm (AAA), gallbladder disease, kidney disease, and free intra-peritoneal fluid. The discovery of unexplained abdominal free fluid should prompt further abdominal scanning to look for the presence of pneumoperitoneum, which would indicate the diagnosis of perforated viscus. In these cases, the free fluid may not be completely anechoic, and may appear as non-homogeneous or “dirty” free fluid as the result of gastric content in the fluid. This is an important differentiation, as simple free fluid in hemodynamically stable trauma patient leads to further imaging with CT, whereas pneumoperitoneum in the right clinical setting should be expedited to the operating room. Pneumoperitoneum is a striking radiological finding that, when found, is almost always indicative of severe intra-abdominal pathology. It is generally accompanied by prominent clinical findings consistent with the need for immediate surgical intervention. The case series described in this paper supports the use of bedside abdominal US as a valuable clinical bedside tool for identifying free air in the peritoneum. It seems that, US will help optimizing acute abdomen patients management as well as expedite early operation. This utility could be easily integrated into the abdominal scanning of the ED patient with abdominal pain looking for evidence of ruptured AAA, investigating undifferentiated hypotension, and hemoperitoneum.

## 5. Appendix

### Acknowledgements

None

### Author contribution

All authors met the four criteria of authorship contribution, recommended by International Committee of Medical Journal Editors.

### Funding and support

This is a non-funded study, with no compensation or honoraria for participation, consulting or conducting the study. Resources required for this project was provided by institutional departmental funds at the George Washington University, Department of Emergency Medicine, with no particular budgeting allocated to this project.

### Conflict of interest

The authors do NOT have a financial interest or relationship to disclose regarding this research project.

## References

1. Physicians ACoE. Emergency ultrasound guidelines 2008. Policy Statement Available at: <http://www3.acep.org/acepmembership.aspx>. 2009
2. Chen SC, Wang HP, Chen WJ, Lin FY, Hsu CY, Chang KJ, et al. Selective use of ultrasonography for the detection of pneumoperitoneum. *Academic emergency medicine*. 2002;9(6):643-5.
3. Grechenig W, Peicha G, Clement H-G, Grechenig M. Detection of pneumoperitoneum by ultrasound examination: an experimental and clinical study. *Injury*. 1999;30(3):173-8.
4. McStay C, Ringwelski A, Levy P, Legome E. Hollow viscus injury. *The Journal of emergency medicine*. 2009;37(3):293-9.
5. Karahan OI, Kurt A, Yikilmaz A, Kahrman G. New method for the detection of intraperitoneal free air by sonography: scissors maneuver. *Journal of Clinical Ultrasound*. 2004;32(8):381-5.
6. Jones R. Recognition of pneumoperitoneum using bedside ultrasound in critically ill patients presenting with acute abdominal pain. *The American journal of emergency medicine*. 2007;25(7):838-41.
7. Blaiwas M, Kirkpatrick AW, Rodriguez-Galvez M, Ball CG. Sonographic depiction of intraperitoneal free air. *Journal of Trauma and Acute Care Surgery*. 2009;67(3):675.
8. Hoffmann B, Nurnberg D, Westergaard MC. Focus on abnormal air: diagnostic ultrasonography for the acute



abdomen. European Journal of Emergency Medicine.  
2012;19(5):284-91.

