

## Himmelfarb Health Sciences Library, The George Washington University Health Sciences Research Commons

---

Urology Faculty Publications

Urology

---

7-2018

# Atypical presentation of obstructed hemivagina and ipsilateral renal anomaly


Christopher Grant  
*George Washington University*

Christopher E. Bayne  
*George Washington University*

N. Kern

Craig A. Peters  
*George Washington University*

Follow this and additional works at: [https://hsrc.himmelfarb.gwu.edu/smhs\\_uro\\_facpubs](https://hsrc.himmelfarb.gwu.edu/smhs_uro_facpubs)


 Part of the [Female Urogenital Diseases and Pregnancy Complications Commons](#), and the [Urology Commons](#)

---

### APA Citation

Grant, C., Bayne, C. E., Kern, N., & Peters, C. A. (2018). Atypical presentation of obstructed hemivagina and ipsilateral renal anomaly. *Urology Case Reports*, 19 (). <http://dx.doi.org/10.1016/j.eucr.2018.05.011>

This Journal Article is brought to you for free and open access by the Urology at Health Sciences Research Commons. It has been accepted for inclusion in Urology Faculty Publications by an authorized administrator of Health Sciences Research Commons. For more information, please contact [hsrc@gwu.edu](mailto:hsrc@gwu.edu).



## Pediatrics

## Atypical presentation of obstructed hemivagina and ipsilateral renal anomaly

Campbell Grant<sup>a</sup>, Christopher E. Bayne<sup>b</sup>, Nora G. Kern<sup>c</sup>, Craig A. Peters<sup>d,\*</sup><sup>a</sup> Department of Urology, The George Washington University, Washington, DC, USA<sup>b</sup> Division of Pediatric Urology, Children's National Medical Center, Washington, DC, USA<sup>c</sup> Department of Urology, University of Virginia, Charlottesville, VA, USA<sup>d</sup> Department of Urology, Children's Medical Center, The University of Texas Southwestern, Dallas, TX, USA

## Introduction

Herlyn-Werner-Wunderlich Syndrome, otherwise known as obstructed hemivagina and ipsilateral renal anomaly (OHVIRA), is a rare Müllerian anomaly consisting of uterine didelphys, hemivaginal septum, and ipsilateral renal agenesis. Patients often present at the onset of menarche with abdominal pain and a pelvic mass from an obstructed hemivagina. We report a child who presented with a febrile urinary tract infection and upon further workup was found to have OHVIRA.

## Case

A previously well 5 month-old term female presented with a febrile urinary tract infection. Prenatal history was only significant for maternal urine drug screen at delivery positive for cocaine, opiates, and alcohol. Renal and bladder sonogram shortly after birth revealed a large left kidney without evidence of hydronephrosis and a distended bladder with debris. The right kidney was not visualized. Voiding cystourethrogram demonstrated left grade III vesicoureteral reflux into the lower pole of a duplicated system. The bladder appeared compressed anteriorly and to the left. Intravenous pyelogram showed a non-dilated left duplex collecting system with two ureters coursing to the pelvis with persistent leftward displacement of a distended bladder (Fig. 1). Given the constellation of radiographic findings, repeat transabdominal sonogram during bladder catheterization revealed a cystic mass in the pelvis entirely separate from the bladder. Finally, magnetic resonance imaging illustrated complete duplication of the left kidney, a cystic dysplastic right kidney, a dilated right uterine horn and hemivagina, and a left laterally displaced bladder (Fig. 2).

At 6 months of age, the patient underwent examination under anesthesia that confirmed the presence of a duplicated vagina with an obstructed right hemivagina (Fig. 3). A transvaginal resection of a segment of the inter-vaginal septum decompressed the right obstructed hemivagina. The edges were oversewn to maintain a patent window.

The patient underwent right laparoscopic nephrectomy at 3 years of

age for presumed ectopic ureteral insertion of the ureter from the right multicystic dysplastic kidney. She is now 9 years old and has been asymptomatic through follow-up.

## Discussion

The term obstructed hemivagina and ipsilateral renal anomaly otherwise known as Herlyn-Werner-Wunderlich Syndrome was originally described in the 1970's to describe a rare congenital syndrome that included renal dysplasia, ipsilateral blind hemivagina, bicornuate uterus without connection to a simple vagina and ureteral aplasia. It is postulated the Wolffian duct has an inducing function in appropriate Müllerian development, and failure of fusion between the mesonephric system and urogenital sinus may explain the associated uterine bud, Müllerian tubercle, and urogenital sinus abnormalities.<sup>1</sup> Approximately 2% of female patients with unilateral renal agenesis or multicystic dysplastic kidney will have OHVIRA syndrome.<sup>2</sup>

The age and presentation of our patient is unique. The majority of OHVIRA patients usually have normal external genitalia and age-appropriate developmental milestones and only present after onset of menarche secondary to obstructive hematocolpos. In two separate series by Smith et al. and Gholoum et al., the youngest case of OHVIRA was reported in a 10 year-old.<sup>3,4</sup> Smith et al. reported one case of contralateral urinary tract duplication in 27 cases of obstructed hemivaginas. At the onset of menarche, patients with OHVIRA often develop hematocolpos that can become infected leading to pelvic inflammatory disease, abscesses, or endometriosis that can cause infertility. Diagnosing OHVIRA at an earlier age can prevent some of those complications and improve fertility. Friedman et al. recommended informing patients at birth of the association between unilateral renal agenesis and Müllerian abnormalities, and to also inform the child's pediatrician so that they can monitor for possible complications associated with OHVIRA. They also recommended pelvic ultrasound at the onset of puberty and early surgical management of girls with OHVIRA to prevent complications.<sup>5</sup>

\* Corresponding author.

E-mail address: [craig.peters@childrens.com](mailto:craig.peters@childrens.com) (C.A. Peters).

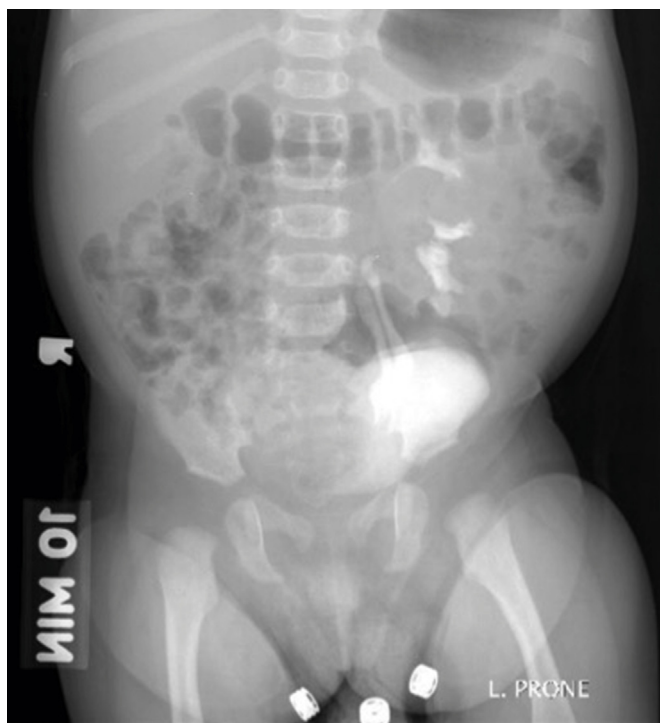

Fig. 1. IVP showing duplicated left collecting system and mass effect in the pelvis.

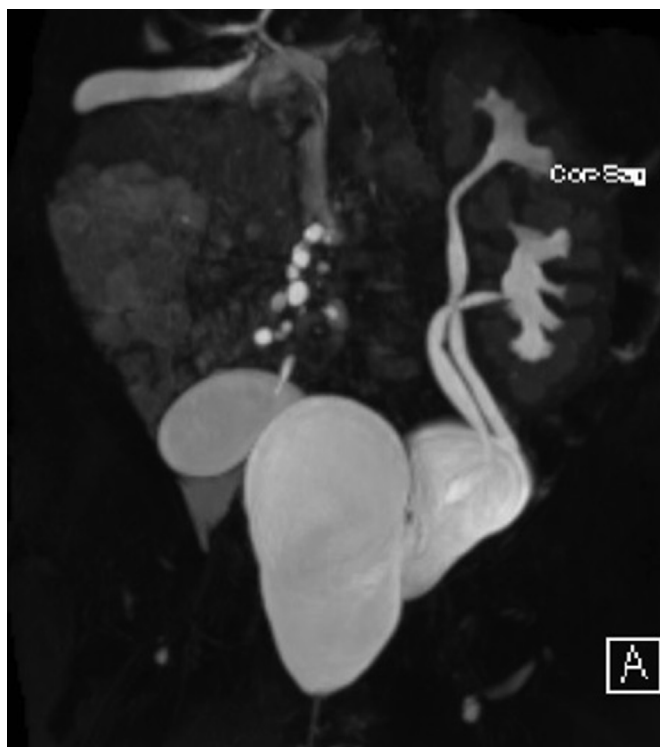


Fig. 2. Magnetic resonance imaging (T2 phase) demonstrating a dysplastic right kidney with dilated right uterine horn and obstructed hemi-vagina as well as a left collecting system duplication.

## Conclusion

While OHVIRA cases usually present at an older age, it is important

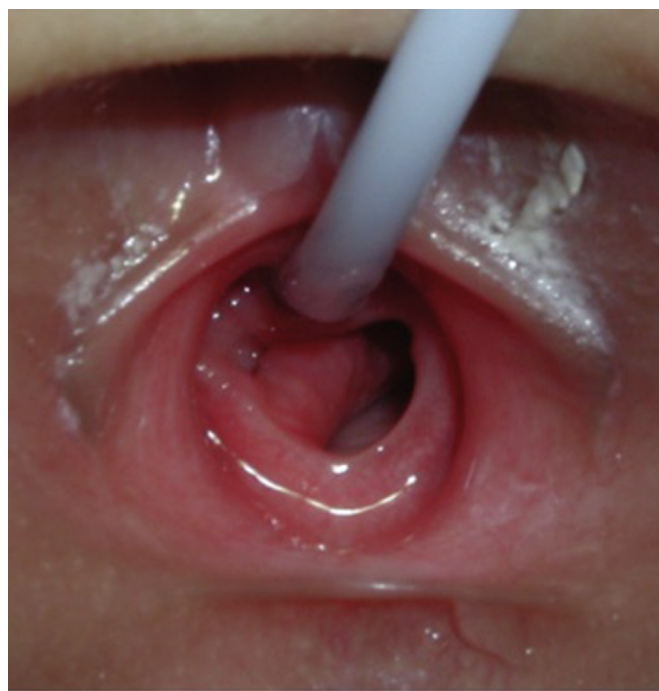


Fig. 3. Examination under anesthesia revealing a bulging intervaginal septum (along right side of vaginal canal; note a catheter is in the urethral meatus).

to keep this in the differential diagnosis in female patients with renal agenesis who present to the pediatric urologist for consultation. Pelvic ultrasound can be used leading up to puberty to screen these patients in order to prevent side effects such as hematocolpos.

## Appendix A. Supplementary data

Supplementary data related to this article can be found at <http://dx.doi.org/10.1016/j.eucr.2018.05.011>.

## References

1. Ación P, Ación M, Sánchez-Ferrer M. Complex malformations of the female genital tract. New types and revision of classification. *Hum Reprod*. 2004;19(10):2377–2384. <http://dx.doi.org/10.1093/humrep/deh423>.
2. Han JH, Lee YS, Im YJ, Kim SW, Lee M-J, Han SW. Clinical implications of obstructed hemivagina and ipsilateral renal anomaly (OHVIRA) syndrome in the prepubertal age group. Kim S, ed. *PLoS One*. 2016;11(11):e0166776 <http://dx.doi.org/10.1371/journal.pone.0166776>.
3. Smith NA, Laufer MR. Obstructed hemivagina and ipsilateral renal anomaly (OHVIRA) syndrome: management and follow-up. *Fertil Steril*. 2007;87(4):918–922. <http://dx.doi.org/10.1016/j.fertnstert.2006.11.015>.
4. Gholoum S, Puligandla PS, Hui T, Su W, Quiros E, Laberge J-M. Management and outcome of patients with combined vaginal septum, bifid uterus, and ipsilateral renal agenesis (Herlyn-Werner-Wunderlich syndrome). *J Pediatr Surg*. 2006;41(5):987–992. <http://dx.doi.org/10.1016/j.jpedsurg.2006.01.021>.
5. Friedman MA, Aguilar L, Heyward Q, Wheeler C, Caldamone A. Screening for Mullerian anomalies in patients with unilateral renal agenesis: leveraging early detection to prevent complications. *J Pediatr Urol*. February 2018. <http://dx.doi.org/10.1016/j.jpuro.2018.01.011> In press.