

FORUM

Development Goals or other campaigns. While facility-level staff are often urged to 'improve' performance, they have difficulty assessing quantitatively how their facility should contribute to the intended outcome of each strategic initiative. The tool uses data that are readily available to district managers for the purpose of setting targets, measuring progress and optimising resources at each facility.

1. HIV & AIDS and STI Strategic Plan for South Africa. 2007-2011. <http://www.info.gov.za/otherdocs/2007/aidspan2007/index.html> (accessed 2 December 2009).

2. Geffen N. HAART coverage and unmet need in South Africa. *HIV Treat Bull* 2009; 10(5/6): 26.
3. Actuarial Society of South Africa. ASSA2003. <http://aids.actuarialsociety.org.za/ASSA2003-Model-3165.html> (accessed 2 December 2009).
4. World Health Organization. *Rapid Advice: Antiretroviral Therapy for HIV Infection in Adults and Adolescents*. 30 Nov 2009. <http://www.who.int/hiv/pub/arv/advice/en/index.html> (accessed 12 January 2010).
5. Barker P, Venter F. Setting district-based annual targets for HAART and PMTCT – a first step in planning effective intervention for the HIV/AIDS epidemic. *S Afr Med J* 2007; 97(10): 916-917.
6. Barker PM, McCannon CJ, Mehta N, *et al*. Strategies for scale-up of antiretroviral treatment in South Africa through health system optimization. *J Infect Dis* 2007; 196 Suppl 3: S457-463.
7. Pantaleo G, Graziosi C, Fauci AS. New concepts in the immunopathogenesis of human immunodeficiency virus infection. *N Engl J Med* 1993; 328: 327-335.

CLINICAL IMAGES

Reversible nephrotic syndrome secondary to pulmonary hydatid disease

Tahar Gargah, Rim Goucha-Louzir, Youssef Gharbi, Rachid Mohamed Lakhoua

Most patients with pulmonary hydatidosis are children. The disease may be asymptomatic or revealed by unusual events such as a glomerulopathy.¹

Case report

An 8-year-old boy from a rural part of Tunisia presented with generalised oedema and macroscopic haematuria. There was no familial history of renal disease. He had a normal blood pressure (100/60 mmHg), and a pleural effusion was detected. Urinalysis showed nephrotic range proteinuria (375 mg/kg/d) and microscopic haematuria. His serum total protein concentration was 40 g/l and his serum albumin was 10 g/l. Renal biopsy showed capillary wall thickening and duplication, and mesangial cell proliferation in the glomeruli, characteristic of mesangiocapillary glomerulonephritis. Renal and abdominal ultrasound images showed increased echogenicity of the kidneys and mild ascites. Radiology revealed three large pulmonary hydatid cysts (Figs 1 and 2). The largest cyst occupied the entire right upper lobe and compressed the superior vena cava. Hydatid disease was confirmed by a strongly positive serum enzyme-linked immunosorbent assay (ELISA) for echinococcus.

The patient was treated with high protein intake, dipyridol and captopril; both right lung cysts were resected,

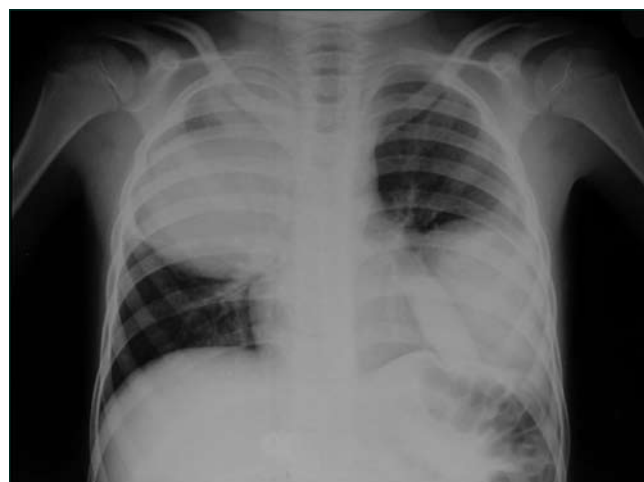

Fig. 1. Chest radiograph showing a bilateral well-circumscribed dense lesion.

followed by the left pulmonary cyst 4 weeks later. Hydatid cyst was confirmed histopathologically. He recovered well, the serum ELISA for echinococcus became negative, and follow-up urine examination and thoracic computerised tomography were normal 6 months after surgery, confirming good renal recovery and absence of pulmonary hydatid disease.

Discussion

Renal involvement during hydatid disease is well recognised.¹ The most common manifestation is proteinuria, with or without nephrotic syndrome. Several histopathological types have been demonstrated.¹⁻³ The pathogenesis of glomerular disease in patients with hydatid disease is not well understood, with most supporting an immune complex-mediated mechanism. Echinococcal antigen and corresponding antibody in the glomeruli have been demonstrated by immunoperoxidase studies.⁴ The site of

Tahar Gargah, Rim Goucha-Louzir and Rachid Mohamed Lakhoua are based at the Charles Nicolle Hospital in Tunis, Tunisia, and Youssef Gharbi in the Department of Paediatric Surgery at the Habib Thameur Hospital in Tunis.

Corresponding author: Tahar Gargah (kitomora@yahoo.fr)

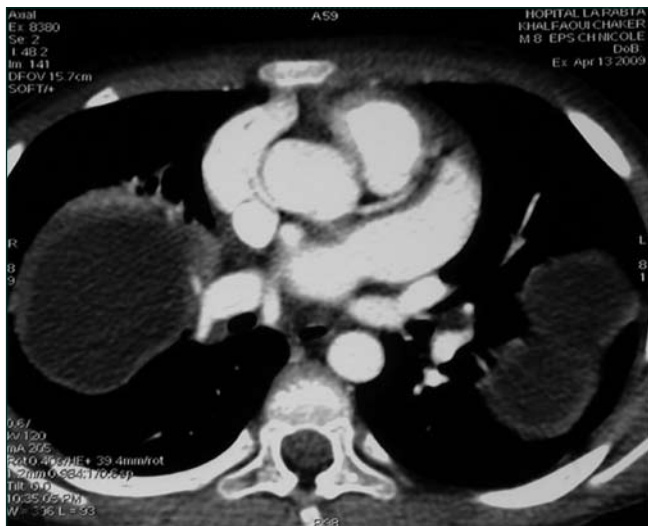


Fig. 2. CT scan showing bilateral hydatid cysts of the lungs.

the hydatid cyst appears to be crucial in the development of glomerular damage, since all reported cases are of either hepatic or pulmonary location. However, this deduction may be unfounded as hydatids occur most frequently in these locations.

Renal involvement during hydatid disease is not confined to the glomeruli. A case of predominantly chronic tubulo-interstitial nephritis with mesangioproliferative glomerulonephritis in a patient with hepatic hydatid cyst which responded to cyst resection was reported.⁵ In our patient, the lesions were confined to the glomeruli which have the typical features of a mesangiocapillary glomerulonephritis. Most cases of glomerular lesions associated with hydatid disease, including ours, are reversible by medical or surgical treatment of the hydatid;³ this demonstrates the causal relationship between hydatid disease and glomerulopathy. Our observation is believed to be the first in a child in the first decade, with renal histological confirmation.

1. Velthuisen V, Florquin S. Glomerulopathy associated with parasitic infections. *Clin Microbiol Rev* 2000; 13: 55-66.
2. Gelman R, Brook G, Green J, Ben-Itzhak O, Nakhoul F. Minimal change glomerulonephritis associated with hydatid disease. *Clin Nephrol* 2000; 53: 152-155.
3. Covic A, Mititiuc I, Caruntu L, Goldsmith DJA. Reversible nephrotic syndrome due to mesangiocapillary glomerulonephritis secondary to hepatic hydatid disease. *Nephrol Dial Transplant* 1996; 11: 2074-2076.
4. Edelweiss MI, Daudt HM, Goldstein HF, Garcia C. Hepatic hydatidosis with glomerular involvement: report of a case. *Rev Assoc Med Bras* 1992; 38: 31-32.
5. Aziz F, Panday T, Patel H, et al. Nephrotic presentation in hydatid cyst disease with predominant tubulointerstitial disease. *Int J Nephrol Renovasc Dis* 2000; 2: 23-26.

SAMF

South African Medicines Formulary

9
Ninth
Edition

The ESSENTIAL REFERENCE for every healthcare professional!

The carefully and thoroughly updated 9th edition of the South African Medicines Formulary (SAMF) can now be ordered. It is your essential reference to rational, safe and cost-efficient use of medicines. That is why you should not prescribe without it.

The newly published SAMF provides easy access to the latest, most scientifically accurate information – including full drug profiles, clinical notes and special prescriber's points. The convenient pocket-size design enables you to fit it comfortably into your bag or hospital coat pocket – always at hand for ready reference.

WHY YOU SHOULDN'T BE WITHOUT THE SAMF 9TH EDITION

The new 9th edition of SAMF provides expanded information on key issues facing South African healthcare professionals today, including antiretrovirals, TB treatment guidelines, management guidelines for asthma and chronic heart failure, other common chronic conditions and prescribing in sport.

- It presents practical, new approaches to the management of venomous bites and stings.
- It outlines extensively the acute adverse reactions to drugs of abuse, and their management.
- It features new as well as existing drugs, indexed by both trade and generic names.
- It offers fresh insights into informed prescribing and carries cautionary guidelines on drug interactions and a range of special risk patients and conditions.

And, as always, you can rely on...

- the professional compilation and editing by a team from the Division of Clinical Pharmacology, UCT
- an independent and unbiased guide on prescribing in South Africa today
- the indication of agents included in the SA and WHO essential drug lists
- support of the SA national drug policy
- guidance for prescribing during pregnancy and lactation, and in patients with porphyria, liver disease and renal impairment (including tables with drug dosage adjustments); and
- indexed and page tabs for quick and easy access to each section.

YOUR SATISFACTION IS GUARANTEED

3 easy order options:

1. PHONE EDWARD OR BYRON – 021 6817000
2. FAX the completed SAMF order form to 0866006218
3. EMAIL: edwardm@hmpg.co.za OR byronm@hmpg.co.za

