

Himmelfarb Health Sciences Library, The George Washington University Health Sciences Research Commons

Neurology Faculty Publications

Neurology

5-2016

Expert opinion regarding invasive monitoring: from surface to depth

Mohamad Z. Koubeissi
George Washington University

Follow this and additional works at: https://hsrc.himmelfarb.gwu.edu/smhs_neuro_facpubs

 Part of the [Neurology Commons](#)

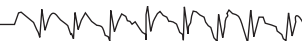APA Citation

Koubeissi, M. Z. (2016). Expert opinion regarding invasive monitoring: from surface to depth. *Epilepsy Currents*, 16 (3).
<http://dx.doi.org/10.5698/1535-7511-16.3.206>

This Journal Article is brought to you for free and open access by the Neurology at Health Sciences Research Commons. It has been accepted for inclusion in Neurology Faculty Publications by an authorized administrator of Health Sciences Research Commons. For more information, please contact hsrc@gwu.edu.

Q-PULSE Survey Commentary

Epilepsy Resources and Updates



Expert Opinion Regarding Invasive Monitoring: From Surface to Depth

Mohamad Koubeissi, MD

MFA Neurology, The George Washington University, Washington, DC

Correspondence: The George Washington University, 2150 Pennsylvania Ave NW, MFA Neurology Suite 7-404, Washington, DC 20037; email: mkoubeissi@mfa.gwu.edu

Disclaimer: The Q-PULSE results presented here represent the aggregate responses of epileptologists to a survey to assess opinions and/or approaches to issues in clinical epilepsy care. The results are not derived from a formal clinical or scientific trial. Q-PULSE results should not substitute for existing clinical evidence or clinical judgment in patient care and do not represent a practice parameter or practice recommendation.

Extraoperative invasive monitoring is essential for localization of the seizure focus and cortical mapping in patients with medically intractable focal epilepsy. While planning the electrode implantation must be based on a solid presurgical hypothesis that takes into consideration a multitude of noninvasive tests, there are many factors that lead to variabilities across epileptologists in terms of what brain regions to sample and what types of electrodes to use. To take the value of seizure semiology as an example, seizures originating from the mesial temporal structures may manifest differently in different patients (1), while seizures originating from disparate cortical regions can manifest similarly (2). Another inconsistency is that some epileptologists implant areas where interictal epileptiform discharges (IEDs) are seen during noninvasive monitoring, while others do not. Additionally, although occasional studies have compared depth with subdural electrodes (3), stereoelectroencephalography (SEEG) has been historically preferred at European centers, while subdural monitoring has been trendier in the United States.

Another factor that can play a role in the epileptologist's preferred choice of electrode types and brain regions to implant in any particular case is their own experience. We, as humans, are programmed to have aversive reactions to situations that have previously proved noxious (e.g., when a patient has surgical complications with a particular type of electrode implantation, when there is a failure to identify the seizure focus with invasive electrodes, or when there is a poor seizure outcome). Such factors are more likely to be mitigated with more prolonged experience and larger surgical volumes. Thus, expert consensus can be helpful when there is no scientific evidence to suggest clear-cut guidelines.

Quantitative Practical Use-Driven Learning Survey in Epilepsy

Development

The "Quantitative Practical Use-Driven Learning Survey in Epilepsy" (Q-PULSE) was established in 2012 by the American Epilepsy Society (4) as a mechanism for quickly polling a panel of leaders in epilepsy care for their expert opinion on difficult or controversial questions for which high quality evidence or scientific data are lacking. The Q-PULSE panel consists of epileptologists selected from a broad cross-section of epilepsy centers across the United States. The Q-PULSE surveys are designed with the hope that their results may facilitate arriving at a working consensus, identifying areas of controversy, or identifying areas that need further research or education.

This Q-PULSE survey was developed to learn about current thinking or practice on approaches used in common presurgical circumstances. The survey was conceived by Robert Fisher, MD, PhD, Stanford, and further developed by the American Epilepsy Society Q-PULSE committee. The survey was open from December 17, 2015 to January 25, 2016, and 95 responses were received from the Q-PULSE panel of 169 members, for a response rate of 56%. The experts were asked about what type of invasive monitoring they use at their centers (Figure 1), and the survey ended for those who did not monitor patients invasively. For those who perform invasive monitoring, the following case was presented: "A 25-year-old man, with a history of childhood febrile seizures, has 1 to 4 complex partial seizures per month with déjà vu, arrest of activity, lip-smacking, fumbling, and impairment of awareness. 3T noncontrast MRI and FDG-PET are normal. Scalp EEG shows bilateral independent interictal spikes over the anterior-to-mid temporal regions. Scalp video-EEG monitoring captured seizures with bilateral rhythmical evolving temporal activity, poorly lateralized, and not evident until approximately 30 seconds after onset of behavioral seizures. MEG localizes bitemporal spikes, but captures no seizures. His seizures are drug-resistant and he is interested in having epilepsy surgery."

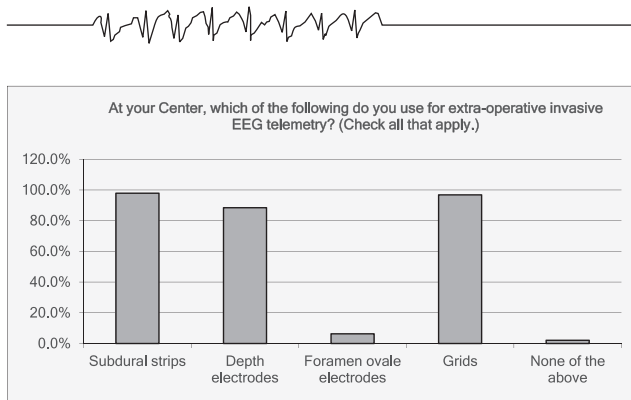


FIGURE 1.

Depth Electrodes

As regards the preferred invasive electrodes in the scenario above, 65% of surveyed experts chose depth electrodes (including lateral approach, posterior approach, and depth plus subdural strips), while 27% chose only bilateral strips (Figure 2). This probably indicates a surge of depth electrode use in American centers in recent years, which are historically more popular in Europe. Among the 27% who chose bilateral subdural strip monitoring, the majority would implant three strips on each side (64%), and the others chose two strips (8%) or more than three (28%). Similarly, almost three-quarters of those who chose both strips and depth electrodes opted for two or three strips on each side, while the remaining one-quarter picked four or more strips.

For those who chose depth electrode monitoring, the next question was about which brain regions to implant. This was a very interesting question as it reflected how different experts extracted knowledge from neuroanatomy, including brain connectivity, and electroclinical features of seizures to use it in clinical epilepsy. All respondents chose the mesial temporal lobe as an area to be sampled, and none chose the occipital region. Less definitive consensus was reached regarding sampling the orbitofrontal region (42%), the insula (24%), and the supplementary motor area (15%). This is possibly because in some experts' experience the described scenario is less likely to be of extratemporal than temporal origin, coupled with preference to minimize the number of invasive electrodes because of the risk of bleeding (especially with insular implantation). Similarly, the majority (96.3%) of those who chose both strips and depth electrodes opted for sampling the mesial

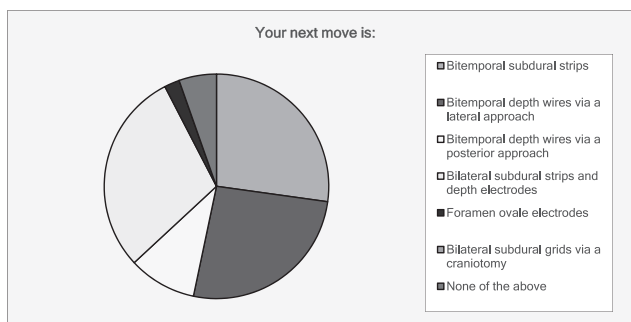


FIGURE 2.

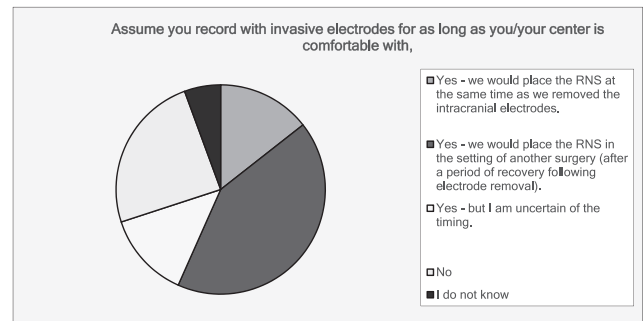


FIGURE 3.

temporal structures with only one expert (3.7%) choosing the occipital lobe.

Electrode Monitoring

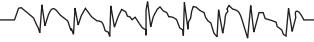The remaining questions pointed to a 70% consensus each. Regarding duration of monitoring, 70% said they would monitor the patient with invasive electrodes for up to 2 or 3 weeks, provided the patient was stable, while 27.7% chose 4 or more weeks (including 3 respondents who agreed with >8 weeks or monitoring). Also, close to 70% of experts would monitor their patients in the intensive care unit the night after implantation, and approximately one-quarter of them send patients from recovery room to the floor. Finally, 70% said they would recommend bilateral responsive neurostimulation (RNS) if invasive monitoring succeeded in only capturing bilateral IEDs but no seizures (Fig. 3).

Conclusions

In conclusion, this survey suggests an increased use in recent years of depth electrode monitoring in the United States, while subdural monitoring continues to be very commonly used (Fig. 1). It is encouraging to know that many centers offer both kinds of electrode implantation because they each offer different kind of information. For example, on the one hand, when the seizure focus is believed to be on the surface and mapping is needed, subdural electrodes can be very helpful. On the other hand, depth electrodes may be better for deep lesions, including mesial temporal or for bilateral monitoring. Also, the combination of subdural grids and depth electrodes may be used in selected patients (5). The survey also suggests a high propensity of using RNS at numerous American centers. This is particularly interesting because it is classical teaching that no surgical decisions must be based on IEDs alone as they are not an indicator of the epileptogenic zone. However, RNS is reversible and can serve as a prolonged monitoring technique that guides further surgical options down the road.

References

1. Toydemir HE, Özkara Ç, Uysal O, Ozyurt E, Uzan M. Complete seizure freedom is possible in patients with MTL-HS after surgery in spite of extratemporal electro-clinical features. *Epilepsy Res* 2015;113:104–112.
2. Kovac S, Diehl B, Wehner T, Fois C, Toms N, Walker MC, Duncan JS. Gelastic seizures: incidence, clinical and EEG features in adult patients undergoing video-EEG telemetry. *Epilepsia* 2015;56:e1–e5.



3. Sperling MR, O'Connor MJ. Comparison of depth and subdural electrodes in recording temporal lobe seizures. *Neurology* 1989;39:1497–1504.
4. French JA. Taking the "Pulse" of our society with Q-PULSE. *Epilepsy Curr Am Epilepsy Soc* 2013;13:304.
5. Munyon CN, Koubeissi MZ, Syed TU, Lüders HO, Miller JP. Accuracy of frame-based stereotactic depth electrode implantation during craniotomy for subdural grid placement. *Stereotact Funct Neurosurg* 2013;91:399–403.