

Hook line and sinker

A O Laosebikan. V Manchev. S R Thomson

brought to you b

provided by South African Medical Jo

We would like to report that we have now found the 'sinker'. The iron bar weighed in at 2.5 kg and was retrieved by colotomy (Fig. 1).

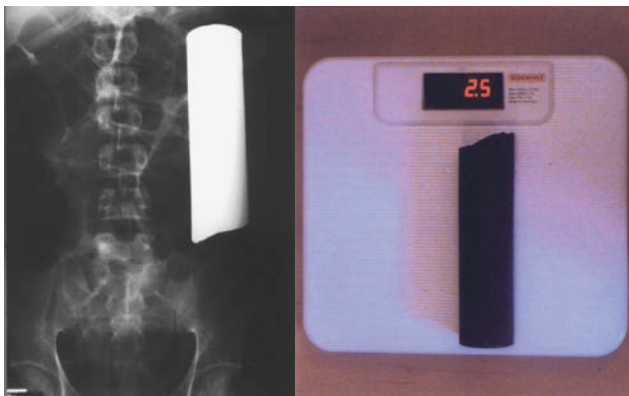


Fig. 1. The bar in the sigmoid colon (as seen on a plain abdominal radiograph) and at weigh-in.

1. Anderson F, Thomson SR. Hook line and finger. *S Afr Med J* 2001; **91**: 494.

A O Laosebikan is a consultant surgeon at Grey's Hospital, Pietermaritzburg, where such extremes are rare. V Manchev, a graduate from Bulgaria with keen interest in surgery, is currently working as a medical officer at Grey's Hospital. S R Thomson is a Durban beachfront professor whose hospital is adjacent to the red light district where many, but obviously not all, such incidents occur.