



Islet neogenesis is stimulated by brief occlusion of the main pancreatic duct

Colin W Woodroof, Charon de Villiers, Benedict J Page, Lize van der Merwe, William F Ferris

Objective. Current models of islet neogenesis either cause substantial pancreatic damage or continuously stimulate the pancreas, making these models unsuitable for the study of early events that occur in the neogenic process. We aimed to develop a method where the initial events that culminate in increased pancreatic endocrine mass can be studied.

Design and methods. Ten 12-week-old female Wistar rats were subjected to a midline laparotomy, the pancreas was isolated and the main pancreatic duct was occluded for 60 seconds. The pancreas was released and carefully relocated within the abdomen. Ten age-, strain- and sex-matched control rats were subjected to a sham operation. The animals were killed 56 days post occlusion, and the pancreata excised and fixed for histological analysis. Body, pancreatic and hepatic weights were noted at termination and serum was taken for analysis. The endocrine-to-exocrine ratio was calculated and the

number of endocrine cells in each islet from the sectioned pancreata was counted.

Results. Occlusion of the main pancreatic duct for 60 seconds results in an increase in endocrine mass by 80% 56 days post occlusion. This constitutes an increase in endocrine units (1 - 6 cells), and in small (7 - 30 cells), medium (31 - 60 cells) and large (> 60 cells) islets by 85%, 96%, 95% and 71% respectively.

Conclusion. Brief occlusion of the main pancreatic duct results in an increase in pancreatic endocrine mass. An increase in endocrine units and small islets is indicative of islet neogenesis. Therefore, owing to the briefness of the stimulation, this model can therefore be used to study the initial events that occur during the neogenic process.

S Afr Med J 2004; 94: 54-57.

Long-term treatment regimens have been found to retard, but not completely abrogate, the progression of type 2 diabetes mellitus.¹⁻³ The disease is characterised by progressive beta-cell dysfunction and a loss of endocrine mass from the pancreas.⁴ New therapies are therefore required to stem this islet depletion and restore pancreatic function. One such therapy might be to stimulate the formation of new islets (neogenesis)^{5,6} within the adult pancreas. This would also be of use in the treatment of type 1 diabetes, where autoimmune reactions have destroyed beta cells. Understanding the mechanism by which the pancreas can be stimulated to increase endocrine mass is therefore of paramount importance in the search for new therapies.

Beta cells have a very low proliferative index in quiescent pancreas.⁷ Although it was once believed that beta cells could

not proliferate, it is now recognised that beta-cell mass can increase in normal individuals in response to hyperglycaemia, allowing for more efficient insulin production.^{8,9} This promotes homeostasis and facilitates euglycaemia. However, in patients with type 2 diabetes this compensation mechanism is faulty and results in a permanent loss of islet mass.¹⁰

An increase in islet mass can be promoted by surgical manipulation of the pancreas in rodents and non-human primates. Partial pancreatectomy (90%),^{11,12} main duct ligation^{13,14} or occlusion of the main pancreatic duct by wrapping the head of the pancreas with cellophane¹⁵ result in an increase in duct cell proliferation which is followed by increased endocrine mass. Although these manipulations are unsuitable for humans, understanding the biochemical signals that initiate this process in rodents could eventually lead to the recognition of specific pharmacological targets and the instigation of therapies to address the problem of beta-cell depletion that occurs during diabetes in humans.

Partial pancreatectomy and ligation of the main pancreatic duct lead to acute pancreatitis and therefore signals integral to the neogenic process are masked by pancreatic damage. Furthermore, 90% pancreatectomy leaves a small pancreatic stump, which has insufficient tissue for assaying enzymatic activity of candidate signalling molecules known to participate in cellular proliferation. Partial occlusion of the main pancreatic duct by wrapping the head of the pancreas with cellophane

Endocrinology and Metabolism Unit, Department of Internal Medicine, University of Stellenbosch, Tygerberg, W Cape

W F Ferris, PhD

Diabetes Research Group, Medical Research Council, Tygerberg, W Cape

C Woodroof, MSc

C de Villiers, Dip Lab An Tech

Department of Anatomy and Histology, University of Stellenbosch, Tygerberg, W Cape

B J Page, PhD

Biostatistics Unit, Medical Research Council, Tygerberg, W Cape

L van der Merwe, PhD



results in continuous stimulation of the pancreas, as the cellophane is left in place postoperatively until termination and may lead to secondary signals not involved in the neogenic process. Therefore these methods of promoting neogenesis are unsuitable for studying the early events that promote increased endocrine mass.

We have previously found that briefly occluding the main pancreatic duct for only 60 seconds elicits a near identical duct cell proliferative response to cellophane wrapping the pancreas.¹⁶ As cellophane wrapping promotes islet neogenesis we asked whether occlusion for 60 seconds would also result in an increase in pancreatic endocrine mass. If so, this stimulus could be used to examine the early events in the neogenic process, without the presence of confounding non-neogenic signals. Such a model could be used to identify the early events that occur during islet neogenesis and possibly lead to new therapies for diabetes in the future.

Materials and methods

Surgical procedure

Ten 12-week-old female Wistar rats (~180 g each in mass) were anaesthetised using 2% fluothane in oxygen. The animals were subjected to a midline laparotomy, the pancreas was isolated and the main pancreatic duct partially occluded by gently squeezing the head of the pancreas between the investigator's forefinger and thumb for 60 seconds. The pancreas was relocated in the abdomen, the laparotomy wound was closed and the animals were subjected to postoperative care. The rats were killed 56 days post occlusion. Pancreata were removed, fixed in formalin (pH 7.0) and used for morphological analysis. Serum was also collected for quantitative measurement of amylase, glucose and insulin. Ten age-, strain- and sex-matched rats were used as controls.

Tissue preparation and staining

Formalin-fixed pancreata were meticulously trimmed of other tissue, weighed and embedded in paraffin wax. Sections (4 µm) were cut across the whole pancreas and mounted on glass slides. The tissue sections were then de-waxed in xylene and rehydrated in serial dilutions of ethanol to water and stained with haematoxylin and eosin.

Analysis of pancreatic sections

Each tissue section was analysed without prior knowledge of any procedure that might have been performed on the rat. Sequential, non-overlapping fields of the whole tissue section were used to calculate the proportion of endocrine to exocrine tissue using a 25-point graticule (Pyser-SGI, UK) (Fig. 1).¹⁷ The number of cells in each islet in the section was also counted.

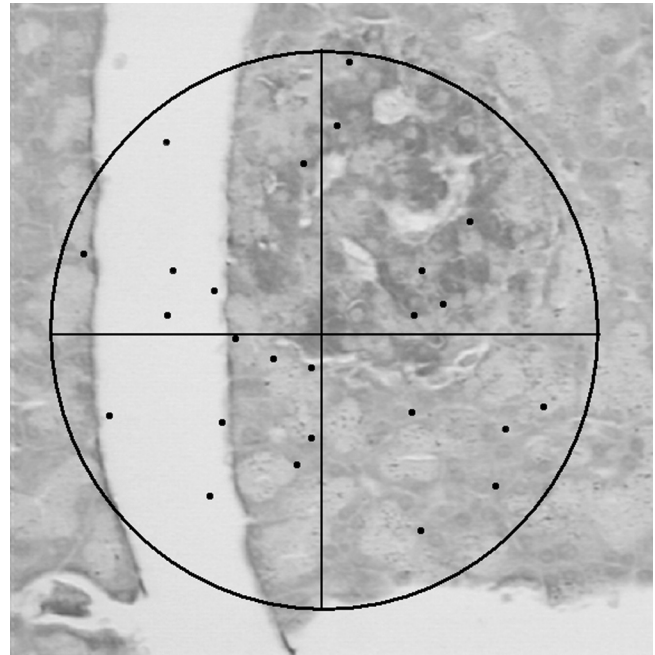


Fig. 1. A 25-point graticule in the eyepiece of a microscope was used to assess the endocrine-to-exocrine ratio. The number of dots falling on endocrine and exocrine tissue was noted for each field of view taken sequentially over the whole pancreatic section.

Serum insulin, glucose and amylase assays

Serum glucose, insulin and amylase were measured at termination in animals fasted overnight. Amylase levels were measured using Beckman amylase reagent, glucose with Technicon glucose (Glu-cinet) reagent and insulin with a Linco RIA kit.

Statistics

The *p*-values are for a one-sided *t*-test for no difference in means assuming that the variances are not necessarily equal.

Results

Brief occlusion of the main pancreatic duct does not significantly alter body weight (control = 182 g, occluded = 180 g, *p* = 0.747), liver weight (control = 25.5 g, occluded = 26.1 g, *p* = 0.630), plasma glucose (control = 3.4 mM, occluded = 3.5 mM, *p* = 0.592) or amylase (control = 706 u/l, occluded = 739 u/l, *p* = 0.694) levels measured at 56 days post occlusion. Animals subjected to brief occlusion of the main pancreatic duct appeared healthy, and morphological examination of pancreatic sections showed no obvious evidence of pancreatitis. The mean fasting insulin level of animals subjected to partial occlusion were significantly lower. However, all individual measurements were still within the



range of values seen in controls (control = 77.8 pM, occluded = 39.8 pM, $p = 0.038$). Further investigation examining another 12 animals subjected to duct occlusion showed no significant differences between this group and controls (data not shown).

Calculation of the endocrine-to-exocrine ratio revealed that this is increased by 37.5% in occluded pancreata compared with controls. Pancreatic weight, compared with body weight, was also increased by 24.5%. Knowing the pancreatic weight and endocrine-to-exocrine ratio enables the endocrine mass to be calculated. This was increased by 80% in occluded pancreata (Fig. 2).

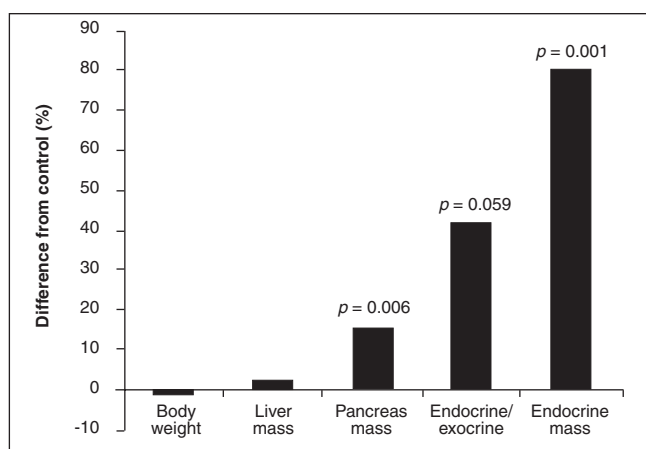


Fig. 2. Percentage differences between animals subjected to brief occlusion of the main pancreatic duct and controls. Mean body weight, liver mass/body weight, pancreas mass/body weight, endocrine-to-exocrine ratio and endocrine mass/body weight for occluded animals was calculated as a percentage of the control values. Organ mass was divided by body weight to compensate for increased organ size in larger animals.

The number of endocrine cells per islet for each pancreatic section was counted. Islets were then grouped into four categories, namely endocrine units (1 - 6 cells), small islets (7 - 30 cells), medium islets (31 - 60 cells) or large islets (> 60 cells). The mass increased in all islet types, with endocrine units, small, medium and large islets increased by 85%, 96%, 95% and 71% respectively.

Discussion

Current mono- and combination therapies for type 2 diabetes slow the progression of the disease, but do not stem the associated progressive beta-cell dysfunction and islet loss.¹⁻³ Consequently many patients will eventually require treatment with insulin regardless of the therapy employed. Alternative therapies are therefore needed to abrogate beta-cell dysfunction and islet depletion in type 2 diabetes and replenish lost beta cells in type 1 diabetes. One such therapy might be the stimulation of the formation of new islets within the pancreas.

Surgical manipulation of the pancreas can stimulate an increase in endocrine mass in rodents^{11,13-15,18} and non-human primates.¹⁹ Understanding the signals that initiate this process may lead to new therapeutic approaches which could be used in the treatment of diabetes in man. Current procedures such as partial pancreatectomy and total duct ligation result in substantial organ injury and pancreatitis. Furthermore cellophane wrapping continuously stimulates the pancreas as the cellophane remains tied around the head of the organ postoperatively. Therefore these procedures are unsuitable for the study of early events that lead to islet neogenesis due to the possible presence of confounding secondary signals.

Here we have shown that brief occlusion of the main pancreatic duct for 60 seconds stimulates a substantial increase in endocrine mass. As all islet types were increased new islet formation must have occurred. This increase in endocrine units and small islets is indicative of islet neogenesis.^{20,21}

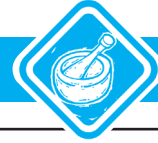Normal serum amylase levels and normal pancreatic morphology at 56 days post occlusion indicate minimal pancreatic damage. Animals subjected to duct occlusion were healthy and glycaemia was unchanged compared with controls. Fasting insulin levels of occluded animals were all in the lower third of the range observed for the controls. Conceivably the lower fasting insulin levels were due to the inability of beta cells to secrete insulin efficiently while undergoing cellular proliferation during the neogenic process. However, as glucose levels were not significantly different between occluded and control groups, indicating that insulin levels were sufficient to maintain euglycaemia, a further set of animals was subjected to ductal occlusion. Insulin levels from these animals were not significantly different from controls and also fell within the range of the control group. It was therefore assumed that the lower mean insulin level found in the group examined in this paper was not biologically meaningful.

In conclusion, brief occlusion of the main pancreatic duct stimulates islet neogenesis without detectable organ damage. This method can therefore be used as a model to study the early events that stimulate islet neogenesis without the presence of confounding secondary signals. This may possibly lead to the identification of new molecular targets and therapies for the treatment of diabetes.

This research was funded by the South African Medical Research Council. We would like to thank Dr Johan Louw for his assistance during the surgery.

References

1. Turner RC, Holman RR. The UK Prospective Diabetes Study. UK Prospective Diabetes Study Group. *Ann Med* 1996; 28: 439-444.
2. Matthews DR, Cull CA, Stratton IM, Holman RR, Turner RC. UKPDS 26: Sulphonylurea failure in non-insulin-dependent diabetic patients over six years. UK Prospective Diabetes Study (UKPDS) Group. *Diabet Med* 1998; 15: 297-303.
3. Levy J, Atkinson AB, Bell PM, McCance DR, Hadden DR. Beta-cell deterioration determines the onset and rate of progression of secondary dietary failure in type 2 diabetes mellitus: the 10-year follow-up of the Belfast Diet Study. *Diabet Med* 1998; 15: 290-296.
4. Kloppel G, Lohr M, Habich K, Oberholzer M, Heitz PU. Islet pathology and the pathogenesis



- of type 1 and type 2 diabetes mellitus revisited. *Survey and Synthesis of Pathology Research* 1985; **4**: 110-125.
5. Vinik A, Pittenger G, Rafaeloff R, Rosenberg L. Factors controlling pancreatic islet neogenesis. *Yale J Biol Med* 1992; **65**: 471-491.
 6. Vinik A, Rafaeloff R, Pittenger G, Rosenberg L, Duguid W. Induction of pancreatic islet neogenesis. *Horm Metab Res* 1997; **29**: 278-293.
 7. Bonner-Weir S. Perspective: Postnatal pancreatic beta cell growth. *Endocrinology* 2000; **141**: 1926-1929.
 8. Laybutt R, Hasenkamp W, Groff A, et al. Beta-cell adaptation to hyperglycemia. *Diabetes* 2001; **50**: Suppl 1, S180-S181.
 9. Steil GM, Trivedi N, Jonas JC, et al. Adaptation of beta-cell mass to substrate oversupply: enhanced function with normal gene expression. *Am J Physiol Endocrinol Metab* 2001; **280**: E788-E796.
 10. Weir GC, Laybutt DR, Kaneto H, Bonner-Weir S, Sharma A. Beta-cell adaptation and decompensation during the progression of diabetes. *Diabetes* 2001; **50**: Suppl 1, S154-S159.
 11. Brockenbrough JS, Weir GC, Bonner-Weir, S. Discordance of exocrine and endocrine growth after 90% pancreatectomy in rats. *Diabetes* 1988; **37**: 232-236.
 12. Bonner-Weir S, Baxter LA, Schupp GT, Smith FE. A second pathway for regeneration of adult exocrine and endocrine pancreas. A possible recapitulation of embryonic development. *Diabetes* 1993; **42**: 1715-1720.
 13. Boquist L, Edstrom C. Ultrastructure of pancreatic acinar and islet parenchyma in rats at various intervals after duct ligation. *Virchows Arch A Pathol Pathol Anat* 1970; **349**: 69-79.
 14. Edstrom C, Falkmer S. Qualitative and quantitative morphology of rat pancreatic islet tissue five weeks after ligation of the pancreatic ducts. *Acta Societatis Medicorum Upsaliensis* 1967; **72**: 376-390.
 15. Rosenberg L, Brown, RA, Duguid WP. A new approach to the induction of duct epithelial hyperplasia and nesidioblastosis by cellophane wrapping of the hamster pancreas. *J Surg Res* 1983; **35**: 63-72.
 16. Ferris WF, Woodroof, CW, Louw J, Wolfe-Cooto SA. Brief occlusion of the main pancreatic duct rapidly initiates signals which lead to increased duct cell proliferation in the rat. *Cell Biol Int* 2001; **25**: 113-117.
 17. Drury, RAB, Wallington EA. *Carlton's Histological Techniqu*. Oxford: Oxford University Press, 1980; 442-449.
 18. Bonner-Weir S, Baxter LA, Schupp GT, Smith FE. A second pathway for regeneration of adult exocrine and endocrine pancreas. A possible recapitulation of embryonic development. *Diabetes* 1993; **42**: 1715-1720.
 19. Wolfe-Cooto S, Louw J, Woodroof C, du Toit D. Development, differentiation, and regeneration potential of the Vervet monkey endocrine pancreas. *Microsc Res Tech* 1998; **43**: 322-331.
 20. Bouwens L, Wang RN, De Blay E, Pipeleers DG, Kloppel G. Cytokeratins as markers of ductal cell differentiation and islet neogenesis in the neonatal rat pancreas. *Diabetes* 1994; **43**: 1279-1283.
 21. Bouwens L, Lu WG, De Krijger R. Proliferation and differentiation in the human fetal endocrine pancreas. *Diabetologia* 1997; **40**: 398-404.

Accepted 12 November 2003