



## CLINICAL IMAGES

## Early visual recovery after macular hole surgery with gas tamponade

K N A Rivett, M Boocock

An artistic physicist had macular hole surgery and recorded her daily observations in colour paintings. These are presented both for their interest and their value in creating a better understanding of what to expect subjectively, for the benefit of both patient and surgeon.

Fear of the unknown and the risk of blindness compound the anxiety of eye surgery, especially in the elderly who spend much time alone. However, the frequency of anterior segment surgery such as cataract extraction and the rapid recovery of vision often achieved lessen the impact of these commonly performed operations.

Vitreoretinal surgery differs markedly from the above, as few people needing it know someone who has undergone a similar procedure. Visual recovery is much slower and is often associated with bizarre symptoms which the surgeon cannot describe adequately to the patient preoperatively. The strange subjective nature of the symptoms may also generate fear that they indicate sinister complications, causing anxiety and sleepless nights — for both patients and the surgeons they telephone!

Macular hole surgery with gas tamponade was performed on an artist, previously a professor of physics, who recorded her daily observations by means of colour paintings.

The daily sequential paintings are recorded as viewed through the operated eye (Figs 1 - 11). Loss of stereopsis, reliance on memory after each viewing, and difficulty in making accurate contact between the brush tip and the canvas influenced the detail produced.

This artist's impressions were verified by other patients undergoing macular hole surgery with gas tamponade. Agreement that the paintings represented what each of the patients observed make it likely that this is a consistent pattern of visual recovery postoperatively. The pictures record bubble breakup, but not movement or changing shapes, and the patient should be warned of this.

We hope that these pictures provide a useful guide to vitreoretinal surgeons and their staff in terms of preoperative counselling and postoperative monitoring, as well as helping to allay patient anxiety.

Illustrations are from the night of the operation to the 11th postoperative day.

36

*Dr Kelvin Rivett is head of the vitreo-retinal department at Frere Hospital, East London, and President of the South African Vitreo-retinal Society. He is in private ophthalmology practice in East London. Mrs Maureen Boocock is a retired physicist and amateur artist.*




Fig. 1. Night of operation. Vision through closed eyes. Photopsias with eye movements.



Fig. 2. Day 1. Eye closed. Photopsias with increasing brightness.

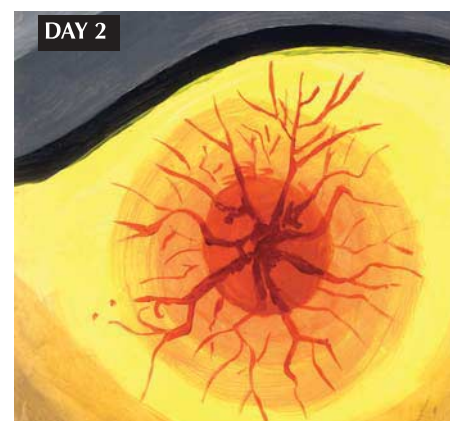

Fig. 3. Day 2. Eye open through narrow slit. Bright, central red image with radiating lines. These have no resemblance to the optic disc vascular pattern.

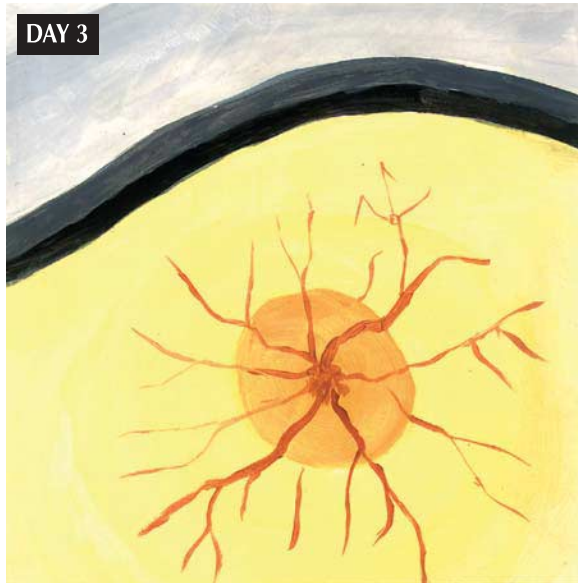

Fig. 4. Day 3. Eye open through narrow slit, similar image but less bright.




Fig. 6. Day 5. The same gown seen with more colour and form. Bars of light and dark are from window bars.



Fig. 5. Day 4. Only light visible without any form. Minimal colour. The blue images are from the dressing gown with coloured pattern.




Fig. 7. Day 6. Beginning of definition of background visible. Many spots (blood?) seen above bubble. Colour pattern in bubble is from a used painting cloth on table under easel.



DAY 7




Fig. 8. Day 7. View within bubble of paint tubes on table and finger held 15 cm away. Focus through bubble good and improving.

DAY 8




Fig. 9. Day 8. Background more defined although edges are fuzzy. The lower dull area could be observed. Great improvement is noted in background and sharp focus through bubble 15 - 20 cm away. Second bubble appeared after sudden movement.

DAY 9




Fig. 10. Day 9. View of plants against wall and tree beyond. Details of background are more accurate than through bubble although still a bit hazy. Both eyes are now able to observe objects and register similar images. Binocular single vision.

DAY 11




Fig. 11. Day 11. Sharp focus on distant similar objects and much sharper colour vision. Note: No central scotoma or metamorphopsia.