

Avian mycobacteriosis in chickens from a rural area of Argentina

Cowper Coles, P.¹; Cicuta, M.E.¹; Zumárraga, M.³;
Etchetchoury, I.³; Lértora, J.²; Ramírez, G.V.¹

¹Cátedra de Microbiología, ²Cátedra de Patología General, Facultad de Ciencias Veterinarias, UNNE, Sargento Cabral 2139, Corrientes (3400), Argentina. ³Instituto de Biotecnología (INTA Castelar, Buenos Aires). E-mail: microbiol@vet.unne.edu.ar

Abstract

Cowper Coles, P.; Cicuta, M.E.; Zumárraga, M.; Etchetchoury, I.; Lértora, J.; Ramírez, G.V.: Avian mycobacteriosis in chickens from a rural area of Argentina. *Rev. vet. 18: 2, 72–77, 2007.* An outbreak of avian tuberculosis was detected in chickens from a rural area of Chaco Province, northeastern Argentina. The hens were emaciated and presented granulomatous lesions of various sizes throughout the internal organs. The lesions observed in three necropsied birds consisted of granulomas containing alcohol/acid-fast bacilli. All the lesions found were diagnosed histopathologically as tuberculosis, *Mycobacterium avium* subsp. *avium* were isolated from the cultures and confirmed by polymerase chain reaction techniques.

Key words: chicken, rural area, *Mycobacterium avium* subsp. *avium*, polymerase chain reaction.

Resumen

Cowper Coles, P.; Cicuta, M.E.; Zumárraga, M.; Etchetchoury, I.; Lértora, J.; Ramírez, G.V.: Micobacteriosis aviar en gallinas de una zona rural de Argentina. *Rev. vet. 18: 2, 72–77, 2007.* Se describe un brote de tuberculosis aviar en gallinas criadas a campo en la provincia de Chaco, al noreste de Argentina. Las aves estaban emaciadas y en la necropsia efectuada a tres de ellas presentaron granulomas de diversos tamaños en diferentes órganos internos, conteniendo bacilos ácido-alcohol resistentes. Histopatológicamente fueron diagnosticadas como tuberculosis. Se aislaron colonias de *Mycobacterium avium* subsp. *avium* en los cultivos, confirmado por técnicas de reacción en cadena de la polimerasa.

Palabras clave: gallina, área rural, *Mycobacterium avium* subsp. *avium*, reacción en cadena de la polimerasa.

INTRODUCTION

Avian mycobacteriosis is an important disease related to all species of birds, most commonly caused by *Mycobacterium avium* subsp. *avium*¹¹. All bird species can be infected, but classic tubercles rarely develop in *Columbiformes*, *Anseriformes*, *Psittaciformes*, and *Passeriformes*⁶. Among mammalian species such as swine, rabbits, and mink, *M. avium* infection can cause progressive disease¹⁹ and is also responsible for tuberculosis in humans¹¹. Mycobacteriosis is a chronic, generalized, granulomatous infectious disease that affects various organs. Lesions are most frequently seen in the liver, spleen, intestine, and bone marrow¹¹ and infrequently in the lungs, ovary, oviduct and testes^{19,21}. Molecular techniques have been shown to be more suitable for use in the epidemiologic study of *M. avium* complex (MAC) infections, for these reasons, several insertion sequences have been identified for the

detection of *M. avium* subsp. *avium*, such as IS901/902, IS110, IS1141, IS1245, IS1311, and IS1613. IS1245 is often used to identify MAC strains².

Mycobacterium avium infection is quite frequent in zoo animals and wild birds in Spain^{21,26} and other countries around the world^{7,22,27,33} but is less frequently described in commercial flocks^{1,23,33}. At present, the incidence of avian tuberculosis in commercial birds in Spain is very low; however, some years ago, these birds were considered a source of infection for swine and cattle. Nevertheless, tuberculosis caused by *M. avium* is much more frequent today within the swine population than in commercially reared birds¹⁴.

Mycobacterium avium subsp. *avium*, is a saprophytic aerobic bacterium capable of causing disease in wild and domestic birds, as well as mammals, including humans. Transmission of the bacteria in wild birds most likely occurs via ingestion of soil and litter contaminated with fecal material or carcasses of infected birds or by aerosols^{18,32,35}. Clinically, often manifests in domestic birds as a chronic progressive disease.

M. avium has been isolated from a number of domestic and wild avian species, including chicken and domestic turkey, captive ring-necked pheasant (*Phasianus colchicus*), sandhill crane (*Grus canadensis*), whooping crane (*G. americana*), bald eagle (*Haliaeetus leucocephalus*), red-tailed hawk (*Buteo jamaicensis*), mallard (*Anas platyrhynchos*), gadwall (*A. strepera*), redhead (*Aythya ferina*), lesser flamingo (*Phoeniconaias minor*), Canada goose (*Branta canadensis*), mute swan (*Cygnus olor*), tundra swan (*C. buccinator*), and European starling (*Sturnus vulgaris*)^{4, 25, 29, 32, 35}.

During a 10-year study in the Netherlands, *M. avium* subsp. *avium* was isolated from 0.7% of dead wild birds, with the prevalence of *M. avium* subsp. *avium* being the highest among scavengers and raptors³⁰. Transmission between domestic and wild birds is likely, and the disease has been seen more frequently in wild birds that are found near poultry farms^{32, 35}.

Tuberculosis lesions can be found throughout the avian body, with the liver, spleen, intestines, and bone marrow most frequently affected; gross lesions consist of irregular grayish-yellow or grayish-white masses, which are firm but easily incised^{18, 32}. *M. avium* also was isolated from several waterfowl with polycystic livers and no granulomas²⁵. It was described an atypical form of avian tuberculosis (ATB) in waterfowl with discrete tubercles that were not evident grossly, and histologically the parenchyma of the liver and spleen was replaced with pale amorphous material³⁵. The typical lesions of ATB in psittacine birds do not contain the classic tubercle but instead are seen as an accumulation of macrophages containing acid-fast bacilli that are scattered throughout the parenchyma²⁸. There was a report describing an hepatic case of ATB in a wild turkey (*Meleagris gallopavo*) from Kansas¹³. We have also isolated (personal communication) one strain of *M. avium* from a turkey hen (*Meleagris gallopavo*) which had been at the local zoo for months when it presented clinical signs.

PCR-restriction analysis (PRA), which relies on the amplification of a 441-bp portion of the *hsp65* gene (heat shock protein) present in all mycobacteria, followed by restriction with *Bst*EII and *Hae*III of the PCR product, offers a rapid and easy alternative that permits the rapid identification of mycobacteria without the need of specialized equipment^{10, 20, 31}. This gene presents different cutting sites owing its polymorphism, so variable restriction fragments are obtained. The electrophoresis of these fragments in an agarose gel generate typical patterns characteristic of the avium species.

The present report describes mycobacteriosis in a flock of domestic chickens in which *M. avium* was identified by PRA.

MATERIAL AND METHODS

The owner of the flock, which had not experienced previous diseases but exhibited poor biosecurity conditions, noted that various chickens of a total of 20, became emaciated and sick. Three dead hens were

necropsied and laboratory examinations performed. Laboratory investigation included cytology of stained smears from affected tissues as well as bacteriologic, histopathologic, and polymerase chain reaction (PCR) examination.

Necropsy examination. The three dead hens necropsied had cachexia with general muscular atrophy. Multiple white-yellow granulomatous nodular lesions, ranging in size from pinhead to 10 mm, were randomly distributed throughout their livers, spleens, lungs, crop, proventriculus and all the intestine tract. Tissues were taken for mycobacterial cultures and were fixed in 10% neutral formalin for histopathologic examination. Smears were made from the lesions of the lungs, liver, spleen and intestine, and stained with the Ziehl-Neelsen (ZN) technique.

Bacteriologic examination. The granulomas were bacteriologically processed for mycobacteria isolation. Petroff decontamination technique using sodium hydroxide (4%) was performed, following by neutralization, centrifugation, and 0.2 ml of the sediment was inoculated in each of four tubes of Stonebrink and two tubes of Löwenstein-Jensen medium.

Histopathologic examination. The samples obtained from the necropsies were fixed in 10% neutral formalin and routinely processed in the histopathology laboratory. The hematoxylin and eosin (H&E) and Ziehl-Neelsen staining methods were employed.

DNA extraction. A loopful of colonies were resuspended in 200 ml of water and were boiled for 30 min. After 10 min of centrifugation at 12,000 rpm, 5 µl of the supernatant were used as template for the PCR.

PCR-Restriction Enzyme Analysis (PRA). The protocol were performed as described by Leao *et al.*, 2005²⁰ with some modifications. Reaction mixing: The amplification of a 441 bp fragment of *hsp65* was performed in a final volume of 50 µl containing buffer (Tris-HCl 10 mM, pH 9.0; KCl 50 mM and Triton X-100 0.1%), 1.5 mM MgCl₂, 0.2 mM of each dNTP, 25 pmols of each TB11(ACCAACGATGGTGTGTCCAT) and TB12 (CTTGTCGAACCGCATAACCCT) primers, 5 µl template and 1.25 U of Taq polymerase (Go Taq Promega Corp)³¹. The PCR reaction consisted of an initial cycle at 95°C for 3 min, following by 45 cycles at 95°C for 1 min, 60°C for 1 min, and 72 °C for 1 min, and a final extension step at 72°C for 7 min. To check the amplification, 5 µl of the reaction was analysed in 1% agarose gel using 1x TBE buffer.

Twenty microliters of the amplification product was subjected to restriction with *Bst*EII and *Hae*III. The fragments obtained were separated by electrophoresis on a 3% agarose in 1x TBE buffer stained with ethidium bromide and visualized under UV. A 50 bp DNA Ladder (Promega Corp.) was used as a molecular weight marker.

Through a particular table, where different size restriction fragments are generated with each enzyme, it is possible to classified to species level^{8-10, 31}. Although all *Mycobacteria* of the *tuberculosis complex* have the

same restriction pattern, some variants have been described⁸ also in the same species of *M. scrofulaceum*, *M. intracellulare*, *M. flavescens*, *M. fortuitum*, *M. gordonae*, *M. terrae* and *M. avium complex*⁹.

RESULTS AND DISCUSSION

Macroscopic lesions. The necropsies revealed in two birds advanced state of cachexia with evident muscular atrophy, above all in breast muscles. In these hens, numerous yellowish, firm, nodular formations between 1 mm and 2 cm in diameter were observed in spleen and liver (Figures 1 and 2). Multiple nodules and ulcers involved mucous of the crops and proventriculus, and all layer of small and large intestines (Figures 3 and 4). Few granulomas were seen in lungs. The ovaries were functional so the hens were theoretically in production. The remaining bird displayed good body condition, and its ovary appeared to be active. This hen also exhibited nodular formations in viscera, especially in the intestine, but the size and extension of the lesions were moderate compared with those of the former group (Figure 5). Large numbers of short, rod-shaped, acid-fast bacilli (AFB) were present with the ZN stain from smears of the lesions in the three chickens (Figure 6).

Histopathologic results. The histological findings were those typical of avian tuberculous granulomas and were seen in lungs, liver, spleen, crop, proventriculus, duodenum, jejunum, ileum, cecal tonsils, cecum and mesentery. Small and large intestines, liver and spleen were the organs with more extensive and severe lesions (Figures 7 and 8). The granulomatous lesions varied from small cluster of unencapsulated macrophages with foamy cytoplasm; until large necrotic centers surrounded with giant cells, epithelioid cells, macrophages and a outer fibrous capsule containing some

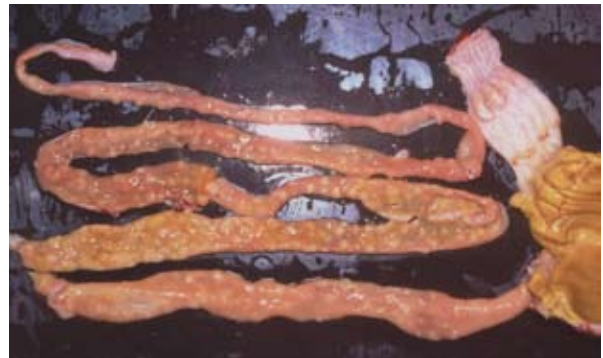

Figure 3. Ventriculus, proventriculus and small intestine. Mucous of proventriculus enlarge with nodules and intestines with multiples nodules and ulcers.

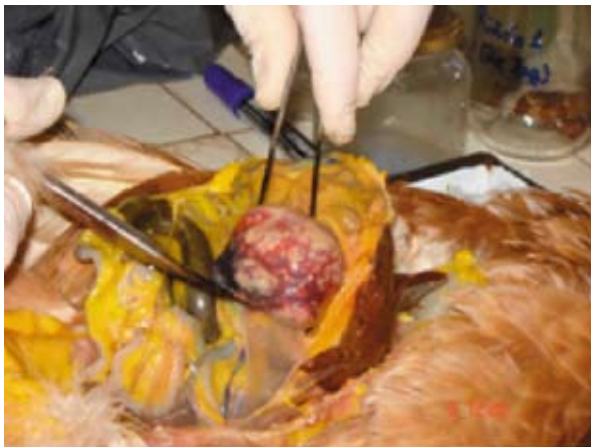


Figure 1. Spleen. Splenomegaly and multifocal nodular granulomatous lesions.

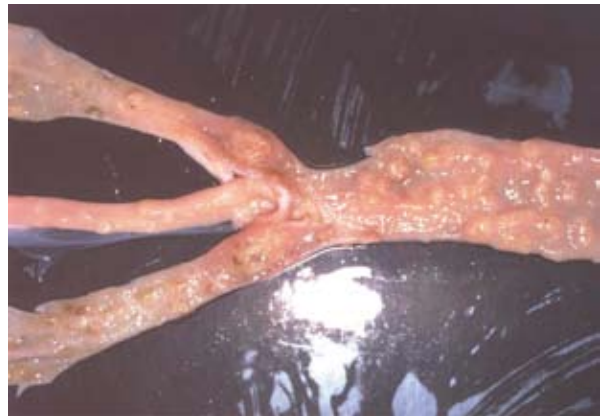

Figure 4. Ileum, cecum and rectum. Multiple nodules and ulcers granulomas in ileum, cecum and rectum. Note cecal tonsil enlarged.

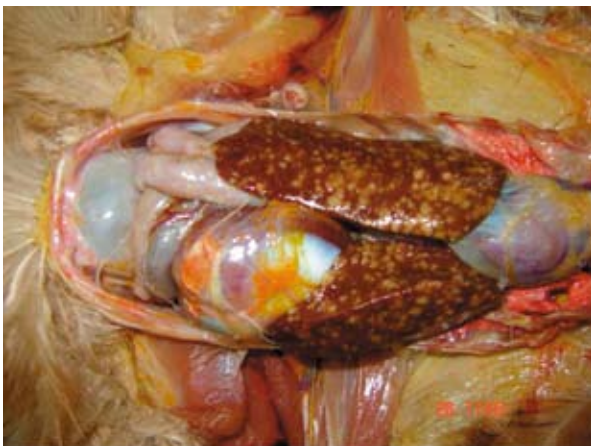


Figure 2. Liver. Multifocal granulomatous hepatitis.

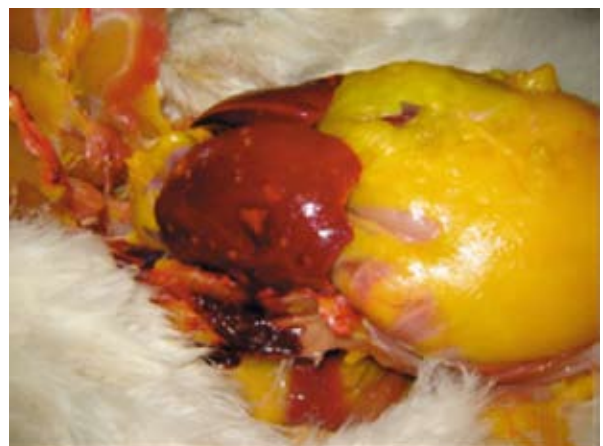


Figure 5. Liver of other hen showing granulomatous foci.

mononuclear cells. The ZN stain revealed numerous acid/alcohol-fast bacilli into the giant cells, macrophages, epithelioid cells and the necrotic tissue.

Bacteriological results. Abundant AFB were observed in all organs stained by ZN. Non-pigmented

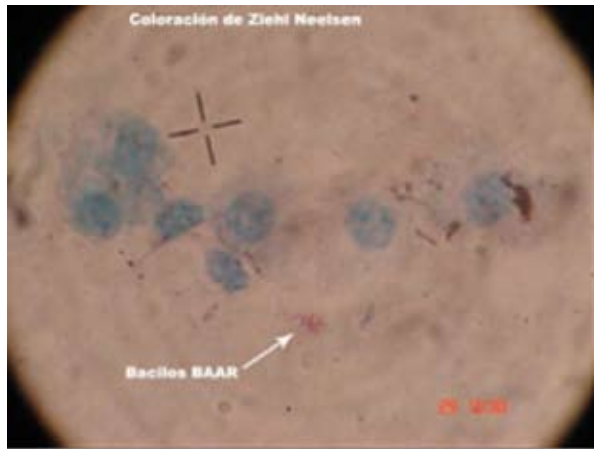

Figure 6. Smear of liver lesions. ZN stain with acid-fast bacilli (AFB or BAAR), 1000x.

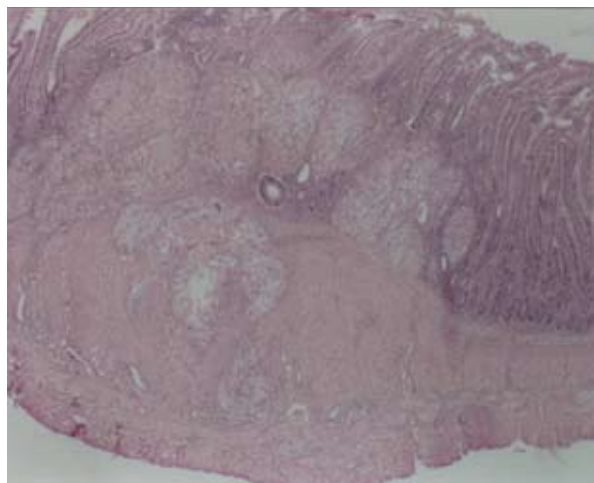


Figure 7. Multiple granulomas involved mucous and muscular of jejunum (H&E, 4x).

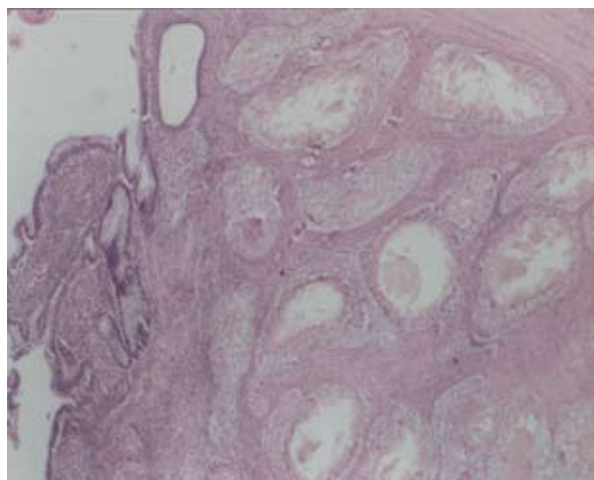


Figure 8. Granulomas involved mucous, submucous and muscular of cecum (H&E, 4x).

colonies grew in all culture media (Löwenstein-Jensen and Stonebrink) after thirty days of incubation at 37°C.

PRA results. The patterns of the three samples analyzed (Figure 9) were identical each other and coincident with those of MAC observed in the international bibliography^{8,9,10} that are characterized by the uniform obtaining of two fragments of 245 and 220 bp with the digestion with *Bst*EII and two fragments of 140 and 105 bp with the digestion with *Hae*III that agree with the published sequences of the antigen of 65-kDa.

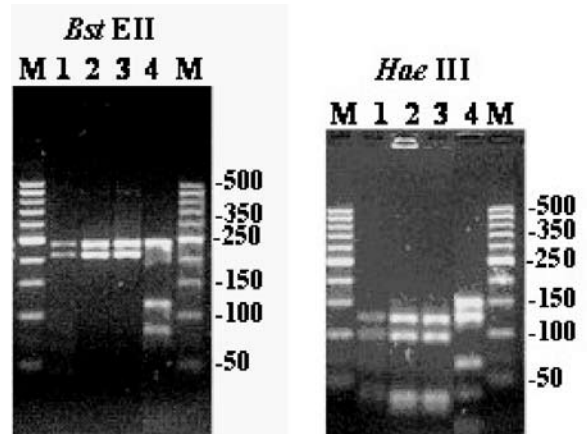


Figure 9. PRA gel after digestion with *Bst*EII of 245-220 bp and *Hae*III of 140-105 bp. Lanes 1-2-3 DNA fragments amplified from *Mycobacterium avium* of chickens. Lane 4 *M. tuberculosis* complex *Bst*EII of 245-120-80 bp and *Hae*III of 160-140-70 bp. M molecular weight marker of 50 bp.

M. avium infection is relatively frequent in zoo and wild birds but is rarely seen in commercial poultry flocks¹⁴. Several decades ago, outbreaks of tuberculosis in industrial poultry operations were described and were associated, above all, with faulty sanitary conditions. Because the biosecurity conditions of the poultry farm were inadequate, it appears unlikely that the hens could have been infected by wild birds. Another point to consider is that the infected animals continued to produce and, as demonstrated years ago, *M. avium* may be present in eggs laid by infected birds^{5,12}.

The significance of this contamination may have, in health terms, makes it necessary to reconsider this disease in poultry. The appearance of clinical signs such as emaciation, muscular atrophy, and disappearance of the subcutaneous and intracavitary fat deposits are frequent findings in birds with *M. avium* infection²² as has occurred in these animals. The lesions observed in the liver, spleen, and various sections of the intestine led to conclude that the portal of entry of the microorganism was digestive. These locations coincide with data reported by other authors in both domestic fowl and wild birds^{3,7,21,22}.

Dissemination of *M. avium* from the intestine may affect the liver and spleen, as the same authors have likewise reported^{7,22}. Granulomas are not observed as

frequently in the pulmonary parenchyma as we could see, although their presence has been reported in non-domestic birds²⁶. Avian tuberculosis most frequently affects adult birds, both commercial and wild, because the incubation period of *M. avium* is lengthy. This is the reason why the infection is infrequent in commercial layer hens because these animals are slaughtered very young (2 yr of age at the most) and also because of the adequate management practices and appropriate biosecurity measures that are generally applied currently in avian operations^{23,24}.

The localization of lesions is probably correlated with the infection route. *Mycobacterium avium*, *M. genavense*, and mycobacteria other than tuberculous mycobacteria are transmitted mainly by oral ingestion, with primary localization in intestinal tract, liver, and spleen¹⁶. The pathogenesis seems to be linked to the main sources, most mycobacteria are environmental saprophytes (soil, water), and therefore are “digested”.

Isolation of *M. avium* associated with lesions and clinical disease has been reported from poultry, domestic turkeys, and captive ringnecked pheasants^{29,32}. *M. avium* is ubiquitous and generally affects immunosuppressed individuals of most avian and mammalian species, including humans¹⁷.

Avian mycobacteriosis is endemic worldwide, especially in wild birds and zoo aviaries, but is rarely seen in domestic birds¹⁴ and must be considered a risk for humans with immunodeficiency¹¹. Diagnosis of mycobacteriosis can be made by detecting the acid-fast bacilli in stained smears of infected organs or by mycobacterial DNA or RNA probes of biopsy specimens^{11,34}. In this work we could differentiate *M. avium complex* from other mycobacteria by PRA method technique. The advantage is the use of only a pair of primers and a pair of restriction enzymes to identify several mycobacteria. Moreover this is an useful method to differentiate non-tuberculous or atypical mycobacteria from the tuberculous complex.

Mycobacteriosis appears to be less prevalent in young birds because in older ones the disease has a greater opportunity to become established through a longer period of exposure^{14,15,34}. As happened in this case, affected hens were adults over 2 years of age. The appearance of cachexia and muscular atrophy are frequent in birds with *M. avium* infection^{22,24}. *Mycobacterium avium* is environmentally and chemically resistant and can survive in soil and water for up to 4 years³⁴. Because the biosecurity of this flock was inadequate, perhaps they had been infected by these wild birds.

In conclusion, owing to the atypical symptoms that we found in this case, more attention should be given to mycobacteriosis in domestic hens, and the biosecurity of these flocks must be improved. Delays in diagnosis increase the risks to breeders, children, and immunocompromised humans. The results obtained in this study indicate that we are faced with the reappearance of a disease with serious human health repercussions and that epidemiologic studies are required to clarify its origin.

REFERENCES

1. Barbour EK, Hamadeh SK, Hilan C, Kallas M, Eid A, Sakr W. 1997. National surveillance of poultry diseases in Lebanon. *Rev Sci Tech Off Int Epizoot* 16: 770-775.
2. Bauer J, Andersen AB. 1999. Stability of insertion sequence IS1245, a marker for differentiation of *Mycobacterium avium* strains. *J Clin Microbiol* 37: 442-444.
3. Bertelsen MF, Grøndahl C, Giese SB. 2006. Disseminated *Mycobacterium celatum* infection in a whitetailed trogon (*Trogon viridis*). *Avian Pathol* 35: 316-319.
4. Bickford AA, Ellis GH, Moses HE. 1966. Epizootiology of tuberculosis in starlings. *J Am Vet Med Assoc* 149: 312-318.
5. Bojarski J. 1968. Occurrence of *Mycobacterium* in eggs of tuberculin-positive hens. *Med Weter* 24: 21-23.
6. Bougiouklis P, Brellou G, Fragkiadaki E, Iordanidis P, Vlemmas I, Georgopoulou I. 2005. Outbreak of avian mycobacteriosis in a flock of two-year-old domestic pigeons (*Columba livia f. domestica*). *Avian Dis* 49: 442-445.
7. Bowes V. 1993. Avian tuberculosis in ostriches. *Can Vet J* 34: 758.
8. da Silva Rocha A, da Costa Leite C, Magarinos Torres H, de Miranda AB, Quinhones Pires Lopes M, Maurits Degrave W, Suffys PN. 1999. Use of PCR-restriction fragment length polymorphism analysis of the *hsp65* gene for rapid identification of mycobacteria in Brazil. *J Microbiol Method* 37: 223-229.
9. Da Silva Rocha A, Werneck Barreto AM, Dias Campos CE, Villas-Bôas da Silva M, Fonseca L, Saad MH, Degrave WM, Suffys PN. 2002. Novel allelic variants of mycobacteria isolated in Brazil as determined by PCR-restriction enzyme analysis of *hsp65*. *J Clin Microbiol* 40: 4191-4196.
10. Devallois A, Goh KS, Rastogi N. 1997. Rapid identification of mycobacteria to species level by PCR-restriction fragment length polymorphism analysis of the *hsp65* gene and proposition of an algorithm to differentiate 34 mycobacterial species. *J Clin Microbiol* 35: 2969-2973.
11. Fulton RM, Thoen CO. 2003. Tuberculosis. In: *Diseases of Poultry* (Said Y ed.), 11th ed., Iowa State University Press, Ames, p. 836-844.
12. Fritzsche K, Allam MS. 1965. The contamination of hen eggs with mycobacteria. *Arch Lebensmittelhyg* 16: 248-250.
13. Gerhold RW, Fischer JR. 2005. Avian tuberculosis in a wild turkey. *Avian Dis* 49: 164-166.
14. Gonzalez M, Rodriguez-Bertos A, Gimeno I, Flores J, Pizarro M. 2002. Outbreak of avian tuberculosis in 48-week-old commercial layer hen flock. *Avian Dis* 46: 1055-1061.
15. Hoop RK, Böttger EC, Pfyffer GE. 1996. Etiological agents of mycobacteriosis in pet birds between 1986 and 1995. *J Clin Microbiol* 34: 991-992.
16. Hoop RK. 2002. *Mycobacterium tuberculosis* infection in a canary (*Serinus canaria* l.) and a blue-fronted amazon parrot (*Amazona amazona aestiva*). *Avian Dis* 46: 502-504.

17. **Horsburg CR.** 1991. *Mycobacterium avium* complex infection in the acquired immunodeficiency syndrome. *N Engl J Med* 324: 1332-1338.
18. **Jordan FT.** 1996. Avian tuberculosis. In: *Poultry Diseases* (Jordan FT, Pattison M ed), 4th ed., Saunders, London, p. 76-80.
19. **Jordan FT, Pattison M, Alexander D, Faracher T.** 2001. *Mycobacterium tuberculosis*. In: *Poultry Diseases* (Jordan FT, Pattison M ed), 5th ed., Saunders, London, p. 213-217.
20. **Leao SC, Bernardelli A, Cataldi A, Zumárraga M, Robledo J, Realpe T, Mejia GI, da Silva Telles MA, Chimara E, Velazco M, Fernández J, Rodríguez PA, Guerrero MI, León CI, Porras TB, Rastogi N, Goh KS, Suffys P, da Silva Rocha A, dos Santos Netto D, Ritacco V, López B, Barrera L, Palomino JC, Martin A, Portals F.** 2005. Multicenter evaluation of mycobacteria identification by PCR restriction enzyme analysis in laboratories from Latin America and the Caribbean. *J Microbiol Method* 61: 193-199.
21. **Marco I, Domin M, Lavin S.** 2000. *Mycobacterium* infection in a captive-reared capercaillie (*Tetrao urogallus*). *Avian Dis* 44: 227-230.
22. **Montali RJ, Bush M, Thoen CO, Smith E.** 1976. Tuberculosis in captive exotic birds. *J Am Vet Med Assoc* 169: 920-927.
23. **Mutalib AA, Riddell C.** 1988. Epizootiology and pathology of avian tuberculosis in chickens in Saskatchewan. *Can Vet J* 29: 840-842.
24. **Porter RE.** 1998. Bacterial enteritides of poultry. *Poult Sci* 77: 1159-1165.
25. **Roffe TJ.** 1989. Isolation of *Mycobacterium avium* from waterfowl with polycystic livers. *Avian Dis* 33: 195-198.
26. **Sallés JC, Fernández J, Domingo M, Adúriz G.** 1996. Tuberculosis aviar en aves no domésticas. *Med Vet* 13: 135-151.
27. **Sandford SE, Rehmtulla AJ, Josephson GK.** 1994. Tuberculosis in farmed rheas (*Rhea americana*). *Avian Dis* 38: 193-196.
28. **Schmidt RE, Reavill DN.** 2003. Phalen Liver Diseases. In: *Pathology of Pet and Aviary Birds* (Clark BW ed.), Iowa State University Press, Ames, p. 76-77.
29. **Singbeil BA, Bickford AA, Stoltz JH.** 1993. Isolation of *Mycobacterium avium* from ringneck pheasants (*Phasianus colchicus*). *Avian Dis* 37: 612-615.
30. **Smit T, Eger A, Haagsma J, Bakhuizen T.** 1987. Avian tuberculosis in wild birds in the Netherlands. *J Wildl Dis* 23: 485-487.
31. **Telenti A, Marchesi F, Balz M, Bally F, Bottger EC, Bodmer T.** 1993. Rapid identification of mycobacteria to the species level by polymerase chain reaction and restriction enzyme analysis. *J Clin Microbiol* 31: 175-178.
32. **Thoen CO.** 1997. Tuberculosis. In: *Diseases of Poultry* (Clark BW ed.), 10th ed., Iowa State University Press, Ames, p. 167-178.
33. **Thorel MF, Huchzermeyer H, Weiss R, Fontaine JJ.** 1997. *Mycobacterium avium* infections in animals. Literature review. *Vet Res* 28: 439-447.
34. **Van Der Heyden N.** 1997. Clinical manifestations of mycobacteriosis in pet birds. *Semin Exotic Pet Med* 6: 18-24.
35. **Wobeser GA.** 1997. Tuberculosis. In: *Diseases of Waterfowl* (Wobeser GA ed.), 2nd ed., Plenum Press, New York, p. 71-75.