

## СЛУЧАЙ ИЗ ПРАКТИКИ CASE STUDY

### A CASE STUDY OF COMBINED CORONARY ARTERY BYPASS GRAFTING AND TRICUSPID VALVE REPLACEMENT 25 YEARS AFTER HEART TRANSPLANTATION

HUSAYN LADHANI<sup>1</sup>, HARVEEN LAMBA<sup>2</sup>, YAKOV ELGUDIN<sup>2</sup>

<sup>1</sup> *University Hospitals Case Medical Center, Cleveland, Ohio*

<sup>2</sup> *Louis Stokes Veterans Affairs Medical Center, Cleveland, Ohio*

**Aim.** Coronary artery bypass grafting (CABG) and tricuspid valve replacement (TVR) are available therapeutic options for cardiac allograft vasculopathy (CAV) and tricuspid regurgitation (TR), respectively after orthotopic heart transplantation (OHT). To our knowledge, these two procedures have never been reported simultaneously in a heart transplant recipient in the literature.

**Materials and methods.** We present the first incidence of a simultaneous CABG and TVR with a Biocor™ bioprosthetic valve in a heart transplant recipient 25 years after the original transplant operation, the longest reported duration before reoperation after OHT.

**Results.** Early postoperative course was complicated by complete heart block requiring placement of dual chamber pacemaker. Patient progressed well after this intervention and was eventually discharged to home and remained asymptomatic on follow-up.

**Conclusion.** Concomitant CABG and TVR for severe TR is a safe and effective treatment option with low perioperative mortality and favorable short and long term outcomes in heart transplant recipients.

**Key words:** heart transplantation, tricuspid valve insufficiency, vascular disease, reoperation.

We present a patient who successfully underwent coronary artery bypass grafting (CABG) and tricuspid valve replacement (TVR) 25 years after orthotopic heart transplantation (OHT). To our knowledge, this is the longest period of time since OHT for a patient to undergo both procedures concomitantly.

A 67 year old male who underwent OHT 25 years ago for ischemic cardiomyopathy, with last endomyocardial biopsy 20 years ago and no prior prophylactic tricuspid valve annuloplasty, presented with worsening generalized fatigue, dyspnea on exertion, and palpitations. Electrocardiogram showed new atrial fibrillation with controlled ventricular response. Echocardiogram showed left ventricular ejection fraction of 50–55 %, moderately reduced right ventricular function, and severe tricuspid regurgitation with a flail anterior leaflet. Coronary angiogram showed subtotal distal left main stenosis with moderate circumflex stenosis. Patient was taken to the operating room for a combined CABG and TVR. He was placed on cardiopulmonary bypass (CPB) using axillary – femoral cannulation and a redo median sternotomy was performed. Left internal thoracic artery and saphenous vein were used to bypass the LAD and OM, respectively. Tricuspid valve was accessed via right atriotomy and replaced with a 33-mm Biocor™ bioprosthetic valve (St.Jude Medical Inc.). He was successfully weaned off CPB in normal sinus rhythm.

Post-operative course was complicated by development of complete heart block on post-operative

day (POD) 3 that required placement of a permanent pacemaker. He progressed well and was discharged home on POD 17. Upon follow up, on POD 31, he had good energy and no complaints of dyspnea.

#### Discussion

Due to advances in immunosuppression therapy, long-term survival after OHT remains excellent, with 10- and 20-year survival rates reported to be 64 % and 56 %, respectively [1]. CAV, with an incidence of more than 50 % by 10 years [2], accounts for major long-term morbidity and mortality among heart transplant recipients. It represents a constellation of vascular changes characterized by fibromuscular intimal hyperplasia, atherosclerosis, vasculitis, or any combination of the three. The most common type of lesion is fibromuscular intimal hyperplasia, which tends to be circumferential and involves large and small epicardial coronary arteries, as well as intramyocardial branches. Atherosclerosis, by contrast, tends to be eccentric and generally occurs proximally, sparing the intramyocardial arteries. Evidence for atherosclerosis as a manifestation of CAV comes from the fact that the pediatric heart transplant recipients have also been found to have atheromas [3]. In adults with longer graft survival there may be both focal atherosclerotic disease as well as diffuse fibromuscular intimal hyperplasia [4], and this was the likely manifestation of CAV in this patient.

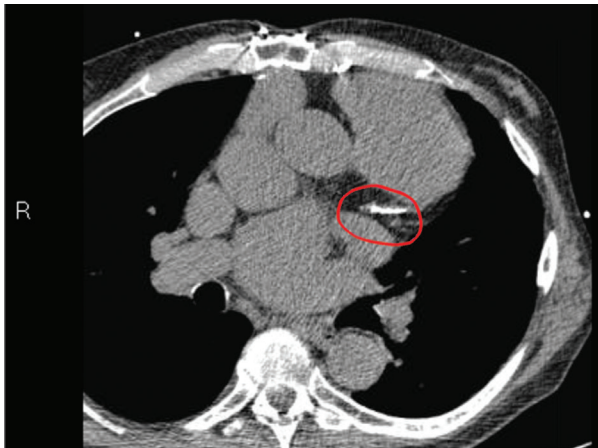


Figure 2. Non-contrast CT Angiography showing calcification and stenosis of Left Anterior Descending (LAD) artery

Between 2 to 5.8 % of heart transplant recipients develop severe tricuspid regurgitation that is symptomatic and refractory to medical management. It is most commonly secondary to flail leaflets from chordal damage sustained during endomyocardial biopsies [5], and the mean time from heart transplantation to diagnosis of severe TR has been reported to be 43 months [6]. This patient first developed severe TR from a flail leaflet 25 years after transplantation and 20 years from last endomyocardial biopsy, a first in current literature. CAV and valvular disease, especially tricuspid regurgitation (TR) due to repeated endomyocardial biopsies, contribute in large part to late morbidity after OHT. CABG and TVR are available therapeutic options[7] but there is very little data in current literature regarding operative intervention more than 10 years after OHT. There is even less data regarding combined CABG and TVR.

Bhama et. al reported a series of 13 patients who underwent CABG 12.3 +/- 6.3 years after OHT with no perioperative mortality and a 92 % 1-year survival rate [8]. Raghavan et. al prospectively reviewed 9 patients who underwent TVR 12 +/- 3.2 years after OHT and reported only one death over a period of 6 months [9]. Goerler et. al reported a series of 44 patients who underwent 19 CABGs 9.0 +/- 5.5 years after OHT, and 20 tricuspid valve procedures 8.6 +/- 4.2 years after OHT. Early mortality in this series was 4.5 %

and 1-year survival was reported to be 84 %. Two patients in this series underwent concomitant CABG and tricuspid valve procedures [2]. Musci et. al reported one case of a patient who underwent CABG and TVR 10.7 years after OHT with no perioperative or short-term mortality [10].

Our patient underwent combined CABG and TVR 25 years after OHT, a much longer interval than what has previously been reported. We have shown this procedure can be safely performed with good perioperative outcome.

#### REFERENCES

1. Biefer H. R. C., Sundermann S. H., Emmert M. Y., Enseleit F., Seifert B. et al. Surviving 20 years after heart transplantation: a success story. *Annals of Thoracic Surgery* 2014; 97: 499–505.
2. Cale R., Rebocho M. J., Aguilar C. et al. Diagnosis, prevention and treatment of cardiac allograft vasculopathy. *Portuguese Journal of Cardiology*. 2012; 31 (11): 721–730.
3. Lu W., Palatnik K., Fishbein G. A. et al. Diverse morphologic manifestations of cardiac allograft vasculopathy: A pathologic study of 64 allograft hearts. *Journal of Heart and Lung Transplantation*. 2011; 30: 1044–1050.
4. Kass M., Haddad H. Cardiac allograft vasculopathy: pathology, prevention, and treatment. *Current Opinion in Cardiology*. 2006; 21: 132–137.
5. Badiwala M. V., Rao V. Tricuspid valve replacement after cardiac transplantation. *Current Opinion in Cardiology*. 2007; 22: 123–127.
6. Chan M. C., Giannetti N., Kato T. et al. Severe tricuspid regurgitation after heart transplantation. *Journal of Heart and Lung Transplantation*. 2001; 20 (7): 709–717.
7. Goerler H., Simon A., Warnecke G., Meyer A. L., Kuehn C. et al. Cardiac surgery late after heart transplantation: a safe and effective treatment option. *Journal of Thoracic and Cardiovascular Surgery*. 2010; 140: 433–439.
8. Bhama J. K., Nguyen D. Q., Scolieri S., Teuteberg J. J., Toyoda Y. et al. Surgical revascularization for cardiac allograft vasculopathy: is it still an option? *Journal of Thoracic and Cardiovascular Surgery*. 2009; 137: 1488–1492.
9. Raghavan R., Cecere R., Cantarovich M., Giannetti N. Tricuspid valve replacement after cardiac transplantation. *Clinical Transplantation*. 2006; 20 (6): 673–676.
10. Musci M., Pasic M., Meyer R., Loebe M., Wellnhofer ?. et al. Coronary artery bypass grafting after orthotopic heart transplantation. *European Journal of Cardio-thoracic Surgery*. 1999; 16: 163–168.

Статья поступила 26.10.2015

For correspondence:

**Lamba Harveen K**

Address: 10701 E. Blvd, Cleveland, OH 44106

Tel. (202) 316-2146

E-mail: hkl12@case.edu