

Himmelfarb Health Sciences Library, The George Washington University Health Sciences Research Commons

Pathology Faculty Publications

Pathology

7-2014

Metastatic renal cell carcinoma to the thyroid 23 years after nephrectomy

Carrie Valdez

George Washington University

M. Katayoon Rezaei

George Washington University

Frederick Hendricks

George Washington University

Stanley M. Knoll

George Washington University


Follow this and additional works at: http://hsrc.himmelfarb.gwu.edu/smhs_path_facpubs

 Part of the [Pathology Commons](#)

Recommended Citation

Valdez, C., Rezaei, M.K., Hendricks, F., Knoll, S.M. (2014). Metastatic renal cell carcinoma to the thyroid 23 years after nephrectomy. *Urology Case Reports*, 2(4), 129-130.

This Journal Article is brought to you for free and open access by the Pathology at Health Sciences Research Commons. It has been accepted for inclusion in Pathology Faculty Publications by an authorized administrator of Health Sciences Research Commons. For more information, please contact hsrc@gwu.edu.



Oncology

Metastatic Renal Cell Carcinoma to the Thyroid 23 Years After Nephrectomy[☆]Carrie Valdez^{a,*}, M. Katayoon Rezaei^b, Fredrick Hendricks^c, Stanley M. Knoll^a^a Department of Surgery, George Washington University, Washington, DC, USA^b Department of Pathology, George Washington University, Washington, DC, USA^c Department of Urology, George Washington University, Washington, DC, USA

ARTICLE INFO

Article history:

Received 5 April 2014

Accepted 14 April 2014

Keywords:

Thyroid

Renal cell carcinoma

Metastatic

Fine needle aspiration

ABSTRACT

Thyroid carcinoma is an uncommon form of human cancer, with an outstanding overall cure rate. This excellent prognosis is based on the fact that well over 99% of thyroid cancers are primary tumors. Metastatic cancer to the thyroid remains very rare. We report a case of clear cell renal carcinoma metastatic to the thyroid gland 23 years after nephrectomy.

© 2014 The Authors. Published by Elsevier Inc. All rights reserved.

Introduction

We review a unique case of metastatic renal cell carcinoma to the thyroid 23 years after nephrectomy. The discussion will include a review metastatic renal cell carcinoma.

Case presentation

Our patient is a 78-year-old woman with a left thyroid nodule. She is asymptomatic, euthyroid, and has no history of thyroid disease. Her only surgical history was a right nephrectomy 23 years ago, for a clear cell carcinoma, 4.6 cm in size, low grade (Fuhrman I), and without vascular, lymphatic, or capsular invasion.

The patient's medical and family histories are negative. On physical examination, neck examination revealed a 4.5-cm, soft, well-circumscribed nodule replacing the left lobe of the thyroid. There was no lymphadenopathy. Ultrasonographic examination showed 4.4-cm and 0.7-cm nodules in the left thyroid lobe and two 1.6-cm nodules in the right thyroid lobe.

Fine needle aspiration was performed. Although the cellularity and monomorphic cell population were consistent with a neoplastic process, the characteristic features of primary thyroid

neoplasm were lacking. The constellation of cytologic features was in favor of metastatic renal cell carcinoma. The lesional cells were focally positive for renal cell carcinoma (RCC) and negative for thyroid transcription factor-1 (TTF-1) immunostains.

Once the clinical diagnosis of late metastatic RCC was established by cytopathology, the patient underwent total thyroidectomy. The left lobe was markedly enlarged and replaced by the nodule, with an intact capsule. The right lobe was normal in size with multiple small nodules. The thyroid was not adherent to any surrounding structures, and there was no lymphadenopathy.

Gross pathologic examination of the specimen revealed a markedly enlarged left lobe. Cut section revealed an extensively hemorrhagic mass with golden-orange speckles of friable tissue, akin to the conventional clear cell RCC seen in nephrectomy specimens (Fig. 1). Histologic examination showed a well-defined distinction between the tumor cells and the adjacent thyroid gland. The tumor showed nests of clear cells separated by a rich capillary network, which is the classic architecture and cellular morphology of clear cell RCC (Fig. 2). A more extensive panel of immunostains appropriately highlighted the renal origin of the tumor cells by strong positivity for RCC (Fig. 3) and CD10 as well as negativity for TTF-1, a pattern in sharp contrast with the neighboring thyroid parenchyma.

Discussion

Thyroid nodules are quite common, occurring in up to 50% of the population, as indicated by ultrasonography. Only about 5% of these

[☆] This is an open access article under the CC BY-NC-ND license (<http://creativecommons.org/licenses/by-nc-nd/3.0/>).

* Corresponding author. Tel.: +1-2483905864.

E-mail address: carrievaldezmd@gmail.com (C. Valdez).

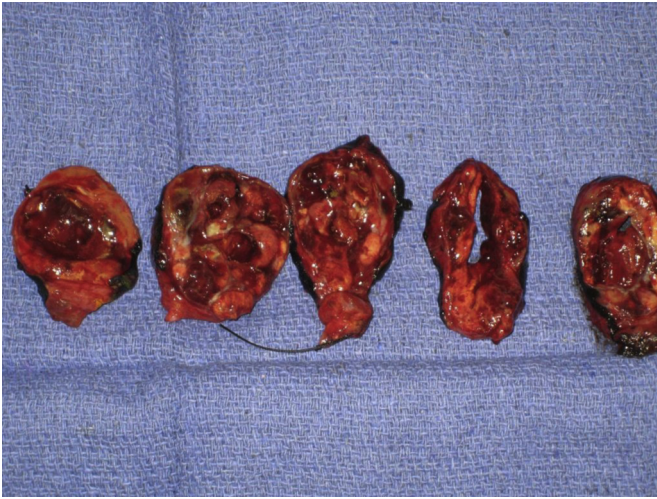


Figure 1. Large hemorrhagic mass with focal golden yellow discoloration, similar to conventional renal cell carcinoma.

nodules are thyroid cancer. Primary thyroid carcinoma increased from 1% to almost 3% over the past 20 years with the advent of extensive imaging of the head and neck, with incidental discovery of thyroid nodules.¹ Although metastatic disease to the thyroid gland is rare, when it does occur kidney is the most common primary tumor site.² Other primary sites include melanoma, lung, breast, esophagus, and uterus; our senior author reported a rare case finding of colon cancer metastasis to the thyroid.³

This report describes a tumor arising from the renal parenchyma; a clear cell carcinoma, which accounts for 70%–80% of all renal carcinomas. One of the common characteristics of clear cell carcinoma is its tendency to metastasize widely before giving rise to any local symptoms. In addition to the common sites, metastases from renal cancer can occur virtually anywhere in the body, including the thyroid.

When renal cell cancers recur, about 60% recur within 2 years, 70% within 3 years, 80% within 4 years, and most of the rest within 5 years. Recurrences can, however, occur many years later. It has

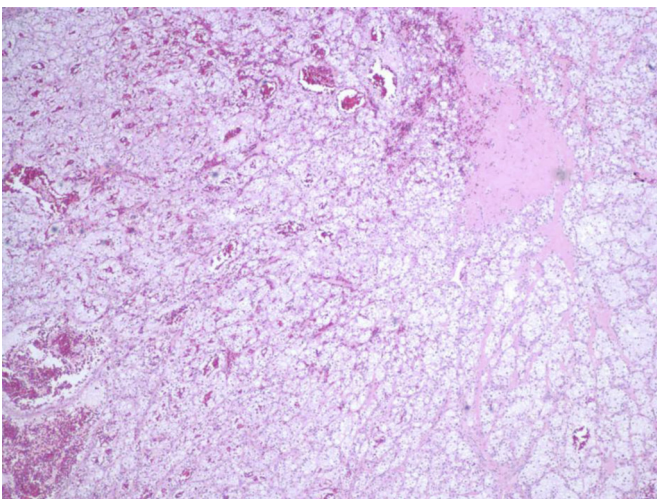


Figure 2. Nests of clear cells traversed by a rich capillary network, hematoxylin and eosin, medium power.

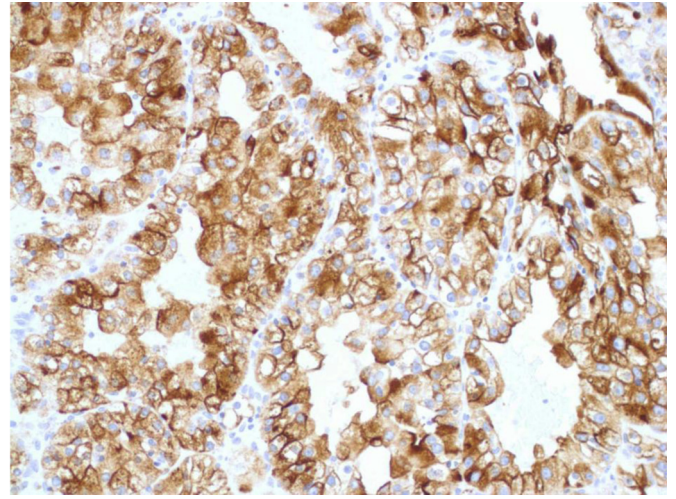


Figure 3. Strong diffuse labeling of tumor with renal cell carcinoma marker, high power.

been reported that 4%–11% of patients develop a recurrence 10 years after initial nephrectomy.⁴

The prognosis after surgical excision of clear cell tumors varies with the size of the tumor, the Fuhrman grade, and the pathologic stage. Overall, approximately 20%–50% of patients will develop metastatic disease after nephrectomy.⁵ However, clear cell cancers <5 cm in size, low grade (Fuhrman 1), and completely resected, carry an excellent prognosis with a recurrence rate of <5%. This was the prognosis for our patient based on her original pathology 23 years ago.

In a 10-year review of 43 patients with metastatic disease to the thyroid gland at the Mayo clinic, Nakhjavani² identified the kidney as the most common primary tumor site (33%), with an average time from diagnosis of the primary tumor to metastasis to the thyroid gland of 106 months. After a thorough review of the English scientific literature, we were not able to find a longer interval than our patient (23 years) from initial diagnosis of renal carcinoma to metastasis to the thyroid gland. There is no useful guidance in the literature on the extent of thyroidectomy for metastatic disease. In our case, we chose total thyroidectomy because our patient also had nodules within the contralateral lobe.

Conclusion

High-quality cytopathology services have become extremely important in the management of thyroid nodules. Needle aspiration is an accurate, quick, and low-risk technique that may yield interesting results such as in this case. This technique served our patient well in identifying the rare finding of metastatic RCC to the thyroid 23 years after initial diagnosis.

References

1. SEER Cancer Statistics Review, 1975–2009. 2012; Available from: http://seer.cancer.gov/csr/1975_2009_pop09/.
2. Nakhjavani MK, Gharib H, Goellner JR. Metastasis to the thyroid gland. A report of 43 cases. *Cancer*. 1997;79:574–578.
3. Hanna WC, Trachiotis GD, Knoll SM. Colon cancer metastatic to the lung and the thyroid gland. *Arch Surg*. 2006;141:93–96.
4. McNichols DW, Segura JW, DeWeerd JH. Renal cell carcinoma: long-term survival and late recurrence. *J Urol*. 1981;126:17–23.
5. Flanigan RC, Campbell SC, Clark JL. Metastatic renal cell carcinoma. *Curr Treat Options Oncol*. 2003;4:385–390.