

Available online on 25.12.2017 at <http://iddtonline.info>

## Journal of Drug Delivery and Therapeutics

Open Access to Pharmaceutical and Medical Research

© 2011-17, publisher and licensee JDDT, This is an Open Access article which permits unrestricted non-commercial use, provided the original work is properly cited

Open  Access

Research Article

### Studies on Combined Toxicity of Pendimethalin and Cadmium Chloride with Ameliorative Effect of Vitamin E-Selenium and Turmeric in Male Albino Rats

Supriya Shukla, Sushma Chakravarti, Anupam Chaturvedi, Sachin Verma, Aditya Sharma, Kuldeep Singh

Department of Veterinary Pathology, College of Veterinary Science and Animal Husbandry, MHOW (M.P.)-453446

E-mail address: s.shukla@gmail.com

#### ABSTRACT

The present investigation was undertaken to study the pathology of pendimethalin and cadmium chloride and to evaluate the different concentration were used as ameliorative agents to reduce the oxidative damage caused by free radicals generated by toxic pollutants at molecular levels. A total of 5 groups each of 12 rats were formed apart from control group. 2 groups of heavy metal and pesticide and 3 group of ameliorative oxidant in varying concentrations were formed. Group T2 was given standard ration along with combination of cadmium chloride at 500 ppm with pendimethalin (38.7%) at 1000 ppm/kg feed, Group T3 was given cadmium chloride at 100ppm/kg feed and P pendimethalin (38.7%) at 1000 ppm/kg feed with standard ration, Group T4 was fed with the combination of cadmium chloride at 50 ppm/kg of feed with pendimethalin at 1000 ppm/kg of feed and alpha tocopherol-selenium at 18 ppm/kg of feed. Lastly group T5 and T6 were given turmeric at 0.5% and 1% concentrations respectively along with the combination of cadmium chloride at 50 ppm with pendimethalin (38.7%) at 1000ppm and alpha tocopherol-selenium at 18ppm/kg of feed. During the toxicity studies observation like effect on CNS, effect on locomotor system recorded on the days 0, 7, 14, 21 and 28 of experiment.

**Cite this article as:** Shukla S, Chakravarti S, Chaturvedi A, Verma S, Sharma A, Singh K, Studies on Combined Toxicity of Pendimethalin and Cadmium Chloride with Ameliorative Effect of Vitamin E-Selenium and Turmeric in Male Albino Rats, Journal of Drug Delivery and Therapeutics. 2017; 7(7):216-217

#### INTRODUCTION:

Cadmium is a well known human carcinogen and a potent nephrotoxin. Higher concentrations are found in the kidneys of animal slaughtered for food, in wild mushrooms, and in sea food such as mussels and oysters<sup>1</sup>. Hepatic necrosis induced by cadmium chloride at 2.5mg/kg bwt s.c. in mice and was examined biochemically, haematologically and histopathologically in order to study the time dependent effect<sup>2</sup>. Cadmium caused primarily renal tubular lesion and sometimes glomerular lesions in rabbits, rats, swine and monkeys<sup>3</sup>. The protective effects of melatonin alone and vitamin E with selenium combination against cadmium induced oxidative damage in rat liver 1 mg/kg body weight and concluded that vitamin E had protective effects against cadmium induced oxidative damage<sup>4</sup>. Curcumin has a free radical scavenger activity, especially on the hydroxyl radical, which explains its capacity to protect DNA from damage in human cell cultures exposed to radiation. It is more efficient than vitamin E as an anti-radical agent and as an inhibitor of lipid per-oxidation<sup>5</sup>. The objective of this study was to study the combined toxicity of Pendimethalin and Cadmium chloride with ameliorative effect of vitamin E-Selenium and turmeric in male albino rats.

#### MATERIALS AND METHODS:

The study was conducted on male albino rat of 2 months age group, weighing around 80-150 gms. Before the start of the experiment, rats were kept in laboratory conditions for a period of 7 days for acclimatization. All the experimental animals were kept under constant observations during the entire period of study. The rats were maintained with good hygienic conditions and provided with standard feed and water *ad lib*. A total of 5 groups each of 12 rats were formed apart from control group. 2 groups of heavy metal and pesticide and 3 group of ameliorative oxidant in varying concentrations were formed. Group T2 was given standard ration along with combination of cadmium chloride at 500 ppm with pendimethalin (38.7%) at 1000 ppm/kg feed, Group T3 was given cadmium chloride at 100 ppm/kg feed and P pendimethalin (38.7%) at 1000ppm/kg feed with standard ration, Group T4 was fed with the combination of cadmium chloride at 50ppm/kg of feed with pendimethalin at 1000 ppm/kg of feed and alpha tocopherol-selenium at 18ppm/kg of feed. Lastly group T5 and T6 were given turmeric at 0.5% and 1% concentrations respectively along with the combination of cadmium chloride at 50ppm with pendimethalin (38.7%) at 1000 ppm and alpha tocopherol-selenium at

18 ppm/kg of feed. During the toxicity studies observation like effect on CNS, effect on locomotors system recorded on the days 0, 7, 14, 21 and 28 of experiment. Haematological parameter and biochemical parameters were studied. At the end of the 21<sup>st</sup> and 42<sup>nd</sup> day of experiment, animals were sacrificed by cervical dislocation. The organs like lung, liver, kidneys, spleen, heart and thymus were examined for any gross abnormality. A portion of the tissues were fixed in 10 % formalin. The formalin fixed tissue pices were serially processed through acetone and benzene and embedded in paraffin. The micro sections were cut and stained in haematoxyline and (H&E) and examined for histopathological changes.

## RESULTS AND DISCUSSION:

Six groups of rats (Group T1 –T6) comparing 12 animals each was fed with cadmium choride and pendimethalin and vitamin E –Se along with Turmeric for 6 weeks and six animals from each group were sacrificed at the end of 21<sup>st</sup> and 42<sup>nd</sup> day of experiment. The details of the experiment are-

**Toxicity study:** In present study the rats were slightly dull, dipressed, reduced feed intake and exhibited sluggish movements in T2, T3 and T4 group.

**Body weight:** In present study, there was a significant reduction in body weight in the cadmium chloride and pendimethalin fed groups as well as rats treated with alpha tocopherol as compared to the control. Supplementation of alpha- tocopherol along with cadmium chloride and pendimethalin caused marginal increase in body weight as compared to toxic group.

### Haematological studies

**Total erythrocyte count:** The total erythrocyte count was found significantly reduced in the rats treated with cadmium chloride and pendimethalin (T2, T3, and T4) the values were improved in T5 and T6 in 21<sup>st</sup> day of experimwent and almost analogous to control group at the terminal stage of study, when turmeric is given along with vitamin E at varying disease (T5 and T6).

**Haemoglobin concentration:** Decrease in haemoglobin concentration in pendimethalin and cadmium chloride fed rat of group T2, T3 and T4 might be due to anemia as a result of depressed erythropoiesis and erythrolysis.

**Total Leukocyte count:** There was a dose dependant reduction in the TLC values in T2, T3 and T4 groups and improvement in turmeric plus vitamin E treated group when compared with other groups at end of the experiment.

**Differential Leucocyte Count:** The overall study of differential leukocyte count did not revealed much significant in monocyte, eosinophils and basophils. Minor variations were seen in neutrophils (toxic) and lymphocytes in treated groups as compared with control.

### Biochemical studies

**Aspartate amino transferase (SGOT):** There was dose dependant significant increase in AST value in T2, T3 and T4 groups and slight improvement in the AST value in turmeric plus vitamin E group compared with respective toxic group at end of the experiment.

**Alkaline phosphate (ALP):** There was a dose dependent significant increase in ALP value in T2, T3 and T4 groups and minimum improvement in turmeric plus vitamin E treated group when compared with toxicity groups.

**Serum total protein:** There was a dose of dependent decrease in total protein value in T2, T3 and T4 groups and significant improvement in turmeric plus vitamin E treated group when compared with toxicity groups.

**Blood urea nitrogen (BUN:)** There was a dose dependent increase in blood urea nitrogen values in T2, T3 and T4 groups and significant improvement in turmeric plus vitamin E treated group when compared with toxicity groups.

**Creatinine:** There was a dose dependent increase in creatinine in T2, T3 and T4 groups and significant improvement in turmeric plus vitamin E treated group when compared with toxicity groups.

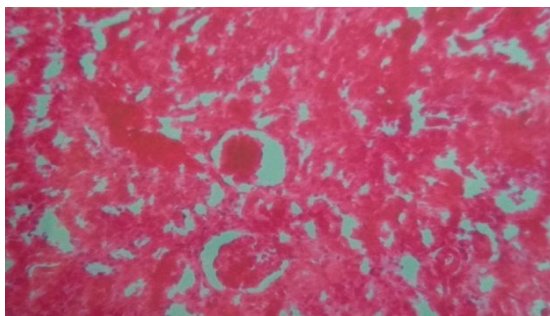
**Gross and histopathology:** The rat of group T1 (control group) revealed normal morphological appearance in organs examined during the study i.e., liver, kidney, brain, spleen at the end of experiment. The path-morphological changes observed in pendimethalin and cadmium chloride fed along with turmeric and vitamin E treated groups have been recorded organ wise follow-

**Liver:** Hepatomagaly with rounded border, congestion and hemorrhages was noticed in T2, T3 and T4 toxic groups.

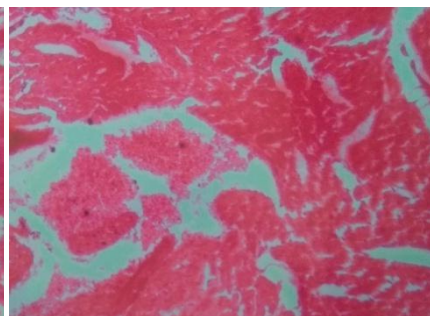
**Kidney:** kidney revealed congestion and hemorrhage at the both sacrifice day (21<sup>st</sup> and 42<sup>nd</sup>) of experiment in both toxicity levels (group T2 and T3).

**Lungs:** Area of congestion and hemorrhage were observed in the lungs of groups T2, T3 and T4 at the 21<sup>st</sup> and 42<sup>nd</sup> day of experiment.

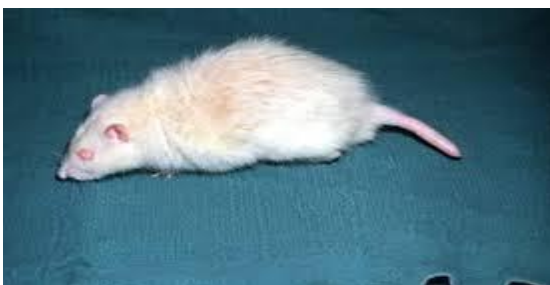**Heart:** in the group T2 and T3 mild degenerative changes were observed in heart muscles at 21<sup>st</sup> day of experiment.



**Figure 1:** Kidney showing congestion & Swelling of both proximal and distal convoluted tubules (H&E 400X)



**Figure 2:** Heart showing congestion and hemorrhage (H&E 400x)



**Figure 3:** Lacrimation and rough hair coat (group T2, T3, T4)



**Figure 4:** Ataxic gait and convulsion (group T2, T3, T4)

## CONCLUSION:

Ameliorative effect of turmeric was best observed in sub-acute toxicity of day 21 at 1% concentration but turmeric at 1% concentration did not show any corrective change in chronic toxicity of day 42.

## REFERENCES:

1. Fried KW, KK Rozman, Toxicity of selected chemicals .In: Greim, H. and Synder, R:toxicity and risk assessment: A Comprehensive introduction, John Wiley and Sons Ltd., 2008, 513-655.
2. Karmarkar R, Bhattacharya R, Chatt M, Biochemical haematological and histopathological study in relation to time related cadmium induced hepatotoxicity in mice, J Biometals, 2000,231-239.
3. Kara H, Aydin C, Konar V, Dayangac A,Servi K, Effects of selenium with vitamin E and melatonin on cadmium induced oxidative damage in rat liver and kidney, J Biol Trace Ele Res, 2008,120, 205-211.
4. Fatma ME, Demendash I, Fatma M, Kedwwany YS , Baghdadi HH , Cadmium induced changes in lipid peroxidation, blood haematology, biochemical parameters and serum quality of male rats; protective role of vitamin E and Beta-carotene, Food Chem Toxicol,2004, 42,1563-1571.
5. Prakash KC, Majeed AC, Hooper MJ, Porkras MA, Monitoring wading bird exposure to agricultural chemicals using turmeric activity, Environ Toxicol Chem, 2003, 19,1317-1323.