

Available online on 15.09.2014 at <http://jddtonline.info>**Journal of Drug Delivery and Therapeutics**

Open access to Pharmaceutical and Medical research

© 2014, publisher and licensee JDDT, This is an Open Access article which permits unrestricted noncommercial use, provided the original work is properly cited

RESEARCH ARTICLE

BOTOX! BETTER OPTION TO PROTECT CORNEA IN IDIOPATHIC BELL'S PALSY¹Dr. Mohammed Ather, ²Dr. Nasreen, ¹Dr. K V Neelima¹Gandhi Medical College, Secunderabad, Telangana State, India²Osmania Medical College, Hyderabad, Telangana State, India**ABSTRACT:****Aim:** Is to evaluate the efficacy of Chemo-denervation of LPS to induce temporary ptosis using Injection Botox in protecting Cornea and healing exposure keratopathy.**Materials & Methods:** Prospective interventional study conducted at Tertiary eye care centre of Hyderabad. Study period between June 2010 to May 2012. 24 cases of Bell's palsy, 11 males & 13 females between age group of 20-80 years were included in the study. Facial palsy due to CP angle tumors, Hansen's disease, Trauma, CSOM and post mastoidectomy were excluded as these are permanent causes. Patient with known allergy to Botox and patient who lost to follow up were also excluded. Cases included were examined by an ophthalmologist and radiologically evaluated to rule out other causes of facial palsy. Height of palpebral aperture, amount of Lagophthalmos, exposure keratopathy was documented. 0.25cc of injection Botox containing 6.25IU of Botox was injected at the insertion of LPS. Patient was examined at the end of 1st week, 2nd week, 4th week and 8th week to check all the 3 parameters.**Results:** At the end of 1st week in 16 cases mean palpebral height of 9mm (SD +/- 1.2mm) before injection was reduced to 2mm (SD +/- 1.0mm) after injection. At the end of 2nd week 8 cases achieved ptosis. Mean difference in Palpebral aperture height was 7mm (p value of 0.05) which is significant. All cases showed improvement in exposure keratopathy. 20 cases recovered from Bell's palsy within 8 weeks. 4 cases required 2nd injection of Botox as ptosis started recovering but Bell's palsy persists. Mean amount of Lagophthalmos of 4.3mm (SD +/- 0.7mm) before injection was reduced to 1.1mm (SD +/- 1.0mm) at the end of 2nd week. P value of <0.05 which is significant.**Conclusion:** Inj. Botox is safe and effective method to achieve ptosis by Chemo-denervation of LPS. Action of Botox remains for 8 weeks wherein 85% of cases recovered from Bell's palsy.**INTRODUCTION:**

Idiopathic Bell's palsy is the most common type of facial neuropathy, characterized by sudden onset of facial paresis/paralysis. It is common in adults and has equal sexual preponderance¹. It leads to Lagophthalmos (inability to close the eyelids completely) because of paralysis of Orbicularis oculi muscle. Inability to close lids will lead to exposure of cornea, dryness and ulceration. Corneal ulceration will not heal with conventional therapy of topical antibiotic eye drops and cycloplegic eye drops. Options available to heal the ulceration of cornea are temporary taping of lids with usage of lubricating eye drops and gel ointment to protect cornea. Other option is temporary tarsorrhaphy using sutures. Permanent methods of managing Lagophthalmos like Gold plate implant in lid, Permanent tarsorrhaphy, LPS recession is not required as 85% of Bell's palsy recovers by 8-12 weeks.

Injection of Botulinum toxin A is used to create temporary ptosis which covers cornea and helps in healing exposure keratopathy^{4,5,6}.

Aim:

Is to evaluate the efficacy of chemo-denervation of LPS to induce temporary ptosis using injection Botulinum

Toxin A in protecting cornea and healing exposure keratopathy.

Materials and Methods:

This is a prospective interventional study conducted at the department of Oculoplasty and orbital disorders of Sarojini Devi eye Hospital which is tertiary eye care centre in Hyderabad. Period of study was between June 2010 to May 2012.

24 cases of proven Bell's palsy were included in the study. 11 were males and 13 were females. Permanent causes of facial palsy like Cerebro-pontine angle tumors, Hansen's disease, Traumatic facial palsy, facial palsy due to CSOM, Post mastoidectomy facial palsies were excluded from study. Patient with known allergy to Botox and patient who lost to follow-up were also excluded from study. Informed consent was taken from all patients in their mother tongue.

Corresponding Author:*Dr Mohammed Ather**

Professor of Ophthalmology,

Gandhi Medical College,

Secunderabad, Telangana State, India

Email: ather11258@gmail.com

CODEN (USA): JDDTAO

24 cases of Bell's palsy were clinically examined by an experienced Ophthalmologist and radiologically evaluated to rule out CP angle tumour and other causes of facial palsy. Basic investigations like CBP, ESR, RBS, and CT scan Brain were carried out. Palpebral aperture height in primary gaze and amount of lagophthalmos were measured in millimeters. Exposure keratopathy was documented by staining cornea with Fluorescein sodium.

Preparation of BOTOX: A vial containing 50 IU of Botulinum Toxin A is diluted by 2cc of preservative free distill water. 0.25 cc of injection Botox was drawn in tuberculin syringe which is equal to 6.25 IU. Under all aseptic precautions in MOT patient's eyelid was cleaned by Betadine lotion and covered by sterile drape. Injection 2% Xylocaine 0.5 cc injected sub cutaneously on tarsal plate to anaesthetize the lid and inj. Botox was given at the insertion of LPS on tarsal plate transcutaneously. Treatment of ulcer cornea is continued by giving topical antibiotic eye drops and cycloplegic eye drops. Patient was examined at the end of 1st week, 2nd week, 4th week and 8th week. At every visit healing of corneal ulcer,

height of Palpebral aperture and amount of lagophthalmos was noted.

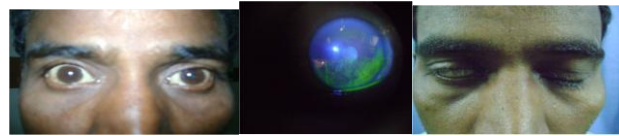
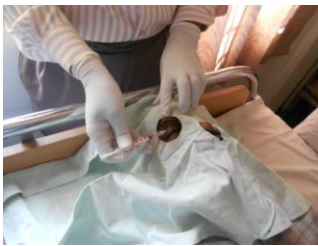RESULTS:

At the end of 1st week in 16 cases mean palpebral aperture height of 9mm (SD +/- 1.2mm) before injection of Botox was reduced to 2mm (SD +/- 1.0mm) showing the achievement of chemo-denervation.

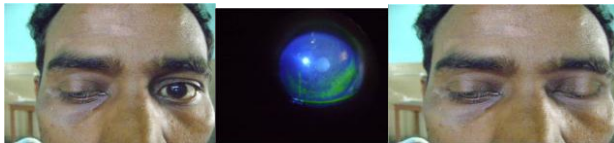
At the end of 2nd week remaining 8 cases developed ptosis. All 24 cases showed improvement in the status of healing of exposure keratopathy. Mean difference in palpebral aperture height before and after injection of Botox was 7mm (p value of 0.05) which is statistically significant.

20 cases recovered from Bell's palsy within 8 weeks. 4 cases needed 2nd injection of Botox as Ptosis started recovering and Bell's palsy didn't recover.

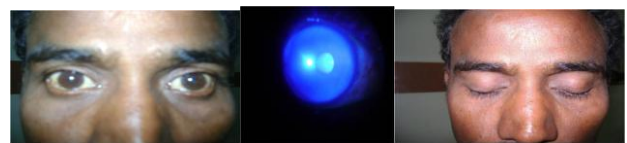
Mean amount of Lagophthalmos before injection of Botox was 4.3mm (SD +/- 0.7mm) was reduced to 1.1mm (SD +/- 1mm) at the end of 2nd week (p value of <0.05) was statistically significant.



Before Injection



After Injection(2nd week)



After Injection(8th week)

Figure 1: showing palpebral aperture, Lagophthalmos & Exposure keratopathy before inj. & 4th week & 8th week after inj. of botox

DISCUSSION:

24 cases of Bell's palsy of whom 11 were males and 13 were females, between the age group of 20 to 80 were selected for study. Male to female percentage ratio was 46/54 in present study which is matching with Adam et al study that had sex percentage ratio of 45.85/54.15⁶. All other study injected Botox at the belly of LPS muscle wherein chances of globe perforation is there. In present study we injected Botox at the insertion of LPS on Tarsal plate, which totally avoided globe perforation.

Median age of presentation in Milind Naik et al study was 30 years. In present study it was 40 years. Reduction in Mean palpebral aperture height of 9mm before injection to 2mm after injection in present study was comparable to Milind Naik et al.

Amount of toxin used in present study was 6.25IU which is less when compared to Milind Naik et al who used 12.5 IU⁷

Discussion

Study	Median age	Sex M/F	Site of inj.	Quantity of Toxin	Lagophthalmos	Height of Palp.app
Adams et al	NA	45.85/54.15	Belly of LPS	NA	NA	NA
Kirkness et al	NA	NA	Belly of LPS	NA	NA	NA
Ellis Daniel et al	NA	NA	Belly of LPS	NA	NA	NA
Milind Naik et al	30		Belly of LPS	12.5 units	NA	From 9mm - 2mm
Our study	40	46/54	Ant.surface of Tarsus	6 units	3.5 mm	From 9.5-2mm

CONCLUSION:

Injection of Botulinum toxin A is safe method to achieve temporary ptosis by chemo-denervation of LPS. Action of Botox remains for up to 8 weeks within which 85% of cases recovered from Bell's palsy. Only 4 cases required 2nd injection of Botox as Bell's palsy did not recovered

but action of Botox started wanning. This study concludes Injection of Botulinum toxin A is safe and effective in protecting cornea and healing exposure keratopathy in the cases of idiopathic Bell's palsy.

Note: Financial interest nil.

REFERENCES:

1. William J Lipham, Yanoff Text book of Ophthalmology 2010, 12.18:15.
2. Parsons
3. Wuebolt GE, Drummond G, Temporary tarsorrhaphy induced with type A Botulinum toxin. Canadian journal of Ophthalmology 1991;26:383-385.
4. Ellis MF, Daniel M: Evaluation of the safety & efficacy of Botulinum toxin A to produce protective ptosis- Clinical experimental ophthalmology 2001 Dec: 29(6) 394-399.
5. Kirkness CM, Adams CG, Dilly PN, Lee JP. Botox induce ptosis in corneal disease. Ophthalmology 1988;95(A):473-480.
6. Adams CG, Kirkness CM, Lee JP. Botulinum toxin A induced ptosis. Eye1987;1(part 5) 603-608.
7. Milind Naik et al Anterior chemo-denervation of LPS with Inj.Botox to induce temporary ptosis for corneal protection: Eye2008;22; 1132-1136.