

RESEARCH ARTICLE

EFFECTS OF OFLOXACIN ON EXPERIMENTAL FRACTURE HEALING IN WISTAR RATS

¹Balakrishna Shetty*, ¹Ajay Udyavar, ¹Chitra Prakash Rao, ¹Suresh Bidarkotimath, ²Viveka S, ³Santhosh Kuriakose

¹Department of Anatomy, A J Institute of Medical Sciences, Managalore, India. PIN - 575001

²Department of Anatomy, Azeezia Institute of Medical Sciences, Kollam, India. PIN - 691573

³Department of Anatomy, Amala Institute of Medical Sciences, Thrissur, India. PIN - 680 555

*Corresponding Author's Email: bbshetty26@rediffmail.com, Mob: 09448158864

ABSTRACT:

Background: The process of bone healing is highly influenced by many intrinsic and extrinsic factors. Ofloxacin is one of the extensively used broad spectrum antibiotic in current clinical practice, belongs to fluoroquinolones, which are known to have adverse effects on chondrocytes.

Objective: This study was undertaken to evaluate the bone healing process in untreated femoral fractures in rats under the influence of Ofloxacin. The effects were evaluated by means of radiology, histology and mechanical strength of callus by clinical examination.

Methodology: Study was conducted in four phases comprising of forty Wistar rats. Each phase had ten rats, which were divided into two group of 5 rats each, one study group and another control group. Unilateral displaced femoral fractures are produced in both groups and in study group, Ofloxacin administered for four weeks. After 4 weeks animals are killed and fractures examined clinically, radiographed and histological study of fracture callus was done. **Results:** Radiography and clinical examination showed signs of healing in all fractures. Histologically healing process showed progressive formation of callus but histological abnormalities were detected in study group compared to control group.

Conclusions: There was no clinically significant difference on bone callus strength and radiologically no signs of difference in union of femoral fractures with the use of ofloxacin when compared to control group. However histologically there were significant differences particularly around endochondral ossification front. This study differs from previous studies which report that ofloxacin may have some adverse effects on chondrocytes.

Key words: Ofloxacin; Chondrocytes; Experimental fracture healing; Wistar rats

INTRODUCTION:

Bone heals by bone. Fractured bone can be replaced to its original form without formation of scar. The process of fracture healing can occur in two ways. Primary bone healing occurs without callus formation and the secondary bone healing occurs with a callus precursor stage^{1,2}. The major diaphyseal fracture models are from animals like mouse, rat, rabbit^{3,4}. Although the bones of some animals (e.g. rat and sheep) differ physiologically from human bone (i.e. they do not undergo normal haversian remodelling), they have been widely used in orthopaedic research^{4,5,6}. Ofloxacin is a synthetic chemotherapeutic antibiotic of the second generation fluoroquinolone. The fluoroquinolones interfere with DNA replication by inhibiting an enzyme complex called DNA gyrase. Recent studies have demonstrated a correlation between mammalian cell cytotoxicity of the quinolones and the induction of micronuclei⁷. As such some fluoroquinolones may cause injury to the chromosome of eukaryotic cells. It is not recommended for usage in children because of serious reversible and irreversible musculoskeletal adverse effects.

Evaluation of experimental fracture healing: Radiography is a basic method for evaluating fracture healing both in clinical use and in animal studies: radiographs are able to visualize callus formation after mineralization^{8,9}. Radiographs are usually taken immediately after surgery to examine the location of the fracture and the quality of fixation. Animal is sacrificed

and high-resolution x-ray images are taken and bone density or bone dimensions are recorded. Histology is another basic method for evaluating fracture healing. Sections passing longitudinally across the fracture callus and the surrounding area are usually cut and stained. The histological parameters like callus formation, bone union, marrow changes and cortex remodeling are studied^{10,4}. Mechanical testing of healing fractures like bending, tension and torsional tests are useful tool in evaluating fracture healing^{4,11,12,13,14}.

There are many studies evaluating the effects of drugs on fracture healing in experimental models of variety of animals. A study in rats showed Ibuprofen and indomethacin retarded fracture healing, with significant differences in "mechanical healing" found between the control and experimental groups¹⁵. Chondrocyte toxicity and necrosis were seen with electron microscopy after incubation of human adult cartilage biopsy specimens in ciprofloxacin¹⁶. While the immediate clinical significance is unknown, the possibility of long-term cartilage damage after fluoroquinolone treatment cannot be excluded. Cultivation of rat chondrocytes in ciprofloxacin supplemented Mg++ free medium led to pronounced changes in the cytoskeleton and decreased adhesion of cells to the culture dish¹⁷. Experimental fractures systemically exposed to levofloxacin or trovafloxacin have diminished healing during the early stages of fracture repair¹⁸.

In the present study an attempt is made to evaluate the effects of ofloxacin on the chondrocytes and ossification front in the artificially induced fractures in femora of Wistar rats, through clinical, radiological and histological methods.

METHODOLOGY:

Fourty male (200- 300gram) Wistar rats were used in four phases in the study. In each phase there were two groups of five animals each. One experimental group was treated with ofloxacin and the second group was the control group. The procedures and the handling of the rats were reviewed and approved by the Institutional Animal Care and Use committee. All rats received humane care in compliance with the Guide for the Care and Use of Laboratory Animals. The rats were fed a standard chow, housed in a twelve-hour night-day-cycle environment, and allowed water without restriction. Displaced or undisplaced unilateral fractures of the femur were established with use of a three point bending device according to the model of Bonnarens and Einhorn¹⁹ Radiography was done to confirm fracture and type of displacement. Antibiotic administration was begun in the experimental groups two days after the fracture and was continued for four weeks. 15 milligrams of ofloxacin per kilogram of body weight was administered orally (endogastric intubation) twice daily at twelve-hour intervals. This time-frame was chosen to approximate the clinical conditions of administering ofloxacin, as in the treatment of a urinary tract or pin-site infection. The antibiotic dosage was selected to lead to peak concentrations of the drug in rat serum approximating those in humans. The control animals received no antibiotic treatment. Both control and test group animals were not treated for fractures (no splinting or internal/ external fixation). Four weeks after the fracture, all animals were killed with an overdose of sodium pentobarbital and the intact fracture calluses were recovered under sterile conditions. The fracture calluses from each treatment group were

1. Examined clinically for union
2. Radiographed to assess radiological union
3. Histologically evaluated

Clinical Union

As the animals were sacrificed fracture calluses were removed and clinical union of fractures were tested by mechanically stressing the fracture site and graded on mobility at fracture site.

Grade -1 -Mobile [no signs of healing]

Grade -2 -Sticky/ restricted mobility

Grade -3 -Stiff –no mobility

Histological Examination

Immediately after the animals were killed, the fracture calluses were removed and were fixed for two to three days in 10% neutral buffered formalin followed by two days in Bouin's solution and then decalcified in a 10% acetic acid, 0.85% NaCl, and 10% formalin solution. Specimens were embedded in paraffin,

sectioned longitudinally, and stained with hematoxylin and eosin.

The progression of fracture-healing in each specimen was quantified with use of a scale that assigns a grade based on the relative percentages of fibrous tissue, cartilage, woven bone, and mature bone in the callus^{1,17}.

- Grade 1 indicates fibrous tissue;
- Grade 2, predominantly fibrous tissue with some cartilage;
- Grade 3, equal amounts of fibrous tissue and cartilage;
- Grade 4, all cartilage;
- Grade 5, predominantly cartilage with some woven bone;
- Grade 6, equal amounts of cartilage and woven bone;
- Grade 7, predominantly woven bone with some cartilage;
- Grade 8, entirely woven bone;
- Grade 9, woven bone and some mature bone;
- Grade 10, lamellar (mature) bone.

Four slides were examined for each fracture.

Radiographic Study

Immediately after the fracture was produced, radiographs [Allenger -525 ,Mas-2,kv-38 exposure] of each rat femur were made to verify the position and characteristics of the fracture. After the animal was killed, the femora were disarticulated and radiographs were made for assessment of fracture-healing. Each fracture specimen was reviewed and classified for callus maturity according to the classification of Goldberg et al¹⁵.

In that classification,

- ✚ Stage 1 indicates nonunion
- ✚ Stage 2, possible union
- ✚ Stage 3, radiographic union

Goldberg radiological classification of fracture callus:

- ◆ Stage 1 = fracture callus without bridging bone,
- ◆ Stage 2 = fracture callus with bridging bone,
- ◆ Stage 3 = fracture callus with the fracture line no longer seen

RESULTS:

The clinical, radiological and histological grading of the calluses noted during the study is tabulated in table 1.

Clinical Analysis

There is no significant difference in callus strength at four weeks after fracture in rats treated with ofloxacin when compared to control group.

Radiographic Analysis

Radiological difference between the test and control group of the study was insignificant. Both groups show signs of radiological healing with radio-opaque callus formation (Figure 1 & 2).

Histological Analysis

The fracture calluses in control rats had a higher grade of histological healing in comparison to ofloxacin treated fractures, indicating a trend but not a significant

difference. Low-magnification histological analysis of the control fractures revealed formation of an external callus consisting of subperiosteal bone and cartilage (Fig. 3 & 4). Hypertrophic cartilage filled the entire space between the subperiosteal bone regions of the callus. Vascular invasion of the hypertrophic cartilage associated with endochondral ossification occurred in the callus at the interface of bone and cartilage.

Table 1: Clinical, radiological and histological grading of calluses of control and test group animals during the study

Control				Test			
Sl no	Clinical grading mechanical strength	Radiology	Histology	Sl no	Clinical grading mechanical strength	Radiology	Histology
Phase 1							
1	GR2	Gr2	Gr6	1	Gr2	Gr2	Gr5
2	GR2	Gr2	Gr6	2	Gr2	Gr2	Gr5
3	GR2	Gr2	Gr5	3	Gr2	Gr2	Gr6
4	GR2	Gr2	Gr6	4	Gr2	Gr1	Gr5
5	GR2	Gr2	Gr6	5	Gr1	Gr2	Gr5
Phase 2							
1	Gr2	Gr2	Gr6	1	Gr2	Gr2	Gr5
2	Gr2	Gr2	Gr6	2	Gr2	Gr2	Gr5
3	Gr2	Gr2	Gr5	3	Gr2	Gr2	Gr6
4	Gr2	Gr2	Gr6	4	Gr1	Gr1	Gr4
5	Gr2	Gr2	Gr6	5	dead		
Phase 3							
1	Gr2	Gr2	Gr6	1	Gr2	Gr2	Gr5
2	Dead			2	Gr2	Gr1	Gr4
3	Gr2	Gr2	Gr6	3	Gr2	Gr2	Gr6
4	Gr2	Gr2	Gr5	4	Gr2	Gr2	Gr5
5	Gr2	Gr2	Gr6	5	Gr2	Gr2	Gr6
Phase 4							
1	Gr2	Gr2	Gr5	1	Gr2	Gr2	Gr6
2	Gr2	Gr1	Gr4	2	Gr2	Gr2	Gr6
3	Gr2	Gr2	Gr6	3	Gr2	Gr2	Gr5
4	Gr2	Gr2	Gr5	4	Gr1	Gr1	Gr4
5	Gr2	Gr2	Gr6	5	Gr2	Gr2	Gr5

At higher magnification, this bone-cartilage interface was seen to have the histological characteristics of endochondral ossification, including vascular invasion into regions of hypertrophic chondrocytes, osteoid deposition on spicules of calcified cartilage, and formation of spicules of cartilage covered by woven bone. With the continued deposition of bone, the cartilage-bone spicules thickened into the normal trabecular bone in the hard callus. The specimens from the ofloxacin-treated animals had the same general pattern of external callus formation, hypertrophic chondrocytes distribution, and endochondral ossification.

However, differences were observed between the calluses from these animals with respect to control animals. Ofloxacin treated animals displayed a central portion of the soft callus incompletely filled with cartilage. These central portions appeared less cellular, and the cells exhibited a flattened, fibroblast-like morphology. High-power views of the endochondral ossification front showed additional abnormalities in the cartilage and trabecular structures of the calluses from the ciprofloxacin-treated animals (Fig. 4 & 6). These abnormalities included a decreased number of chondrocytes, an increase in chondrocyte size, and an

increased proportion of cartilage in the newly formed trabecular bone spicules compared with the control specimens. These differences were observed most clearly on the higher magnification photomicrographs of the

endochondral ossification front. The calluses from the ofloxacin treated animals appeared to contain more cartilage and less bone in the newly formed trabeculae than the control calluses.

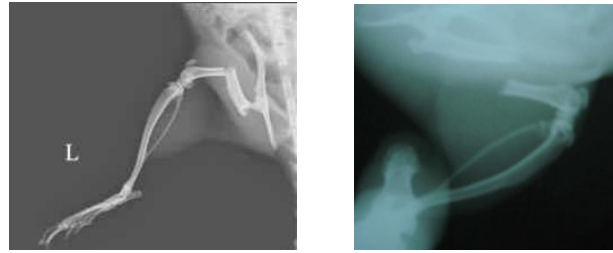

Figure 1: X ray showing fresh fractures in test groups.

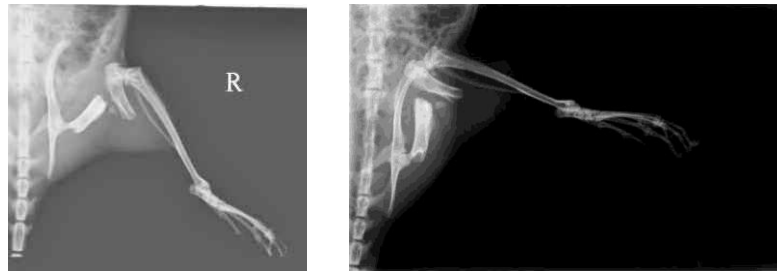


Figure 2: X ray showing fracture callus after 4 weeks.

The calluses from the ofloxacin-treated animals contained a smaller number of hypertrophic chondrocytes at the endochondral ossification front (Fig. 6, 8 & 9) than did the calluses from the control animals (Fig. 5 & 7).

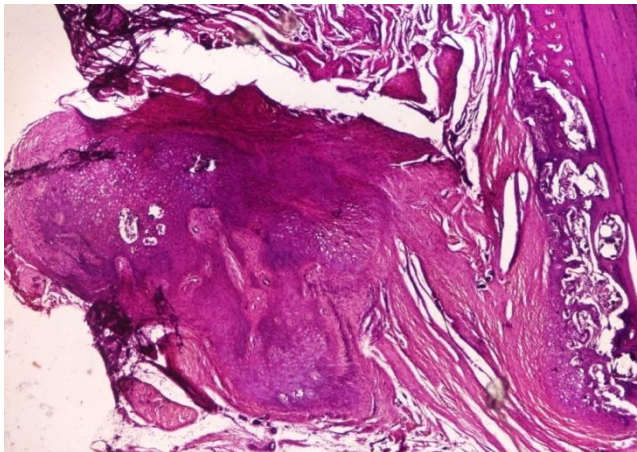


Figure 3: Callus in control group rat in low magnification 4x view.

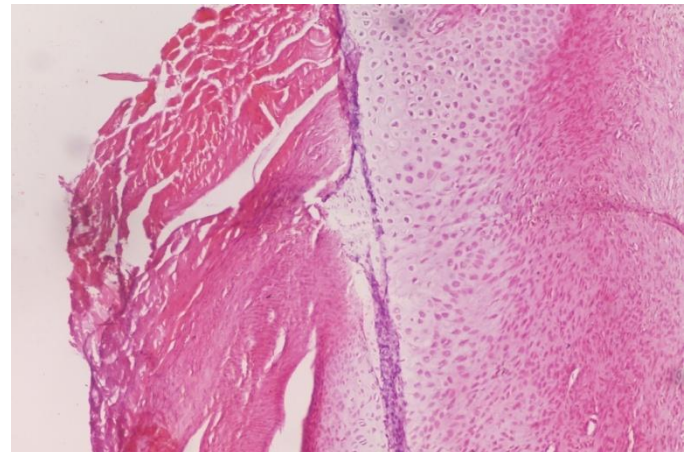


Figure 5: Cartilage in endochondral ossification front, Control group, 10x view.

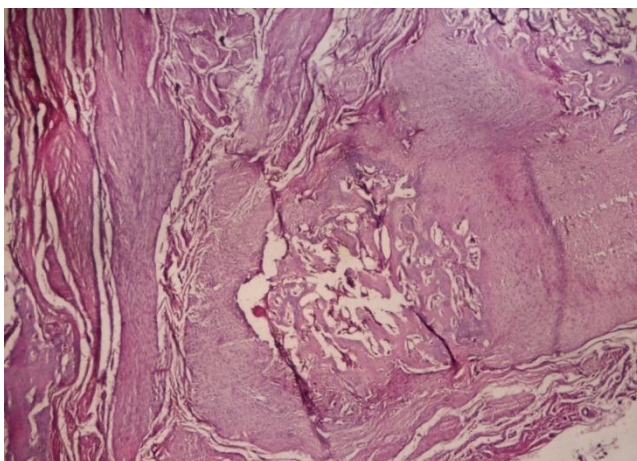


Figure 4: Callus deficient cartilage in the center, test group, 10x view.

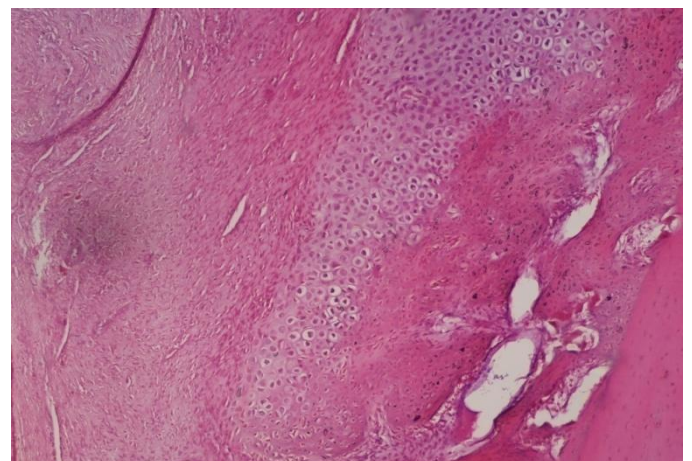


Figure 6: Test group, showing predominant cartilage in callus, 10x view.

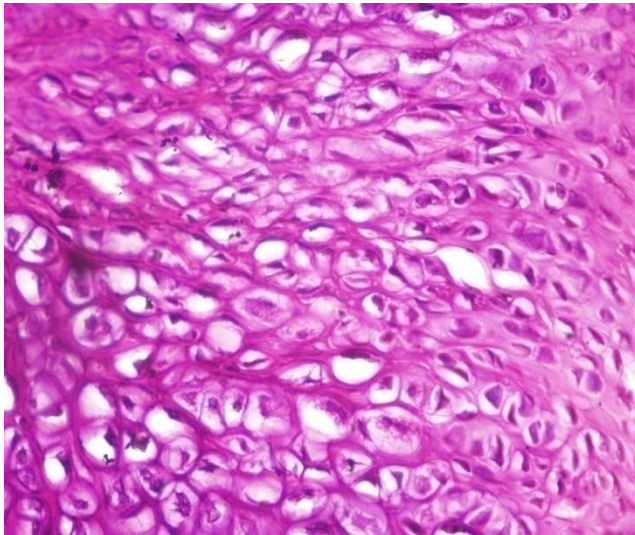


Figure 7: Endochondral ossification front in control group showing thick trabeculae, 40x view.

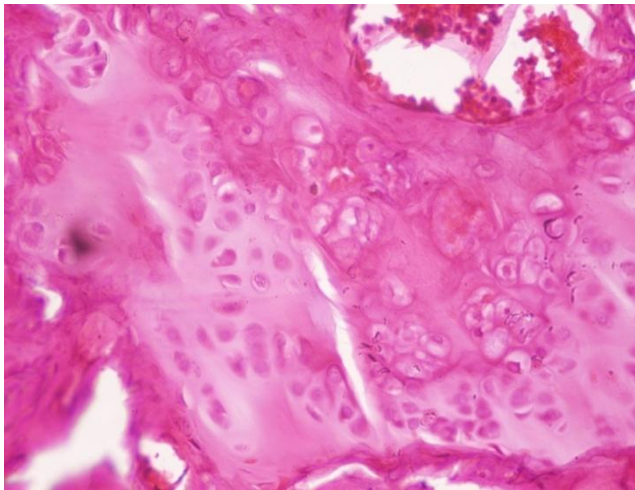


Figure 8: Endochondral ossification front in test group showing sparse hypertrophied chondrocytes, 40x view.

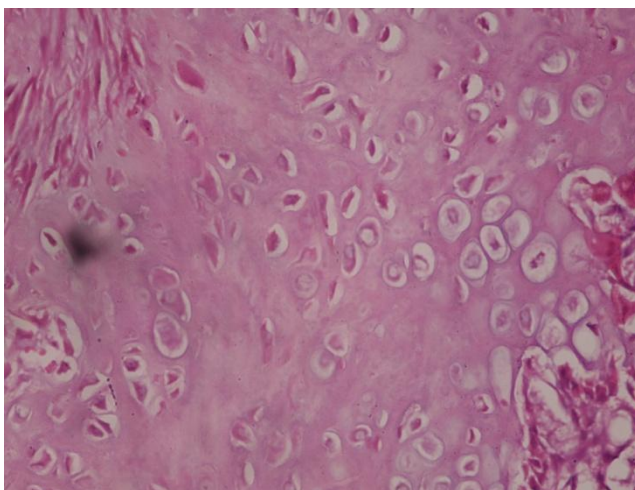


Figure 9: Test group, showing sparse chondrocytes, 40x view.

DISCUSSION:

In the present study all the fractures were displaced and are not treated. All were unstable, mobile fractures. It will take longer time to develop mechanical stability of

fracture site. Therefore mechanical testing was not undertaken. Clinical assessment of fracture callus in terms of functional stability of the limb was done. In the study there is no significant difference in callus strength at four weeks after fracture in rats treated with ofloxacin when compared to control group. This observation is contrary to many other studies which support the hypothesis that exposure to ofloxacin affects early fracture healing and alters the progression of normal fracture callus formation. Fabiano Kupczik studied the effects of ciprofloxacin on fracture healing in rat femora and found similar results as the current study. In our study radiological evaluation of fracture callus showed no difference between test and control group. Similar results were reported in previous study. In the study by Fabiano Kupczik rat fractures were treated with intramedullary K-wire fixation and the biomechanical study was carried out on a three-point flexion strength assay device (tension/compression). No histological studies were done. Drug used was ciprofloxacin²⁰.

Although histological examination of the fracture calluses from the ofloxacin-treated animals showed progressive formation of cartilage and subperiosteal bone and replacement of cartilage by endochondral ossification, histological abnormalities were apparent when the specimens were compared with the fracture calluses from control animals. These abnormalities included a persistent central region of fibrous tissue, a decreased size and number of chondrocytes at the endochondral ossification front, and abnormalities of trabecular bone formation. The decreased number and size of the chondrocytes in the fracture callus of the ofloxacin-treated animals suggest that ofloxacin may have a primary effect on chondrocyte maturation and development. This adverse effect on chondrocyte function then leads to an inefficient conversion of cartilage to bone, which is manifested by decreased mechanical properties of the fracture callus. Histological findings in present study are comparable to studies by Huddleston²¹, Tuncay²² and Perry AC¹⁸. These studies demonstrate by histological, X-ray and biomechanical analysis that bone union was delayed with the use of therapeutic concentrations of ciprofloxacin and other quinolones.

In a study involving histological, X-ray, biomechanical and ultra-structural analyses of effects of ciprofloxacin on experimental fracture healing states that bone union is delayed with therapeutic dosage of the drug²¹. However, fractures were produced on both femurs, they did not report if they were fixed or not; the antibiotics administration started only one week after the fracture, the rats were sacrificed at week 4, the biomechanical test was carried out by assessing strength and stiffness with torsion failure and gross evaluation of bones was not reported after bone disconnection.

Concerning the study by Tuncay, the authors have also conducted an experimental study on rats and histologically assessed bone union after the administration of four kinds of quinolones (ofloxacin, norfloxacin, pefloxacin and ciprofloxacin)²². They concluded that all those quinolones delayed bone callus formation in rats. Consistently to the first study, fractures

were produced on both sides, quinolones were only administered after seven days of fracture, for three weeks, and the animals were sacrificed at week four.

With regard to these studies, some differences exist to our method. First, ofloxacin administration started from day one of fracture, because as early as in the second week, cartilaginous cells appear.

Further studies are warranted, including histopathological and immuno-histochemical analysis in order to prove a negative influence exerted by this drug on fractures

CONCLUSIONS:

We conclude that there was no clinically significant difference on bone callus strength and radiologically no

signs of difference in union of femoral fractures with the use of ofloxacin when compared to control group.

However histologically there were significant differences particularly around endochondral ossification front. Compare to other studies ofloxacin may have some adverse effects on chondrocytes. But further studies required knowing the clinical significance of adverse effect.

ACKNOWLEDGEMENTS:

We thank Dr. Mohandas Rai for providing permission to utilize the animal house facilities and Dr. Ganesh K for allowing us to take X-rays of fractures.

REFERENCES:

1. Frost HM. The biology of fracture healing. An overview for clinicians. *Clin Orthop Relat Res.* 1989,248:283-93.
2. Greenbaum MA, Kanat IO. Current concepts in bone healing. Review of the literature. *J Am Podiatr Med Assoc.* 1993, 83:123-29.
3. Arnoczky SP, Wilson JW. Experimental Surgery of the Skeletal System. [book auth.] Gay WI. Methods of Animal Experimentation. Orlando : Academic Press, 1986, p. 67-108.
4. An YA, Friedman RJ & Draughn RA. Animal models of bone fracture or osteotomy. [book auth.] An YA& Friedman RJ. Animal models in orthopaedic research . Boca Raton : CRC Press, 1999.
5. Miller SC, Bowman BM & Jee WS. Available animal models of osteopenia--small and large. *Bone.* 1996, 17:117S-123S.
6. Sietsema, WK. Animal models of cortical porosity. *Bone.* 1995, 17:297S-305S.
7. Yokota, Hosomi JA, Maeda Y, Oomori T, Irikura and T. Mutagenicity of norfloxacin and AM-833 in bacteria and mammalian cells. *Rev. Infect. Dis.* 1988, 10:S148-S150.
8. Aronson J, Shen X. Experimental healing of distraction osteogenesis comparing metaphyseal with diaphyseal sites. *Clin Orthop.* 1994, 301:25-30.
9. Kato T, Kawaguchi H, Hanada K, Aoyama I, Hiyama Y, Nakamura T, Kuzutani K, Tamura M, Kurokawa T & Nakamura K. Single local injection of recombinant fibroblast growth factor-2 stimulates healing of segmental bone defects in rabbits. *J Orthop Res.* 1998,16: 654-59.
10. Eriksen EF, Axelrod DW, Melsen F. [book auth.] Eriksen EF. Bone histomorphometry. New York : Raven Press Ltd, 1994.
11. Keller TS, Liebschner MAK. Tensile and Compression Testing of Bone. [book auth.] An YA& Draughn RA. Mechanical Testing of Bone and the Bone-Implant Interface. Boca Raton : CRC Press, 2000, p. 175-205.
12. Lopez MJ, Markel MD. Bending Tests of Bone. [book auth.] An YA& Draughn RA. Mechanical Testing of Bone and the Bone-Implant Interface. Boca Raton : CRC Press, 2000, p. 207-217.
13. Saha, S. Torsional Testing of Bone. [book auth.] An YA& Draughn RA. Mechanical Testing of Bone and the Bone-Implant Interface. Boca Raton : CRC Press, 2000, p. 219-231.
14. Ekeland A, Engesaeter LB & Langeland N. Mechanical properties of fractured and intact rat femora evaluated by bending, torsional and tensile tests. *Acta Orthop Scand.* 1981, 52 :605-613.
15. Altman RD, Latta LL, Keer R, Renfree K, Hornicek FJ, Banovac K. Effect of nonsteroidal antiinflammatory drugs on fracture healing: a laboratory study in rats. *J Orthop Trauma.* 1995, 9(5):392-400.
16. M Menschik, J Neumüller, C W Steiner, L Erlacher, M Köller, R Ullrich, W Graninger, and W B Graninger. Effects of ciprofloxacin and ofloxacin on adult human cartilage in vitro. *Antimicrob Agents Chemother.* 1997, 41(11):2562-65.
17. Monika Egerbacher, Gertrude Seiberl, Birgitt Wolfesberger and Ingrid Walter. Ciprofloxacin causes cytoskeletal changes and detachment of human and rat chondrocytes in vitro. *Arch Toxicol.* 1999, 73:557-63.
18. Perry AC, Prpa B, Rouse MS, Piper KE, Hanssen AD, Steckelberg JM, Patel R. Levofloxacin and trovafloxacin inhibition of experimental fracture-healing. *Clin Orthop Relat Res.* 2003, 414:95-100.
19. Väänänen, HK. Luun elmänkaari. *Duodecim.* 1996,112: 2087-94
20. Kupczik Fabiano, Vialle Luiz Roberto Gomes, Nobre Leonardo Oliveira, Vieira Lucas de Almeida, Fernandes André Eugênio Omine. Influence of ciprofloxacin on femoral fractures healing in rats. *Acta ortop. bras.* 2009, 17:1342-56.
21. P M Huddleston, J M Steckelberg, A D Hanseen, M S Rouse, M E Bolander. Ciprofloxacin Inhibition of Experimental Fracture-Healing. *J Bone Joint Surg Am.* 2000, 82:161-73.
22. Tuncay I, Ozbek H, Köşem M, Unal O. A comparison of effects of fluoroquinolones on fracture healing (an experimental study in rats). *Ulus Travma Acil Cerrahi Derg.* 2005, 11:17-22.