

Hyperadrenocorticism Induces Demodicosis in Shih Tzu Dog

Maulana Arraniri Putra*, Cucu Kartini Sajuthi

PDHB 24hrs Veterinary Clinic, Nirwana Sunter Asri III Blok J 1/2 Sunter, Jakarta Utara

ABSTRACT: A 10-year old male intact Shih Tzu, was presented to our clinic with complains of skin and hair problem. The condition had been appeared for 3 months. The antifungal medicated shampoo was given to the patient by the previous veterinarian, but there was no any clinical improvement. The clinical symptoms included alopecia in the dorsal body and trunk, comedones, hyperpigmentation, scales, lichenification, *pot bellied*, polyuria and polydipsia. Skin scraping and trichogram in the face area and fore limb found *Demodex sp.* Adult onset generalized demodicosis usually has an underlying cause. Endocrine disorders such as hypothyroidism and hyperadrenocorticism must be ruled out. From the clinical sign and laboratory work suggested for Low Dose Dexamethasone Suppressing Test (LDDST). Cortisol value after 8 hours of low dose dexamethasone injection was greater than basal cortisol, it means dexamethasone failed to suppressing cortisol level due to the high number of cortisol in the body. From LDDST the diagnose of hyperadrenocorticism (Cushing syndrome) has been made. The dog was given trilostane (Vetoryl[®]) 3mg/kg SID for the Cushing and imidacloprid and moxidectine spot on (Advocate[®] spot on) every 2 weeks for the demodicosis. Scales and lichenification was reduced and the skin got better after 3 weeks. Unfortunately, after 3 months of treatment, the dog had neurological sign including seizure, head tilt and nystagmus. From the neurological sign, we suspected that the dog had macroadenoma type of hyperadrenocorticism. A week after hospitalization, the owner decided to euthanize the dog.

Keywords:

Cushing, hyperadrenocorticism, demodicosis, canine

■ INTRODUCTION

Demodicosis is a common canine skin disease. It can be localized and generalized (juvenile- and adult-onset). Adult-onset demodicosis has been reported caused by immunosuppressive treatment for neoplasias or auto-immune disorders, or diseases that is altering the immune response such as hypothyroidism, hyperadrenocorticism, leishmaniasis, and neoplasias (Campbell 2004). Hyperadrenocorticism described as the excessive production or administration of glucocorticoids and it is one of the most commonly diagnosed endocrinopathies in the dogs. High level of glucocorticoid in body will diminishes inflammatory response and reduces immune response (immunosuppression) (Herrtage dan Ramsey 2012). Immunosuppression induces demodex mites to proliferate into the skin and causes demodicosis. The purpose of this study was to learn about correlation between hyperadrenocorticism and demodicosis in dog and the treatment.

■ SIGNALEMENT AND ANAMNESES

A 10-year old male intact Shih Tzu, was presented to our clinic with complains of skin and hair problem. The condition had been appeared for 3 months. The antifungal medicated shampoo was given to the patient by the previous veterinarian, but there was no any clinical improvement.

■ CLINICAL SIGNS

The clinical symptoms included alopecia in the dorsal body and trunk, comedones, hyperpigmentation, scales, lichenification, pot-bellied, polyuria and polydipsia. Skin scraping and trichogram in the face area and fore limb found *Demodex sp.* Based on the age of the dog we suspected dog had concurrent disease that inducing demodicosis. Following a clinical examination was hematologic, biochemical test, urine analysis and also low dose dexamethasone suppression test (LDDST).

■ RESULT AND DISCUSSION

Demodex mites are normal flora of the skin and ear canals in dogs and cats (Campbell 2004). Proliferation of this mites into the skin (usually the hair follicle) will cause demodicosis (Hui-Pi dan Yu-Hsin 2013). Adult onset generalized demodicosis usually has an underlying cause. Endocrine disorders such as hypothyroidism and hyperadrenocorticism must be ruled out (Campbell 2004).

Diterima : 21 Juli 2017

Direvisi : 8 Agustus 2017

Disetujui : 11 Agustus 2017

Blood chemistry showed increase in alkaline phosphatase, blood glucose and cholesterol. It can be caused by increase of corticosteroid in the body. Urine analysis showed hypostenuria with mild proteinuria without glucosuria. High level of glucocorticoid will inhibit Anti Diuretic Hormone (ADH) and causes polyuria and polydipsia. From the clinical sign and laboratory work suggested for Low Dose Dexamethasone Suppressing Test (LDDST). Cortisol value after 8 hours of low dose dexamethasone injection was greater than basal cortisol, it means dexamethasone failed to suppress cortisol level due to the high number of cortisol in the body. From the result, the dog was diagnosed with Hyperadrenocorticism (Cushing syndrome) with demodicosis as secondary diseases. The LDDST graph (Figure 1) showed the dog had pituitary dependent hyperadrenocorticism.

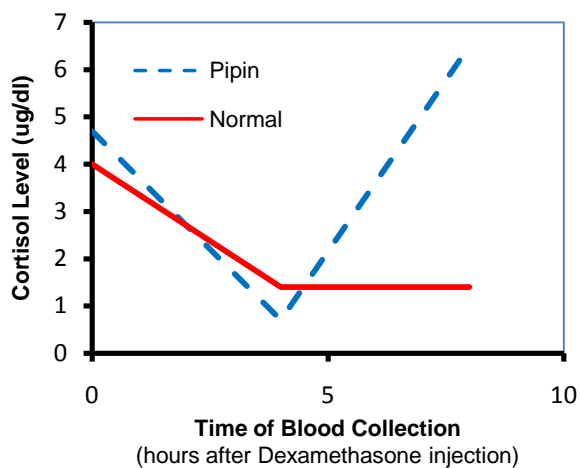


Figure 1 Low Dose Dexamethasone Suppression Test

The dog was given trilostane (Vetoryl®) 3mg/kg SID for the Cushing and imidacloprid and moxidectine spot on (Advocate® spot on) every 2 weeks for the demodicosis. Scales and lichenification was reduced and the skin showed improvement after 3 weeks. Trilostane is a synthetic steroid with no inherent hormonal activity. Trilostane primarily acts as a competitive, and therefore reversible, inhibitor of the 3β -hydroxysteroid dehydrogenase enzyme system, which blocks adrenal synthesis of glucocorticoid, mineralocorticoids and sex hormones (Herrtage dan Ramsey 2012). The weekly application of spot-on moxidectin/imidacloprid appeared to be effective and safe against generalized adult

onset canine demodicosis associated with hyperadrenocorticism (Hui-Pi dan Yu-Hsin 2013).

Unfortunately, after 3 months of treatment, the dog had neurological sign including seizure, head tilt and nystagmus. From the neurological sign, we suspected that the dog had macroadenoma type of hyperadrenocorticism. A week after hospitalization, the owner decided to euthanize the dog.

■ CONCLUSION

Hyperadrenocorticism alters the immune response by producing high amount of cortisol and causes immunosuppression. This condition will induce demodicosis in adult-onset. Combination between moxidectine and imidacloprid spot-on (as a treatment for demodicosis) and trilostane (as a treatment of hyperadrenocorticism) appear to be effective to treat demodicosis associated with hyperadrenocorticism.

■ AUTHOR INFORMATION

Corresponding Author

info@pdhbvet.com

Author Contributions

All authors contributed equally and approve with this publication.

■ ACKNOWLEDGMENT

We would like to acknowledge drh. Muntofiah from PT. Multi KaryaVetatama (MK Vet) as the sponsor of this publication.

■ REFERENCES

- Campbell KL. 2004. Parasitic Skin Diseases. Di dalam: *Small Animal Dermatology Secrets*. Philadelphia (US): Hanley & Belfus.
- Herrtage ME, Ramsey IK. 2012. Canine hyperadrenocorticism. Di dalam: *BSAVA manual of Canine and Feline Endocrinology 4th Edition*. Gloucester (UK): BSAVA.
- Hui-Pi H, Yu-Hsin L. 2013. Treatment of canine generalized demodicosis associated with hyperadrenocorticism with spot-on moxidectin and imidacloprid. *Acta Veterinaria Scandinavica*. 55: 40-45.