

Oral Presentation (SA-1)

Conjunctivitis Treatment in Dog with *Alkaline Water Eye Drop*

A. A. S. I. Pradnyantari^{1*}, A. A. N. G. D. Wisesa², I. W. Y. Semarariana², A. A. N. O. Pujawan²,
M. P. A. Yunikawati², P. T. E. Sucitrayani², P. S. Dwipartha², I. N. Suartha³

¹Denpasar Veterinary

²Kedonganan Veterinary

³Faculty of Veterinary Medicine, Udayana University

Keywords: alkaline eye drop, dog, conjunctivitis.

INTRODUCTION

Conjunctivitis is an inflammation of the conjunctival tissue that lines the eyelids and covers the sclera. The conjunctiva is the exposed mucous membrane and reacts to antigenic stimulation caused by contact with harmful stimuli. Handling of cases of conjunctivitis is generally treated with the administration of glucocorticoid antibiotics and topical antibiotics and broad spectrum (Ron, 2017). However, handling using Alkaline Eye Drop is still rare even never done especially in dogs. Alkaline Eye Drop is a liquid with an alkaline pH, the normal dog's eye pH is 8.05 (Billie et al, 2014). Alkaline water is easy to obtain and affordable. The use of Alkaline water to date has not been detected toxicity in the eye. But it is already used in humans to drink and cause antioxidant effects to the body (Rosa et al., 2012). It became the basis of the use of Alkaline Eye Drop for treatment in this case. The purpose of this paper is to get a more efficient, effective and without complications.

CASE REPORT:

Signalmen

The dog's name is Helly. He is Pekingese mix local breed dog. He's one year old and his weight is 8 kg. He has black and brown color of hair.

Anamneses

Dog at home was visited with complaints from the owner of both eyes cannot open start from three days ago. Four days ago the dog liked to sunbathe and play the dusty yard.

Clinical Signs

Physical examination was performed and from the inspection, the dog seems difficult to open both eyes, there was a serous discharge and when the palpation was done in the dog's eye there are conjunctival parts that experience inflammation and redness. The pupil's response to the eye is still normal but the lens in the eyeball turns blue or cloudy. The mucosa in dogs is reddish and capillary refill time is less than one second. When palpated, both lymphoglandula do not experience swelling. And dog temperature was at 38.9°C. His heartbeat

120 times per minute and respiration rate was 44 times per minute.

Result of Laboratory Assay

There was no laboratory test was done on this case.

Diagnoses

From the results of anamneses and physical examination, this dog is conjunctivitis.

Prognoses

The prognoses of dogs with conjunctivitis is fausta.

Therapy

The therapy was using topical therapy that begin with cleaning the eyes using cotton and NaCl solution. After that, it was given a water-containing alkaline eye drop with a pH of 8-11 (base) dripped twice a drop in a day for 14 days.

DISCUSSION

The first until third days, there have been no significant changes to the eyes and still difficult to open, but the serous discharge began to decrease (Figure 1). In the fourth until sixth day were the eye condition has begun to slowly open with normal pupillary response but the color of the lens is still bluish or cloudy (Figure 2). And in the seventh to ninth day were showing the condition of the eyes begin to open and the inflammation begins to subside.

On Tenth days, the progress was much better, the eyes are fully open but the color of the lens was still bluish. In the eleventh day until thirteenth, the eye condition was opened and lens color started back to normal and serous discharge was gone (Figure 3). In the fourteenth day the eye condition was clear with no serous condition, normal lens color, and active dog and can see as before (Figure 4).

When dripped, the dog exhibits a non-aggressive and calm response. Alkaline water was chosen as a form of prevention against antibiotic resistance. Inappropriate use of antibiotics will

lead to long-term resistance to antibiotics without definitive diagnosis based on laboratory tests such as full blood counts.

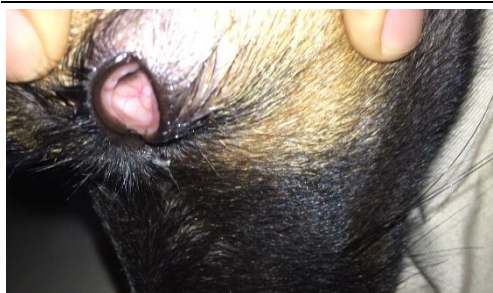


Figure 1

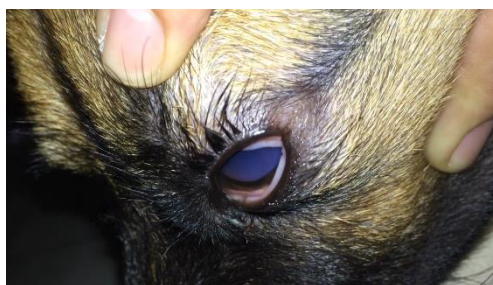

Figure 2

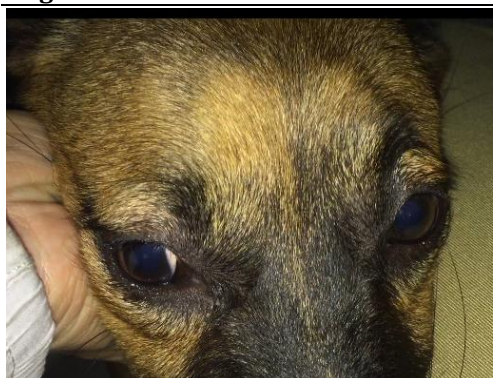


Figure 3

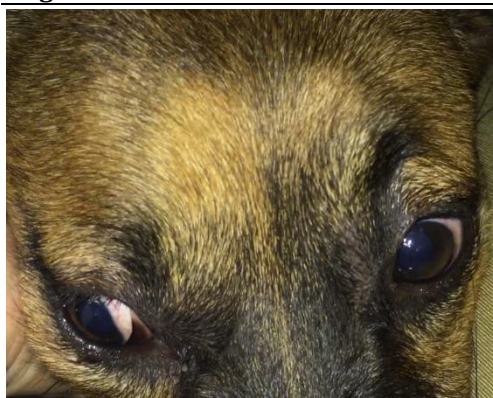


Figure 4

CONCLUSION

The alkaline water eye drop was a good treatment for conjunctivitis in dog.

ACKNOWLEDGEMENTS

Thank you to Denpasar Veterinary team for the help of this case study and the support from Usadha Buron Indonesia team.

REFERENCES

- [1] Billie BC, Daniel E, Tali BA, Ron O. 2014. Comparison of tear pH in dogs, horses, and cattle. University of California. Berkeley. DOI 10.2460
- [2] Ron O. 2017. Conjunctivitis in Dogs. Hebrew University of Jerusalem Rehovot. Israel