

Oral Presentation (FA-4)

Assessment of Estrous Cycle Using Ultrasound to Determine Time of Insemination In Banteng (*Bos javanicus*, d'Alton 1823)

Dedi Rahmat Setiadi*^{1,2}, Muhammad Agil², Iis Arifiantini², Tuty L Yusuf², Muchidin Noordin⁴
Yohana Tri Hastuti⁵, Setyaningsih Rambu Liwa⁵, Jansen Manansang⁵, Dondin Sajuthi³

¹Study Program of Reproductive Biology-Graduate School of IPB; ²Division of Obstetric and Gynaecology, Faculty of Veterinary Medicine, Bogor Agricultural University; ³Division of Veterinary Internal Medicine, Faculty of Veterinary Medicine, Bogor Agricultural University; ⁴Breeding Consultant of Indonesia Safari Park, Cisarua, Bogor; ⁵Indonesia Safari Park, Cisarua, Bogor.

*Corresponding author's email: rhinogil@googlemail.com

Keywords: artificial insemination, banteng, oestrous, rectal palpation, ultrasonography.

INTRODUCTION

Banteng is considered as endangered species by the International Union for Conservation of Nature (IUCN). Banteng is currently distributed in Java, in Kalimantan [Indonesian Borneo], Sabah [part of Malaysian Borneo], Myanmar, Thailand, Cambodia and, probably Lao PDR and Vietnam (1). The populations in the Asian mainland have decreased by about 80% in the last decades. The total number of wild banteng is estimated to about 5,000-8,000 animals. No population has more than 500 animals, only a few have more than 50. Reasons for the population decline are reduction of habitat, poaching, hybridisation with domesticated cattle, and infections with cattle diseases (4).

Since the wild population has been declining continuously and the numbers of individual are getting smaller, therefore captive breeding is urgently needed in order to support the conservation of Banteng sustainably. Although breeding program of Banteng is important, but information about the reproductive biology of Banteng is very limited. Breeding programs in Banteng can be done by natural mating or using assisted reproductive technology such as artificial insemination (AI). The application of AI in Banteng can support Banteng conservation program in order to increase heterozygosity, prevent inbreeding and possible to use of the Banteng bulls from different facilities for AI of females in all breeding facilities of Banteng.

AI applications require information on the estrous cycle and estrous signs to determine the precise AI time. Clinical signs of estrous in Banteng is difficult to observe, therefore determining the time of AI must be done through rectal palpation and ultrasonography. The objectives of this research is to assess estrous cycle to determine time of insemination.

MATERIALS AND METHODS

There were two females Banteng (*Bos javanicus*, d'Alton 1823) at Taman Safari Indonesia, Cisarua, Bogor used in this study. These Banteng were housed separately from the male with inter connecting door, therefore they can recognize each other although they were separated.

- Assessment of Oestrous Cycle

Female banteng was examined every 2 days per week. Examinations was conducted by rectal palpation and ultrasonography scanning of the reproductive organs focused on cervix, uterus and ovaries.

- Ultrasonography (USG)

USG was used to examine the female Banteng reproductive organs including the cervix, uterus dan ovary. Especially for ovarian examination was conducted to determine the growth and development of the follicles and corpus luteum during the period of the oestrous cycle.

The Exago® ver. 1.08 USG machine was used with a rectal linear probe of 5 MHz. The females Banteng were habituated to the application of rectal probe through rectal palpation in the service crate.

RESULT AND DISCUSSION

There was no significantly changed of the external reproductive organs estrous cycle such as vulval swelling and oestrous discharge observed during the oestrous cycles. Examination of the reproductive organs by rectal palpation could palpate the increase of uterine tone to become turgid significantly, therefore both uterus horns were easily grabbed like rubber tube and the bifurcation was very palpable. Transparent oestrous discharge was flowing out when the uterus was massaged. Oestrous in Banteng could be incidentally observed for indirect (tail rub; increased activity pattern) or overt (standing) evidence of oestrus [2].

Follicle growth and development were very

clearly seen through USG scanning when approaching the oestrous. Follicle was developed to dominant follicles up to 12-14 mm in diameter size when the females Banteng was in oestrous. On the other hand, there was seen accumulation of oestrous discharge also in the uterus clearly (Figure 1).

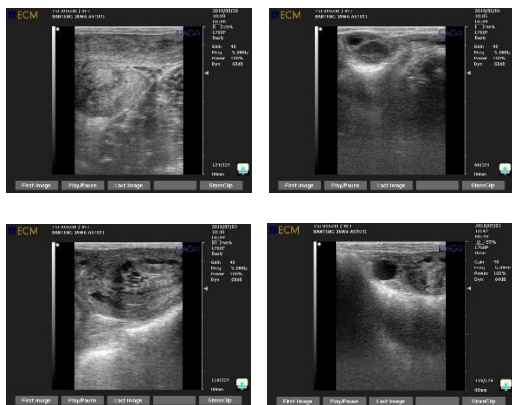


Figure 1 Ultrasonography images of (a) Uterus and (b) ovary are not in the estrous condition; (c) accumulation of oestrous discharge in the uterus and (d) dominant follicle during estrous

Cervical size was increased the length when estrous from 1.68 cm to 1.92 cm. The increase was due to a dilatation of the cervical rings, as shown in Figure 2.

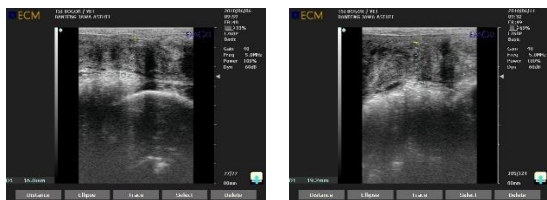


Figure 2 Increased cervical size when estrous

If the follicle size was about 12mm, USG procedure was conducted twice a day in the morning and the afternoon to follow the development of follicle size until ovulation was observed. The development of dominant follicles has been found to be a dynamic process in which large follicles appear on the surface of the ovary then regress and are replaced by other large follicles that will be ovulated [3].

According to the size of follicle observed during the oestrous, therefore AI was proceeded when the follicle size is about 13 mm. AI was conducted in the morning and afternoon consecutively if the follicle development was still observed. AI was stopped when the follicle was ovulated during the last USG observation

CONCLUSION

Estrous cycle in Banteng can't be assessed from the clinical signs of the changes of external reproductive organs. Oestrous in Banteng can be

determined only by rectal palpation examination and using an ultrasound to examine the increase of uterus turgidity and the size of dominant follicle, respectively. The right time of AI can be determined when the follicle size is about 13-14 mm.

ACKNOWLEDGMENTS

Thank you to the director and staff at Taman Safari Indonesia Cisarua Bogor (TSI) that facilitated and supported the research. Grateful to Mrs. Nani Maerani who has supported the smooth administration and logistic during research. Great thanks to ANBIOCORE, USAID SHERA for generous support to provide research funding and participation at the 20th FAVA Congress and Conferences in Bali.

REFERENCES

- [1] Gardner P, Hedges S, Pudiyatmoko S, Gray TNE, Timmins RJ. 2016. *Bos javanicus*. The IUCN Red List of Threatened Species. <http://dx.doi.org/10.2305/IUCN.UK.2016-2.RLTS.T2888A46362970.en>
- [2] Johnston SD, Mc Gowan MR, Blyde D. 2002. Birth of Banteng (*Bos javanicus*) calf at Western Plains Zoo after Fixed Time Artificial Insemination. *Aust Vet J*, Vol 80. Nos 1 and 2.
- [3] Kojima FN. 2003. Symposium paper: The Estrous Cycle in Cattle: Physiology, Endocrinology, and Follicular Waves. *The Professional Animal Scientist* 19 (2003): 83-95
- [4] Timmins, R.J.; Duckworth, J.W.; Hedges, S.; Steinmetz, R. & Pattanavibool, A. (2008). "*Bos javanicus*". IUCN Red List of Threatened Species. Version 2008. International Union for Conservation of Nature. Retrieved 29 March 2009. Database entry includes a brief justification of why this species is of endangered. https://en.wikipedia.org/wiki/IUCN_Red_List