

'Inverted Y' field radiotherapy planning with multi-leaf collimator: A single isocentric technique using multiple fields

Puja Sahai, Seema Sharma, Durai Manigandan, Bidhu Kalyan Mohanti

Department of Radiation Oncology, All India Institute of Medical Sciences, New Delhi, India

Received December 18, 2014; Revised February 11, 2015; Accepted April 09, 2015; Published Online April 26, 2015

Case report

Abstract

The purpose of our study is to describe a planning technique using multi-leaf collimator and asymmetric fields for irradiating an 'inverted Y' shaped geometry in a patient with testicular seminoma. The entire target area covering the para-aortic, pelvic, and inguinal nodal regions was split into three fields. Single isocenter half-beam block technique was employed. The fields were planned with antero-posterior and postero-anterior portals with a differential weightage. The dose was prescribed at the respective reference points of the fields. A uniform dose distribution for the entire portal was achieved without any under- or over-dosing at the field junctions.

Keywords: Inverted Y Field; Multi-leaf Collimator; Radiotherapy; Seminoma

Introduction

Before the era of the multi-leaf collimator (MLC), planning of 'Inverted Y' field radiotherapy comprised of shaping the field with customized blocks.¹ The field was often split into two with gap calculation.^{2, 3} Such planning raised concerns regarding the possibility of geographic misses and under- or over-dosed areas. The purpose of this study is to describe a planning technique using MLC and asymmetric fields for irradiating an 'inverted Y' shaped geometry in a patient with testicular seminoma.

Case presentation

A 41-year-old man diagnosed with right-sided testicular seminoma had presented with disease relapse in bilateral inguinal and right pelvic lymph nodes during post-orchietomy surveillance. 'Inverted Y' field radiotherapy was planned for him as a therapeutic measure. The patient was immobilized with a thermoplastic mold in the supine position. He was scanned on Brilliance Big Bore (85 cm) computed tomography (CT) simulator (Philips Medical Systems, Inc., Cleveland, OH, USA) from the level of the diaphragm to the level of mid-thigh with a slice thickness of 3 mm. The CT datasets were transferred to the Eclipse™ (version 6.5, Varian Medical Systems, Inc., Palo Alto, CA, USA) treatment planning system (TPS) through the DICOM network. Planning was performed with Eclipse™ TPS for CLINAC 2300C/D linear accelerator (Varian Medical Systems, Inc., Palo Alto, CA, USA). Both the kidneys were contoured on the CT images.

The field borders were defined with the aid of bony landmarks on the digitally reconstructed radiograph (DRR). The superior border was placed between T11 and T12 vertebral bodies. The inferior border was placed at the level of 1 cm below the ischial tuberosities so as to cover the lower extent of inguinal nodal volume as seen on the CT images. The lateral borders were placed at the tips of the lumbar transverse processes. At the mid-L4 level, the field was extended bilaterally. Laterally, the field was shaped with collimator leaves to spare iliac wing bone marrow without compromising the coverage of lymph nodal chain. Appropriate central shielding extending from the inferior edge of the field and superiorly up to the sacroiliac joint was incorporated to protect the bladder and the rectum. The collimator leaves were shaped manually to obtain the required coverage on the DRR.

The treatment area was split into two fields, i.e., upper and lower with the half-beam block technique **Figure 1**. The lower field was further divided into two with the collimator leaves. Matching of the two lower fields was performed with MLC and by placing the jaw manually to avoid any hot or cold spot at the junction. The upper field covered the para-aortic lymph nodal region. The 'right lower' field covered bilateral pelvic with the right inguinal region. The 'left lower' field covered the left inguinal with part of the left pelvic region. A single isocenter technique was employed with a dose prescription of 30 Gy in 15 fractions. The jaw position was fixed at the isocenter for all the fields.

Corresponding author: Puja Sahai; Department Radiation Oncology, All India Institute of Medical Sciences, New Delhi, India.

Cite this article as: Sahai P, Sharma S, Manigandan D, Mohanti BK. 'Inverted Y' field radiotherapy planning with multi-leaf collimator: A single isocentric technique using multiple fields. *Int J Cancer Ther Oncol* 2015; 3(2):3214. DOI: 10.14319/ijcto.32.14

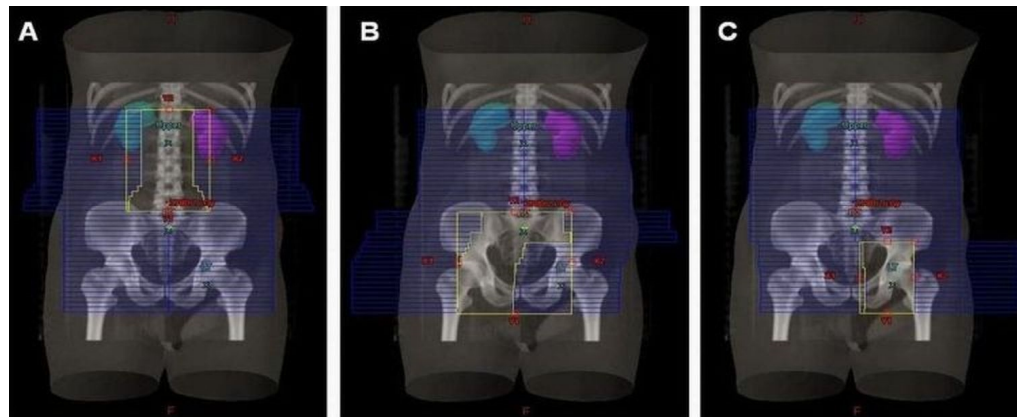


FIG.1: Anterior DRR of the fields: (A) upper (B) 'right lower' (C) 'left lower'.

The upper field was planned with antero-posterior (AP) and postero-anterior (PA) portals using 15 MV X-rays with a differential weightage of 0.8:1.0. Divergence from the lower field was blocked by keeping the lower jaw at the isocenter. The upper field plan was normalized to a reference point placed inside the field. The dose was prescribed at 95% isodose. The 'right lower' and 'left lower' fields were planned keeping the same isocenter using AP and PA portals. The energy of 6 MV and 15 MV X-rays was used for the AP and PA portals, respectively. A differential weightage of 0.55:1.0 was applied for the AP:PA portals. With reference to the 'right lower' field plan, the dose was prescribed at the reference point inside the field at 93% isodose. The dose for the 'left lower' field was prescribed at the respective reference point at 98% isodose. A gel bolus of 1 cm thickness was applied to AP portals of the lower fields to obtain adequate dose build-up at the inguinal nodal regions. Collimator angle was kept at 0 degree for all the fields. The whole plan was generated using source to axis distance (SAD) technique. Pencil beam dose calculation algorithm at 2.5 mm grid size was employed. The equivalent tissue air method was employed for the inhomogeneity correction. The three plans were summated to generate a final one.

The dose maximum for the upper field region was 109% (34.4 Gy). The dose maximum values for the right and the left lower plans were 109.2% (35.2 Gy) and 106.4% (32.6 Gy), respectively. No sharp peak or dip was observed at the TPS dose line profiles at the field junctions. The TPS dose color-wash illustrated a uniform dose distribution for the entire portal without any under- or over-dosing at the field junctions **Figure 2**.

Dose verification was performed by delivering the summated plan to a Kodak™ extended dose range (EDR2) film at a source to surface distance (SSD) of 95 cm. A solid water phantom slab of 5 cm thickness was placed above the film. A similar phantom slab of 10 cm thickness was placed below the film for backscatter. Prior to this, the film was calibrated by irradiating known doses ranging from 0.5 Gy to 4.0 Gy, and a calibration curve was drawn. The film was scanned and ana-

lyzed using OmniPro-1™mRT software (IBA Dosimetry, Scanditronix Wellhofer, Germany). The EDR2 film analysis based on the optical density calibration curve also demonstrated a uniform dose distribution **Figure 3**. Dose volume histogram showed mean dose to the right and the left kidney of 5.0 Gy and 2.1 Gy, respectively.

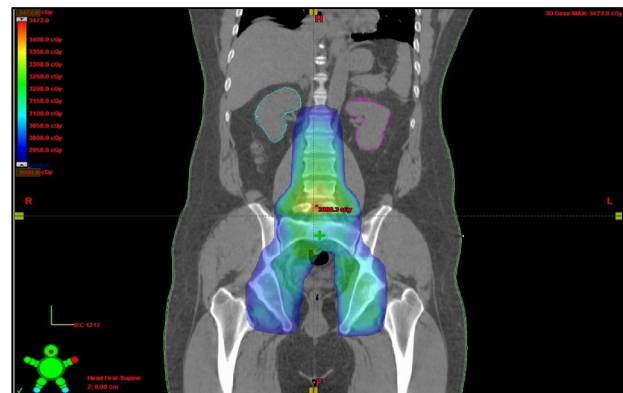


FIG.2: Coronal image shows summated dose distribution of the AP-PA portals of all the fields (96% of the prescription dose).

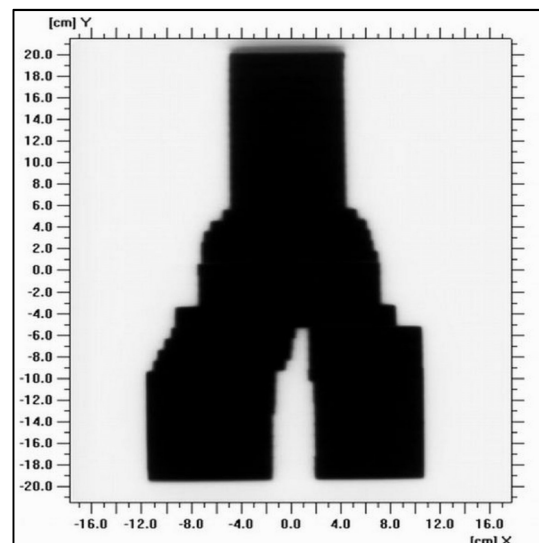


FIG. 3: Dose verification film (EDR2) of the 'inverted Y' radiation portal.

Discussion

Multiple asymmetric fields with separate plans for each one facilitates the attaining of a desired dose distribution for a large target volume. A single isocentric technique as described in the present study offers an advantage of a convenient and reproducible patient set-up. Classen *et al.*⁴ observed marginal misses when patients with testicular seminoma were treated with AP-PA fields based on bony anatomy. Blood vessels have been suggested as a surrogate for the conception of a nodal clinical target volume (CTV).⁵ Wilder *et al.*⁶ have described nodal CTV contouring for the different stages of testicular seminoma. Clinical and nodal mapping studies substantiate the shift of superior border of the para-aortic field from the upper border of T11 to that of T12. The lowering of superior border reduces doses to kidney, stomach, and bowel.

Birgani *et al.*⁷ described a method with couch and gantry rotation for the radiation treatment of adjacent fields. The dose inhomogeneity was limited to 2% across the field junction. The design and fabrication of a prototype gonadal shield for 'inverted Y' field radiotherapy has been described by Ravichandran *et al.*⁸ The dose received by the testis was measured to be 0.8% of the prescribed dose with the use of the shield.

The para-aortic field planning with intensity modulated radiation therapy (IMRT) has been reported by Zilli *et al.*⁹ The volume irradiated to 100% and 50% of the prescribed dose (V100 and V50) for bone marrow, small and large bowel, stomach, pancreas, and liver were reduced with IMRT as compared with CT-based AP-PA fields. However, the mean dose and D50 for kidneys, liver, and bowel were lower with AP-PA fields in contrast to 7-field IMRT. The increase in number of monitor units and volume of normal tissues irradiated to low dose radiation tend to increase the risk of second malignancies with IMRT.¹⁰ Therefore, AP-PA portals remain the most commonly employed planning approach for para-aortic irradiation in patients with testicular seminoma.

Our case study described a method of CT-based planning with the aid of DRR and MLC. A combined radiation portal for treating the entire nodal risk volume consisting of para-aortic, pelvic, and inguinal regions was generated with a homogeneous dose distribution.

Conflict of interest

The authors declare that they have no conflicts of interest. The authors alone are responsible for the content and writing of the paper.

References

1. Nautiyal J, Weichselbaum RR, Vijayakumar S. Radiation therapy techniques in the treatment of Hodgkin's disease. *Semin Radiat Oncol* 1996; **6**:172-184.
2. Prosnitz LR, Brizel DM, Light KL. Radiation techniques for the treatment of Hodgkin's disease with combined modality therapy or radiation alone. *Int J Radiat Oncol Biol Phys* 1997; **39**:885-95.
3. Kumar PP, Good RR, Jones EO, *et al.* Extended-field isocentric irradiation for Hodgkin's disease. *J Natl Med Assoc* 1987; **79**:969-80.
4. Classen J, Schmidberger H, Meisner C, *et al.* Para-aortic irradiation for stage I testicular seminoma: results of a prospective study in 675 patients. A trial of the German testicular cancer study group (GTCSG). *Br J Cancer* 2004; **90**:2305-11.
5. Taylor A, Rockall AG, Reznick RH, Powell ME. Mapping pelvic lymph nodes: guidelines for delineation in intensity-modulated radiotherapy. *Int J Radiat Oncol Biol Phys* 2005; **63**:1604-12.
6. Wilder RB, Buyyounouski MK, Efstathiou JA, Beard CJ. Radiotherapy treatment planning for testicular seminoma. *Int J Radiat Oncol Biol Phys* 2012; **83**:e445-52.
7. Birgani MJT, Ansari M, Behrooz MA. A new method for ideal dose distribution of two adjacent fields for external beam radiation therapy. *Med J Islam Repub Iran* 2007; **20**:192-7.
8. Ravichandran R, Binukumar JP, Kannadhasan S, *et al.* Testicular shield for para-aortic radiotherapy and estimation of gonad doses. *J Med Phys* 2008; **33**:158-61.
9. Zilli T, Boudreau C, Doucet R, *et al.* Bone marrow-sparing intensity-modulated radiation therapy for Stage I seminoma. *Acta Oncol* 2011; **50**:555-62.
10. Hall EJ, Wu CS. Radiation-induced second cancers: the impact of 3D-CRT and IMRT. *Int J Radiat Oncol Biol Phys* 2003; **56**:83-8.