

A case of endometrial carcinoma with age related hyperkyphosis treated with definitive radiotherapy

Arvind S Murthy, Janaki G Manur, Arul TR Ponni, Kirthi AS Koushik, Ram C Alva, Mohan K Somashekar, Ram A Kannan, Ritika R Harjani

Department of Radiation Oncology, M S Ramaiah Medical College, Bangalore, India

Received September 15, 2014; Revised December 10, 2014; Accepted December 11, 2014; Published Online December 14, 2014

Case Report

Abstract

This report describes a simple brachytherapy procedure in a patient with endometrial cancer with age related hyperkyphosis. Sixty-eight year-old postmenopausal woman with age related hyperkyphosis presented with endometrial carcinoma, and the patient was not operated on due to associated pelvic deformity. The patient received whole pelvic radiation followed by uterovaginal brachytherapy. Patient was supported with soft pillows to support her exaggerated anterior concavity during brachytherapy procedure and execution. The brachytherapy dose was 6 Gy per fraction per week for 3 weeks using image guidance. This is probably the first reported case of endometrial cancer with age related hyperkyphosis. In spite of the associated skeletal problems, a simple brachytherapy procedure is possible and provides good result.

Keywords: Brachytherapy; Endometrial Cancer; Hyperkyphosis

Introduction

Endometrial cancer is the most common female genital malignancy worldwide.¹ In India it is the 2nd most common female genital tract malignancy.² Surgery in the form of total abdominal hysterectomy, salpingo oophorectomy with or without pelvic lymph node dissection is the standard treatment for endometrial carcinoma. Radiotherapy, either external or in the form of brachytherapy, is usually used in adjuvant setting. In a selected few medically unfit patients, who have uncontrolled diabetes, hypertension, or morbid obesity, constituting around 10% of the cases, radical radiotherapy can be considered. We are hereby presenting one such case of endometrial carcinoma that could not be operated due to kyphosis, hence treated with radical radiotherapy.

Case history

A Sixty-eight year-old postmenopausal lady with fair performance status presented with history of bleeding PV of two months duration. She was initially evaluated with a colposcopy, which revealed an ulcerated ectocervix, histopathologically consistent with chronic cervicitis. The patient was further subjected to a dilatation and curettage; the histopathology was suggestive of well-differentiated adenocarcinoma.

The patient was further evaluated with an Magnetic Resonance Imaging (MRI) of abdomen and pelvis which revealed

bulky uterus with T2 heterogeneously enhancing hyper intense lesion in the endometrium measuring 48 mm × 26 mm × 42 mm (Figure 1).

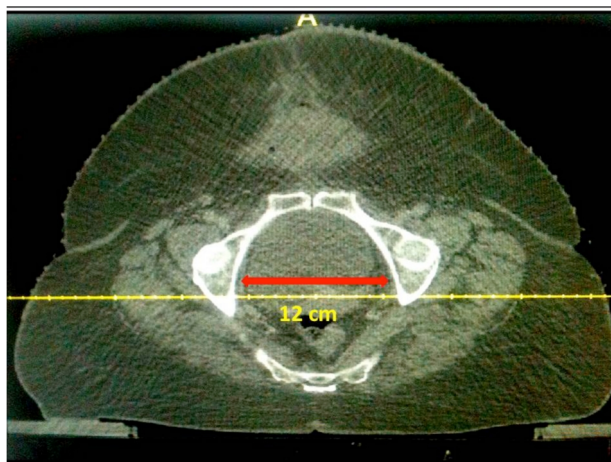


FIG.1: CT scan pelvis showing small pelvis (the transverse diameter being 12 cm versus normal 13.5 cm).

Junction between lesion and endometrium was poorly maintained and a lymph node measuring 12 mm in the left parametrium was detected. There was no evidence of cervical involvement.

Subsequently a complete metastatic workup was done, which was negative. The patient was then posted for total

abdominal hysterectomy with bilateral salpingo-oophorectomy with pelvic lymph node dissection. Due to anatomical complications, mainly age related osteoporotic hyperkyphosis (**Figure 2**) and an inaccessibly cramped pelvis, the procedure could not be performed. Following this, a tumor board meeting was conducted and a consensus for radical radiation therapy was arrived at.

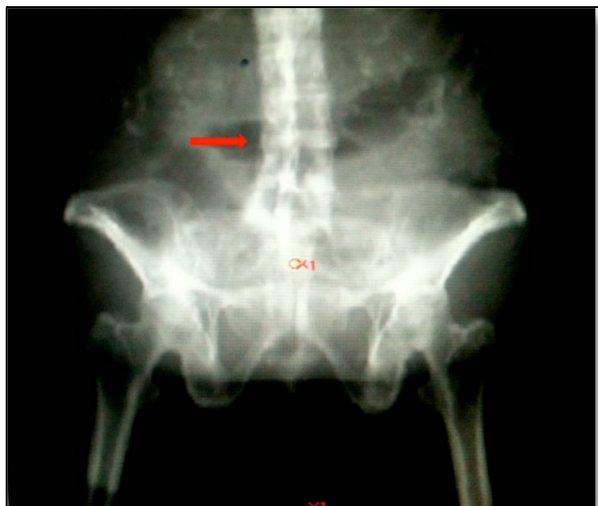

FIG 2: X ray pelvis showing associated lumbar deformity.

External beam radiotherapy

In her pre radiation assessment, the patient had hip flexion deformity as a result of her aforementioned condition, due to which the patient was unable to lie down in supine position for prolonged periods of time. Pelvic immobilization was done using aquaplast cast and knee rest. The CT based simulation planning was done, with 3 mm cuts using 80 ml of intravenous contrast. The contouring and planning were done on Prowess Panther version 4.71 (Prowess Inc.1844 Clayton Road, Concord, California, USA). The volumes for external radiation included the entire uterus and the vagina as the primary volume, whereas bilateral parametrial and pelvic lymph nodes up to the bifurcation of aorta were included as the nodal volume.

External beam radiotherapy was delivered to a dose of 5040 cGy in 28 fractions, 5 fractions/week, using 3D-CRT technique on 6 MV linear accelerator. The treatment was delivered using 4 beams and an additional field-in-field for the posterior beam to reduce the high dose region (**Figures 3 and 4**). The total monitor units (MUs) per fraction were 460. The total treatment time including setup was approximately 10-15 minutes every day.

Brachytherapy

Following external beam radiation, the patient was planned for high dose rate (HDR) brachytherapy. Due to the aforementioned problems, we had to take additional measures to maximize patient comfort by using soft supports for the neck

and thorax during the applicator placement, CT simulation and also during brachytherapy execution. The CT simulation was done with 3 mm cuts with institutional protocol of 50 ml of bladder contrast and 20 ml of rectal contrast. The planning was done on HDR plus version 3.0.4 (Eckert & Ziegler BEBIG GmbH, Berlin, Germany). Per American Brachytherapy Society recommendation, High Risk Clinical Target Volume (the target-HRCTV) included the entire uterine wall along with the cervix and the upper third of the vagina.³

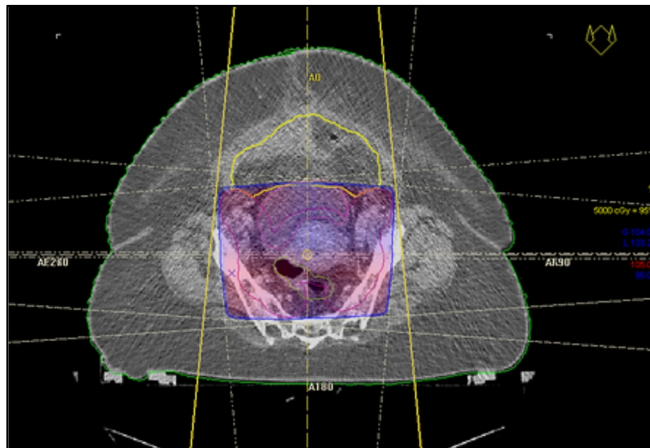


FIG. 3: External beam radiotherapy dose distribution - Axial.

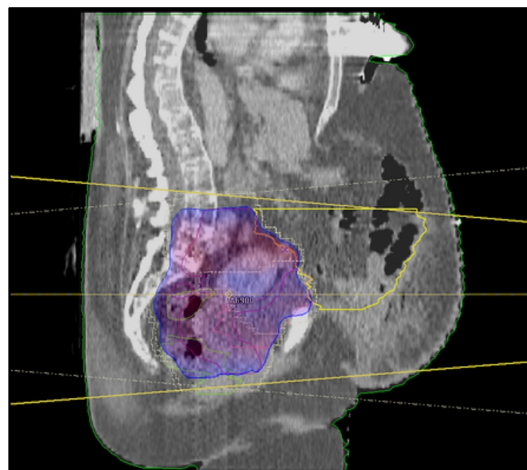


FIG. 4: External beam radiotherapy dose distribution - Sagittal.

The total volume of the HRCTV was 62.93 cc. As the pre-treatment MRI did not show any evidence of cervical involvement, a single uterovaginal source without ovoids was used. The active length of the tandem was 7 cm and the diameter of the cylinder was 3 cm. The optimization was done at 3.2 cm at the level of tumour. At the level of bladder and rectum, optimization was done at 2.2 cm in order to reduce the dose to these structures. Hence, the prescribed dose of 6 Gy covered 96.4% of the target (**Figure 5**) while 2 cc of bladder and rectum received 5 Gy and 2.2 Gy, respectively (**Figures 6 and 7**). Brachytherapy was delivered using a

remote after loading HDR unit using Co-60 source of activity 73.34 GBq, to a dose of 6 Gy/fraction prescribed to the HRCTV (target in the **Figure 8**). Three such fractions were

given once per week over three weeks to a total dose of 18 Gy to the target.

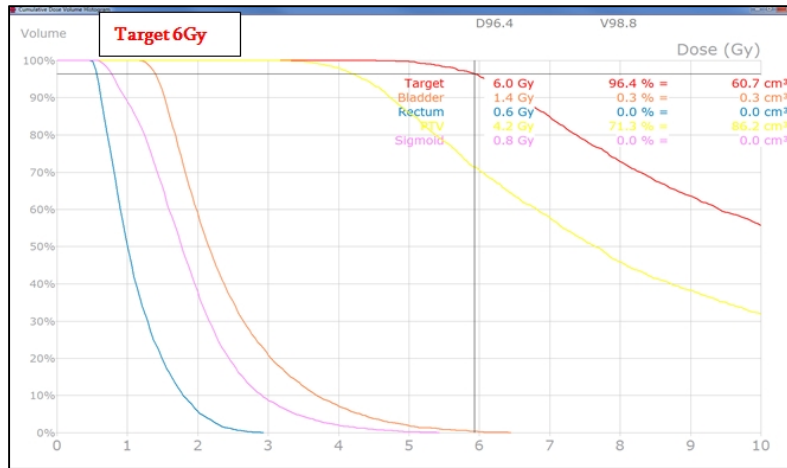


FIG. 5: DVH representing 6 Gy volume coverage. [PTV for reference in yellow]

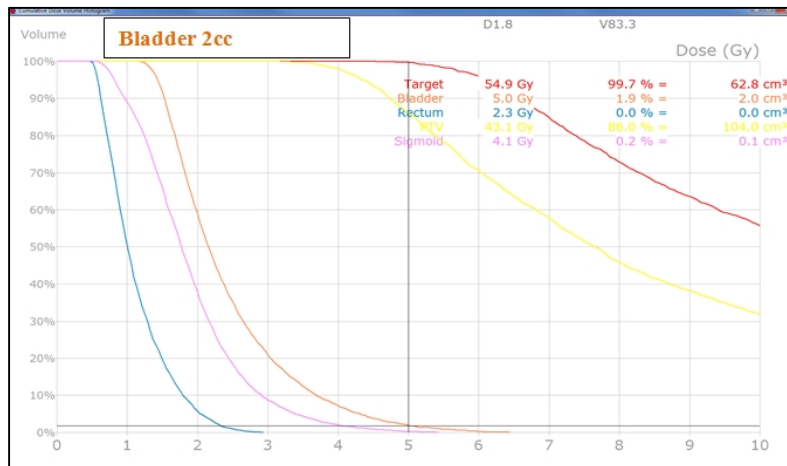


FIG. 6: DVH representing dose received by bladder 2 cc. [PTV for reference in yellow]

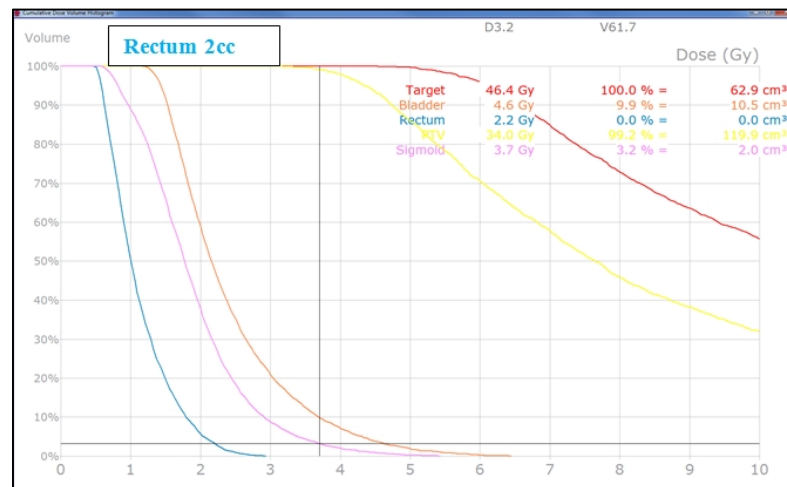


FIG. 7: DVH representing dose received by 2 cc of rectum. [PTV for reference in yellow]

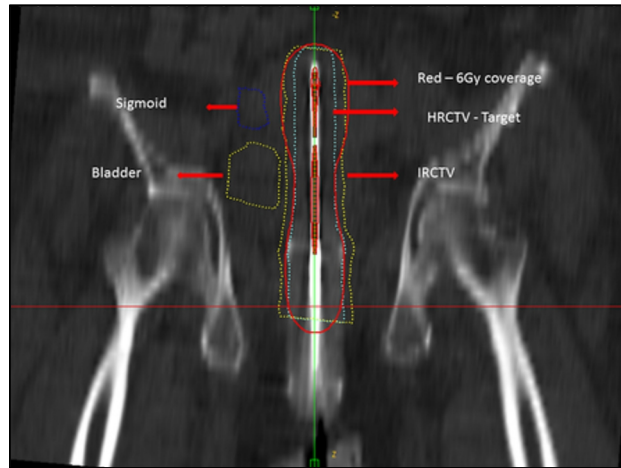


FIG. 8: Coronal view of target coverage (brachytherapy)

In lieu of the fixed geometry and since vaginal packing was not done, a CT simulation was done only before the first fraction. Subsequent fractions were delivered with the same plan, with correction factors applied for the calculation of the decay of the isotope in order to get accurate treatment time.

Results and Discussion

At 6 months post treatment, the patient is on regular follow up and there is no evidence of loco regional disease. Follow up MRI revealed a reduction in the thickness of endometrium from 26 to 8 mm and complete disappearance of parametrial lymph node.

A pipelle aspiration on 6 months follow up was a dry tap, suggestive of locally controlled disease.

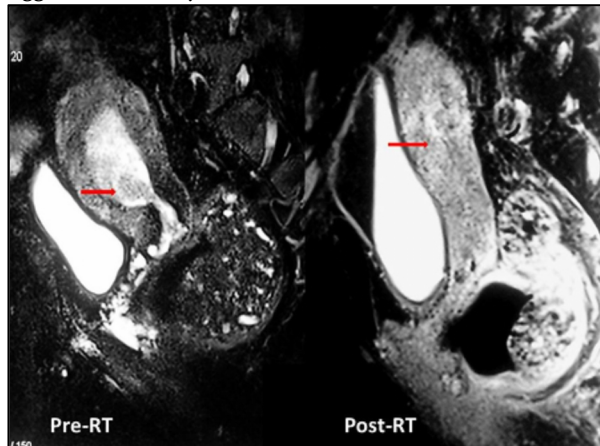


FIG. 9: MRI pre and post RT.

Definitive radiotherapy of technically operable but medically inoperable endometrial cancer depends on the stage of the disease. Stage I and II patients can be treated with brachytherapy alone. All other patients are treated with combined external beam and brachytherapy. Since there was a pelvic node of 1.2 cm on MRI, we treated our patient with com-

bined external radiation and brachytherapy.

With the advent of Intensity modulated radiation therapy (IMRT) and volumetric modulated arc therapy (VMAT), it is potentially possible to reduce the volume of normal tissues in the irradiated field, thereby reducing the risk of acute and chronic radiation sequelae. However, at our institution at the time of treatment of this patient, only step and shoot IMRT was available. The treatment time for pelvic irradiation with step and shoot IMRT ranged from 30-45 minutes. Due to skeletal deformity and morbid obesity, our patient was not able to lie down in supine position for prolonged periods of time; hence we went ahead and treated the patient with Three Dimensional conformal radiotherapy technique (3D-CRT).

Lin *et al.*⁴ studied the impact of body mass index (BMI) on the systematic setup errors in patients treated with adjuvant radiotherapy for endometrial cancer. They found that with increasing body mass index, the systematic setup errors also increased from 3 mm to 5.6 mm in lateral direction for normal and obese individuals respectively; 2.6 mm to 6.2 mm in the longitudinal direction and 3 mm to 5 mm in the vertical direction. Also, they applied the van Herk equation⁵ for calculating margins based on BMI for normal and obese individuals. They found that for morbidly obese individuals vis a vis normal weight individuals, the margins required were 7 mm versus 13.9 mm in the vertical; 5.3 mm versus 15.6 mm in the longitudinal and 6.3 versus 14.9 mm in the lateral directions. This in essence precludes the dosimetric advantages of IMRT. Hence, in a morbidly obese patient like ours, use of IMRT may not be of much additional benefit.

Tamim *et al.*⁶ have treated 30 patients of stage I and II with HDR brachytherapy alone to a dose of 23.9 Gy in three fractions over three weeks prescribing at 2 cm from the central axis of the tandem. A long term follow up of 15 years showed disease specific survival (DSS) of 91% and 42 % for stage I and II respectively.

Nguyen *et al.*⁷ have treated 36 similar patients with a dose of 45 Gy in five weekly fractions and they observed three year DSS of 85%. They also noted that the late rectal and bowel complications were seen in 21% of patients and attributed it to the higher dose that was used. A case controlled study by Peter *et al.*⁸ of Stage I and II patients treated by primary radiation therapy matched to surgically treated controls showed no statistical difference in survival.

Churn *et al.*⁹ have treated 37 patients with a combination of external beam radiotherapy and intracavitary brachytherapy using a single line source technique and observed a 5-year disease-specific survival of 68.4% for Stages I and II and 33.3% for Stages III and IV. The important factor was that, each patient's dose prescription points were based not only on the length, but also on the bulk of the disease and individual anatomy.

Age-related postural hyperkyphosis is an exaggerated anterior curvature of the thoracic spine, sometimes referred to as Dowager's hump or gibbous deformity. This condition impairs mobility, and increases the risk of falls and fractures. As kyphosis increases, there are concomitant alterations in the normal sagittal plane alignment like flexion deformity of the pelvic girdle.¹⁰ To our knowledge, our patient is the first reported case of age related osteoporotic hyper kyphosis with fixed flexion deformity of the pelvis making the patient inoperable.

Historically brachytherapy for inoperable cancer endometrium has been carried out with various techniques such as Heyman's capsule, a rigid tandem, a biconcave butterfly applicator or even a regular intracavitary application prescribing to point A. Each of these has its own advantages and limitations.¹¹ An ideal applicator for inoperable endometrial cancer, consists of dual tandem placed in each cornu of the uterus, which provides optimal distribution at the fundus.³ Due to non-availability of the dual tandem, we used single uterovaginal source and since the locoregional recurrence following surgery for endometrial cancer is around 14% and two thirds of these are seen in the vagina¹² the upper part of the vagina was also treated.

The advantage of single uterovaginal source is that the procedure can be simple and completed fast, especially in patients like ours, who are unable to lie supine for long periods of time due to pelvic deformity.

Follow up includes MRI based assessment as well as check curettage. Follow up MRI at 6 months of treatment revealed a good regression of the disease, a reduction in endometrial thickness down to 8 mm compared to 26 mm before treatment and a complete resolution in the size of the pelvic lymphnode. Rose *et al.*¹³ have performed a D & C at 6 months of radiotherapy and residual disease was seen in 2/27 patients. However, the study period was 1974-1992 and

probably an MRI in the present time would have been an ideal follow-up investigation.

We subjected our patient to pipelle aspiration which turned out to be dry and hence a regular follow up is planned. A Pipelle is a plastic flexible tube with a piston inside and works on the principle of suction. It can be inserted into the uterine canal without any dilatation and hence can be done along with routine gynecological examination. In a study by Ibrahim *et al.*¹⁴, pipelle was followed by routine D and C in patients with abnormal uterine bleeding and the results were compared. The sample obtained was adequate in 97.9% of patients and opined that it can replace conventional D and C in patients who have an endometrial thickness of more than 5 mm. They also noticed 100% sensitivity, specificity and predictive value for both endometrial hyperplasia as well as for endometrial cancer.

Limitation

An MRI scan post external radiotherapy would have provided the differential quantification of disease response after external radiation alone when compared with external radiation plus brachytherapy.

Conclusion

For medically inoperable endometrial cancer patients, definitive radiation therapy is a viable alternative. Single uterovaginal brachytherapy technique not only delivers the required dose to the disease, but also is easy for patients who cannot lie in supine position for prolonged periods of time due to skeletal deformity.

Conflict of interest

The authors declare that they have no conflicts of interest. The authors alone are responsible for the content and writing of the paper.

References

1. Colombo N, Preti E, Landoni F, et al. Endometrial cancer: ESMO Clinical Practice Guidelines for diagnosis, treatment and follow-up. *Ann Oncol* 2011; **22 Suppl 6**: 35-9.
2. Salhan S, Singh P, Miglani U. Textbook of Gynecology. New Delhi, India: Jaypee Brothers Medical Publishers Pvt Ltd; 2011.
3. Nag S, Erickson B, Parikh S, *et al.* The American Brachytherapy Society recommendations for high-dose-rate brachytherapy for carcinoma of the endometrium. *Int J Radiat Oncol Biol Phys* 2000; **48**:779-90.

4. Lin LL, Hertan L, Rengan R, Teo BK. Effect of body mass index on magnitude of setup errors in patients treated with adjuvant radiotherapy for endometrial cancer with daily image guidance. *Int J Radiat Oncol Biol Phys* 2012; **83**:670-5.
5. van Herk M, Bruce A, Kroes AP, et al. Quantification of organ motion during conformal radiotherapy of the prostate by three dimensional image registration. *Int J Radiat Oncol Biol Phys* 1995; **33**:1311-20.
6. Niazi TM, Souhami L, Portelance L, et al. Long-term results of high-dose-rate brachytherapy in the primary treatment of medically inoperable stage I-II endometrial carcinoma. *Int J Radiat Oncol Biol Phys* 2005; **63**:1108-13.
7. Nguyen C, Souhami L, Roman TN, Clark BG. High-dose-rate brachytherapy as the primary treatment of medically inoperable stage I-II endometrial carcinoma. *Gynecol Oncol* 1995; **59**:370-5.
8. Rose PG, Baker S, Kern M, et al. Primary radiation therapy for endometrial carcinoma: a case controlled study. *Int J Radiat Oncol Biol Phys* 1993; **27**:585-90.
9. Churn M, Jones B. Primary radiotherapy for carcinoma of the endometrium using external beam radiotherapy and single line source brachytherapy. *Clin Oncol (R Coll Radiol)* 1999; **11**:255-62.
10. Katzman WB, Wanek L, Shepherd JA, Sellmeyer DE. Age-related hyperkyphosis: its causes, consequences, and management. *J Orthop Sports Phys Ther* 2010; **40**:352-60.
11. Creutzberg CL, Nout RA. The role of radiotherapy in endometrial cancer: current evidence and trends. *Curr Oncol Rep* 2011; **13**:472-8.
12. van der Steen-Banasik E. Primary brachytherapy as a radical treatment for endometrial carcinoma. *J Contemp Brachytherapy* 2014; **6**:106-12.
13. Rose PG. Endometrial carcinoma. *N Engl J Med* 1996; **335**:640-9.
14. Abdelazim IA, Aboelezz A, Abdulkareem AF. Pipelle endometrial sampling versus conventional dilatation & curettage in patients with abnormal uterine bleeding. *J Turk Ger Gynecol Assoc* 2013; **14**:1-5.