

# Autologous fat transfer as prostate-rectal spacer: Technique description and early results

Marcelo Borghi<sup>1</sup>, Luis Montes de Oca<sup>1</sup>, Edgardo Becher<sup>1</sup>, Marcelo Bou<sup>1</sup>, Lijia Elizabeth Aviles<sup>2</sup>,  
Maria Luisa Filomia<sup>2</sup>, Jorge Chiozza<sup>2</sup>

<sup>1</sup>Department of Urology, Centro de Urología – CDU, Buenos Aires, Argentina

<sup>2</sup>Department of Radiation Oncology, Vidt Centro Médico-21<sup>st</sup> Century Oncology, Buenos Aires, Argentina

Received April 05, 2016; Revised August 18, 2016; Accepted August 20, 2016; Published Online September 18, 2016

## Technical Report

### Abstract

**Purpose:** Several attempts have been made to increase the distance between the prostate and the rectum through injection of different synthetic compounds, generating space between organs. To report an original technique to increase the distance between the rectum and the prostate, by autologous fat implantation into the rectoprostatic space, with the aim of providing physical dosimetry protection and rectal dose sparing. **Methods:** We prospectively evaluated twelve patients subjected to autologous fat implantation as recto-prostatic spacer subsequently receiving prostate either radical (n = 6), or salvage brachytherapy for local recurrence after external beam radiation therapy (EBRT) (n = 6). Standard permanent prostate brachytherapy seed implantation was performed through transperineal approach and under transrectal ultrasonography (TRUS) and template guidance. Prescribed D90 dose for Iodine - 125 monotherapy was 140 - 160 Gy, reduced by 30% for rescue cases to obtain a Rectum V100 under 1 cc. **Results:** Lipo-transfer was completed in all 12 patients. Control CT scan at 1 month showed average distances of: 10.7 mm (range) (2.8 - 15.9 mm), 7.6 (1.8 - 11.6 mm) and 6.8 (4.2 - 8.3) mm at prostate base, middle and apex, respectively. Shortest separation distance observed was at apex and midline, while largest was observed the sides and at seminal vesicles level. Control CT at 3 months showed average distances of 9.6 mm (1.9 - 14.6 mm), 6.3 mm (1.8 - 10.2 mm) and 5.4 mm (3.8 - 7.2 mm) at prostate base, middle and apex, respectively. Most complications were minor. **Conclusion:** Autologous fat transfer is a feasible and simple procedure for experienced practitioners with low complication rates, which allows dose escalation to the prostate.

**Keywords:** Autologous fat transfer, brachytherapy, recto-prostatic spacer

## 1. Introduction

Several phase III studies have now demonstrated consistent improvement in tumor control using radiation dose escalation. Increasing total radiation dose augments risk of side effects, unless volume of normal tissue treated along with the tumor can be reduced.<sup>1,2</sup>

Direct link between dose and acute or chronic rectal toxicity during prostate radiation treatment has been well established.<sup>3,4,5</sup>

Many attempts have been made to increase the distance between the prostate and the rectum through injection of different synthetic compounds generating a space

between both organs. Substances introduced must remain stable during radiotherapy application.<sup>6,7,8</sup> Use of materials has proven effective in reducing total radiation dose to the rectum while minimizing toxicity.<sup>9</sup>

Our group has developed a technique to increase the distance between the rectum and the prostate, by autologous fat implantation into the rectoprostatic space, with the aim of providing physical dosimetry protection and rectal dose sparing.

The objective of this study is to describe the technical feasibility of autologous fat implant as a prostatic rectal spacer and our early results in patients undergoing low

**Corresponding author:** Lijia Elizabeth Aviles; Department of Radiation Oncology, Vidt Centro Médico, Buenos Aires, Argentina.

**Cite this article as:** Borghi M, Montes de Oca L, Becher E, Bou M, Aviles LE, Filomia ML, Chiozza JO. Autologous fat transfer as prostate-rectal spacer: Technique description and early results. *Int J Cancer Ther Oncol.* 2016; 4(3):4316. DOI: 10.14319/ijcto.43.16

dose rate prostate brachytherapy either for primary or salvage treatment.

## 2. Methods and Materials

We prospectively evaluated twelve patients who underwent autologous fat implantation a prostatic-rectal spacer to receive prostate brachytherapy either as radical (n = 6), or salvage treatment for local recurrence after external beam radiation therapy (EBRT) (n = 6). All patients signed specific informed consent forms previously approved by the institutional review board.

### 2.1. Technique

First, standard permanent seed prostate brachytherapy implantation was performed through transperineal approach under transrectal ultrasonography (TRUS) and template guidance. High-resolution biplanar ultrasound with dedicated prostate brachytherapy software was used together with fluoroscopy monitoring of seed deposition. After loading of stranded seeds, D90 prescription dose used for Iodine-125 monotherapy was 140 - 160 Gy, and reduced by 30% for salvage cases, The goal was to obtain Rectum V100 under 1 cc.<sup>10</sup>

Fat extraction and processing was conducted by a plastic surgeon experienced in lipo-transfer, and radioactive seed and fat implants by an urologist with extensive experience in brachytherapy techniques. Dosimetry and plan approval was supervised by a radiation oncologist. The procedure applied for lipo transfer consists of the following steps, originally described by Coleman.<sup>11</sup>

#### 2.1.1. Infiltration of donor fat

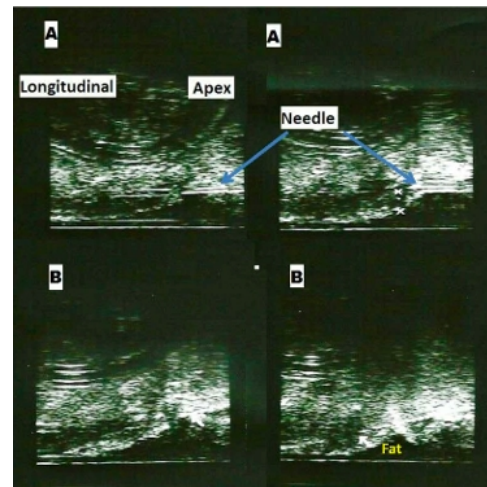
Periumbilical subcutaneous cellular tissue is infiltrated with 1 mg of adrenaline diluted in 500 ml of saline. Infiltration plane is the same as the one followed during abdominal liposuction, in which a syringe or infiltration pump may be used, with multi-perforated Klein needles attached. Twenty minutes are necessary for vasoconstrictive effects to occur. A 10 cc Luer-Lok syringe is then used for fat aspiration at a negative pressure of 50 to 115 mm Hg, in order not to damage fat cells, filling a 3 mm cannula. The material is then allowed to decant, and supernatant removed after ten minutes. Syringe contents are centrifuged at 1000 rpm for three minutes; this time is brief and the speed low in order to allow adipocyte concentration and separation from the remaining Klein solution only.

Eighty ccs of subcutaneous abdominal fat need to be harvested, to generate 30 cc of finely processed fat.<sup>11</sup>

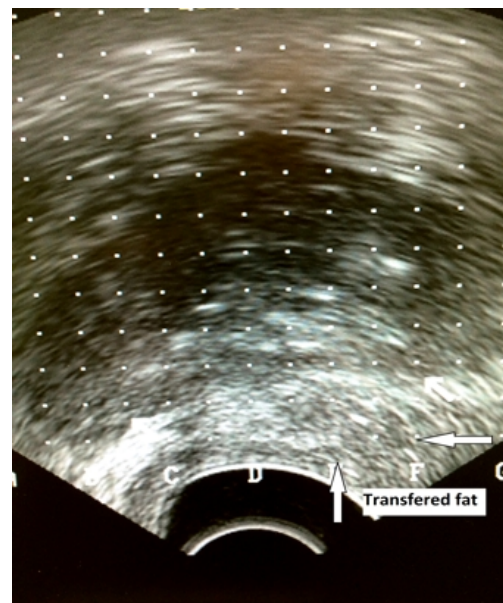
#### 2.1.2. Fat transfer

Once brachytherapy is completed, the transrectal transducer is pushed down as far as possible in the dorsal direction, in order avoid compression of the rectum against the prostate. A Foley catheter is left in

place to identify the midline. One cc of saline or sterile gel should be introduced into the tip of the Denonvilliers fascia to generate a welt using an 18 G brachytherapy needle under physical placement grid guidance (Figure 1A). This will create a window and make placement of the 3 mm placement needle easier, a step which can be avoided if necessary. However, much better visualization is obtained creating a gel or water welt. Water is easy to inject, but remain for less time than gel, which may be harder to introduce, but persist for longer. Dissection of Denonvilliers fascia is very simple in primary cases, but may be more difficult in salvage cases, for which gel or water dissection is recommended first.<sup>11</sup>



**Figure 1:** A: Dissecting Denonvilliers fascia with water using a standard 18 gauge needle. B: fat transfer with dedicated 3 mm needle.

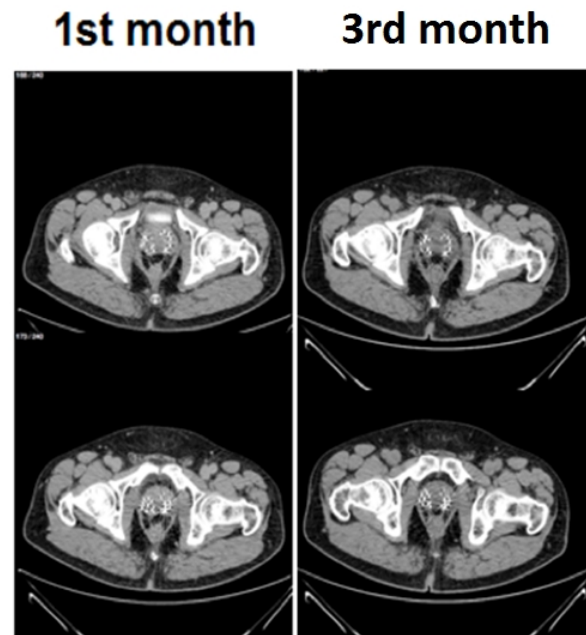


**Figure 2:** Final axial US view of transferred fat and increased prostate-rectum distance on the left side.

The brachytherapy grid is then removed, and the perineal area scrubbed with an antiseptic, the transducer is isolated and a 3 mm incision is made along the midline, at 10 mm from the anal verge. The transfer needle is then introduced freehand, parallel to the transducer and connected to a fat-loaded 10 cc Luer-Lok syringe, tightly screwed and purged.<sup>11</sup>

Great care should be taken not to injure the rectum, should this occur the procedure must be terminated immediately. Needle entry port is through the welt created by prior injection of gel or water. Small amounts of fat are introduced (1 ml), with the needle opening facing either the rectum or the prostate, while advancing 5 to 10 mm proximally, constantly rotating the needle between 12 and 6 o'clock (Figure 1B).

This will generate small lakes of fat that will maximize posterior nutrition. Notice this concept is the opposite of the procedure described by Coleman, who recommended distal to proximal injection of small volumes. However, in cases of salvage brachytherapy the Denonvilliers fascia may be more adherent, therefore, distal to proximal dissection and fat injection is better for these cases. Semi-liquid fat is isoechoic, and care is required as natural planes of dissection may be lost, making spaces generated hard to visualize, particularly the Denonvilliers fascia.



**Figure 3:** 1st and 3rd month CT Scan in a case of primary brachytherapy. Prostate-rectum distance remained the same at 3 months. Note, 3 separate small lakes: at midline and on both sides.

Once midline injection is completed, the needle is drawn back and redirected towards one side. The parallel position between the needle and the longitudinal transducer crystal is lost; therefore, transducer should be used to monitor needle tip displacement control both

rectum location as well as fat injection site. Along the sides, the Coleman technique of distal to proximal injection may be followed, advancing the needle after each injection, always rotating in order to generate small fat welts. Once one side is completed, the procedure is repeated on the opposite side.<sup>11</sup>

It is important to alternate between ultrasound planes (longitudinal to axial) to better control the procedure (Figure 2). We have always attempted to generate a distance of at least 10 mm between the prostate and the rectum. Ciprofloxacin is administered for antibiotic prophylaxis.

Control CT scan is obtained in all patients one and three months post procedure in order to measure the distance between the rectum and prostate at the base, midsection, and apex.

### 3. Results

Lipo-transfer was completed in all 12 patients. Six were primary cases and six salvage brachytherapy cases. In the rescue cases, a 30 ml fat implant was conducted only on the positive biopsy side (Figure 4). In standard brachytherapy cases, 40 ml were placed bilaterally (20 ml on each side).

Two patients referred perineal heaviness but did not require medication (Clavien 1). No patients referred lower bowel dysfunction.

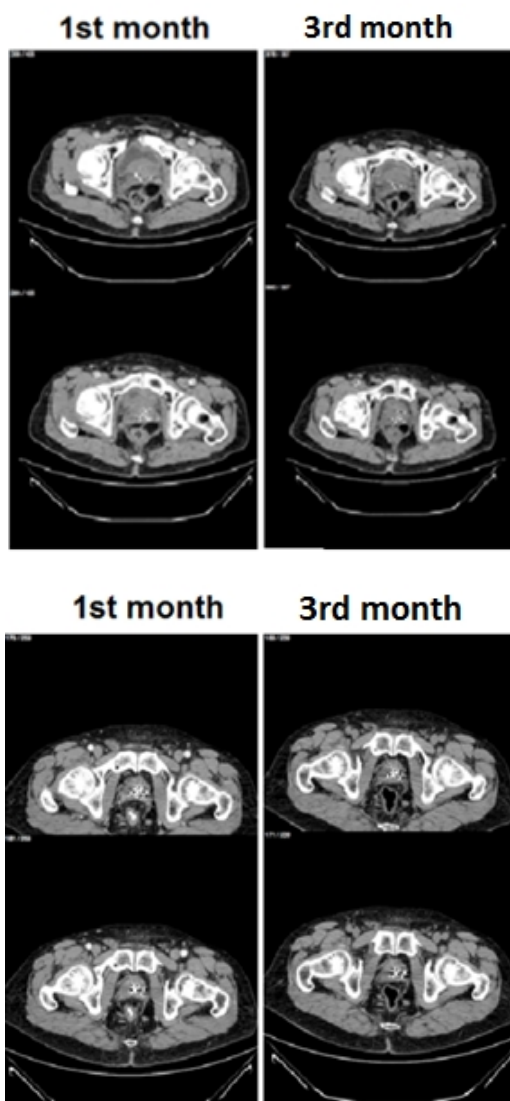
### 4. Discussion

Incidence of actinic proctitis after prostate treatment is 5 - 20% according to the published series.<sup>3,4,5</sup> Currently, in the era of modern radiation therapy modalities such as three-dimensional conformal, intensity modulated and image- guided radiotherapy technique this figure has dropped to 1 - 3.8%<sup>12,13</sup> because of decreased rectal exposure. In cases of local recurrence (LR) after EBRT, rectal complication rates rise considerably (3 - 47%) and become potentially severe and difficult to manage.<sup>13</sup> Dose-volume histograms have been studied extensively, and the nature and timing of the radiation dose analyzed to provide safe maximum dosing to the cancerous prostate, while minimizing risk of late uncommon rectal complications after primary EBRT or brachytherapy treatment. Dose constraints after EBRT rectum D75 are < 5%, and D50 are < 20%. Similarly, for rectal dosimetry in brachytherapy the RV100 is ideally < 1 cc.<sup>2,10</sup>

However, rectal proximity to higher isodose lines makes it very difficult to remain within this ideal constraint level.<sup>5</sup> This is why, rectal spacers generating an ideal 10 mm separation were developed, ensuring better rectal dose sparing.<sup>14</sup>

In salvage brachytherapy after prior EBRT, use of rectal spacers would potentially allow full dose treatments.

Use of other modalities such as cryotherapy, HIFU (high intensity focused ultrasound) etc. requires further investigation.<sup>13</sup> Synthetic spacers such as polyethylene glycol (PEG) or hyaluronic acid (HA) have been developed, with considerable reduction of rectum exposure.<sup>14, 6</sup> Prada *et al.* reported mean rectal dose reduction from 608 to 442 cGy during HDR and LDR brachytherapy, after generating a 20 mm separation by injecting 6 (3 - 7) ml of HA.<sup>7</sup> Strom evaluated use of PEG in 100 patients undergoing HDR brachytherapy with or without IMRT<sup>8</sup> creating  $12 \pm 4$  mm separation using 10 ml of PEG and reducing D2 cc from  $60 \pm 8\%$  to  $47 \pm 9\%$  ( $p < 0.001$ ). Heikilä used 10 ml of PEG decreasing rectal dose from  $64 \pm 13$  Gy to 31 Gy ( $95 \pm 13$ ) ( $p < 0.005$ ). Separation duration was reported to be 110 days.<sup>14</sup> Increasing the distance not only decreased risk of rectal side effects but also allowed greater dose delivery to the prostate. This is important for hypofractionated EBRT planning.



**Figure 4:** CT Scan at 1st and 3rd month in two cases of salvage brachytherapy.

Coleman<sup>11</sup> described the lipo-transfer technique for damaged tissue repair, as a simple way to generate a filling effect and replace tissue loss. The procedure is based on the presence of stem cells in the transferred fat. In fact, adipose tissue has the highest concentration of stem cells, greater than any other body tissue (5000 cells/ml vs. 100 - 1000 cells / ml in bone marrow).<sup>15</sup> Successful use of fat transfer techniques have been described in plastic and reconstructive surgery, on vocal chords, for post - actinic dermatitis, etc. generating a change in the lipo - transfer paradigm.<sup>11</sup>

The technique does not offer significant challenges for trained brachytherapy experts. And provides the advantage that no changes need to be made to treatment planning since the adipose transfer is conducted once radiotherapy has been completed. Another important advantage is the low cost of the procedure, which only requires commercially-available plastic surgery needles. Perhaps the biggest challenge remains generating a homogenous distance between the prostate and the rectum, particularly because injected fat will tend to shift away from the midline. To avoid this, it is important not to apply too much pressure on the transrectal transducer, which would push fat delivery away from the midline. It is also convenient to introduce the midline graft first and only then inject into the sides, while controlling transducer positioning along both planes. Another potential source of difficulty arises from manual needle introduction since which may fail to coincide with grid holes. This series includes our "learning curve", which is why in some cases, less distance was achieved, especially at the prostate apex level. We included primary and rescue cases since our main objective was to evaluate technique feasibility as well as radiotherapy influence on fat tissue viability, a result not yet reported in the literature. In this series, reduced apex separation corresponded to early cases, probably due to poor technique or excessive pressure on the transrectal transducer, which pushed injected fat away from the midline, to lateral areas of less resistance.

It remains to be established whether transferred fat remains in situ with time, and whether it is modified or not by radiotherapy exposure. Adipose stem cells are known to generate new vessel formation after 48 hours. This neovascularization allows adipocyte and pre-adipocyte survival,<sup>16</sup> although not all transferred fat tissue remains stable, and some will undergo transformation to connective tissue. Histology examination of transferred fat has always been from non-irradiated tissue samples.<sup>17</sup> We plan to conduct biopsies between 6 and 12 months of follow-up to establish transferred tissue condition after brachytherapy. If prostate-rectum distance equal to or greater than 10mm is maintained at 6 months, this should be sufficient to guarantee very low adverse clinical event rates, considering Iodine - 125 half - life is 59.4 days.

## 5. Conclusion

Autologous fat transfer is a simple procedure for experienced practitioners with low complication rates, allowing radiation dose escalation. Mean separation generated by our group after three months was: 9.6 mm (1.9 - 14.6 mm), 6.3mm (1.8 - 10.2 mm) and 5.4 mm (3.8 - 7.2 mm) at prostate base, middle and apex, respectively with minimal complications. These are encouraging results although larger case series, with rectal volume dosimetry, as well as longer follow - up will be needed to establish the true value of this procedure during radiotherapy for primary or salvage prostate cancer treatment.

## Conflict of interest

The authors declare that they have no conflicts of interest. The authors alone are responsible for the content and writing of the paper.

## References

1. Zelefsky MJ, Reuter EV, Fuca Z, *et al.* Influence of Local Tumor Control on distant metastasis and cancer-related mortality after external beam radiotherapy for prostate cancer. *J Urol.* 2008;179(4):1368-73.
2. Zietman AL, Bae K, Slater JD, *et al.* Randomized trial comparing conventional-dose with high-dose conformal radiation therapy in early-stage adenocarcinoma of the prostate: Long-term results from proton radiation oncology group/American college of radiology 95-09. *J Clin Oncol.* 2010 Mar 1;28(7):1106-11.
3. Kinsella TJ, Bloomer WD. Tolerance of the intestine to radiation therapy. *Surg Gynecol Obstet.* 1980 Aug;151(2):273-84.
4. Moore E, Magrino T, Johnstone P. Rectal bleeding after radiation therapy for prostate cancer: endoscopic evaluation. *Radiology.* 2000 Oct;217(1):215-8.
5. Cho KH, Chung KKL, Levitt SH. Proctitis after conventional external radiation therapy for prostate cancer: importance of minimizing posterior rectal dose. *Radiology.* 1995 Jun;195(3):699-703.
6. Hatiboglu G, Pinkawa M, Vallee PJ, *et al.* Application technique: Placement of a prostate-rectum spacer in men undergoing prostate radiation therapy. *BJU Int.* 2012;110(11b):E647-E652.
7. Prada PJ, Fernández J, Martínez AA, *et al.* Transperineal injection of hyaluronic acid in anterior perirectal fat to decrease rectal toxicity from radiation delivered with intensity modulated brachytherapy or EBRT for prostate cancer patients. *Int J Radiat Oncol Phys.* 2007;69(1):95-102.
8. Chapet O, Udrescu C, Devonec M, *et al.* Prostate hypofractionated radiation therapy: Injection of hyaluronic acid to better preserve the rectal wall. *Int J Radiat Oncol Phys.* 2013;86(1):72-6.
9. Heikkilä VP, Kärnä A, Vaarala MH. DuraSeal as a spacer to reduce rectal doses in low-dose-rate brachytherapy for prostate cancer. *Radiotherapy and Oncology.* 2014;112(2):233-6.
10. Davis BJ1, Horwitz EM, Lee WR, *et al.* American brachytherapy society consensus guidelines for transrectal ultrasound-guided permanent prostate brachytherapy. *Brachytherapy.* 2012;11(1):6-19.
11. Coleman S. Hand Rejuvenation with structural fat grafting. *Plast. Reconstr. Surg.* 2002;110(7):1731-44.
12. Ammar H, Eldebawy E, Maarouf E, *et al.* Evaluation of the peripheral dose and the conformity index for three stereo-tactic radiotherapy techniques: Arcs, noncoplanar fixed fields and intensity modulation. *Int J Cancer Ther Oncol.* 2014;2(4):02042.
13. Alongi F, De Bari B, Campostrini F, *et al.* Salvage therapy of intraprostatic failure after radical external beam radiotherapy for prostate cancer: a Review. *Critical Review in Oncol Hemat.* 2013;88(3):550-63.
14. Strom TJ, Wilder RB, Fernandez DC, *et al.* A dosimetry study of polyethylene glycol hydrogel in 200 Prostate cancer patients treated with high dose rate brachytherapy+intensity modulated radiation therapy. *Radiotherapy and Oncology.* 2014 Apr;111(1):126-31.
15. Moscona R, Shoshani O, Lichtig H, *et al.* Viability of adipose tissue injected and treated by different methods: an experimental study in the rat. *Ann Plast Surg.* 1994;33(5):500-06.
16. Shiffman M, Mirafati S. Fat transfer techniques: the effect of harvest and transfer methods in adipocyte viability and review of the literature. *Dermatol Surg.* 2001 Sep;27(9):819-26.
17. Strem BM, Hicok KC, Zhu M, *et al.* Multipotential differentiation of adipose tissue-derived stem cells. *Keio J Med.* 2005 Sep;54(3):132-41.