

Multiple adenomatoid tumours in the Epididymis and Tunica vaginalis: Case report

Ahmed Abroaf¹, Rajan Veeratterapillay¹, Nikhil Vasdev¹, Joaquim Majo²,
Amira El-Sherif², Edgar Paez¹

¹Department of Urology Department, Freeman Hospital, Newcastle Upon Tyne, UK.

²Department of Pathology, Royal Victoria Infirmary, Newcastle Upon Tyne, UK.

Received December 19, 2013; Revised February 10, 2014; Accepted March 08, 2014; Published Online March 25, 2014

Case report

Abstract

We describe the case of a 65 year-old male presenting with a tender right testicular mass, confirmed to be a tumour on ultrasound. The patient underwent a radical inguinal orchidectomy and histology revealed multiple adenomatoid tumours in epididymis and tunica vaginalis. This is an infrequent benign tumour of mesothelial origin that has rarely been reported as multiple lesions in the literature. Immunohistochemistry demonstrates that adenomatoid tumour and mesotheliomas share the expression of podoplanin (D2-40) which is helpful to differentiate them from carcinomas. On the other hand adenomatoid tumour is differentiated from mesothelioma on morphological grounds since the former does not exhibit cellular atypia, mitotic activity or bland focal tumour necrosis. Although testis preserving surgery can be an option for benign adenomatoid tumours, most patients (as in our case) proceed to orchidectomy as diagnosing them confidently can be difficult.

Keywords: Tumour; Adenomatoid; Tunica; Epididymis

Introduction

Testicular tumours whether benign or malignant, have to be diagnosed accurately and treated promptly. Adenomatoid tumours are infrequent in the male genital tract. We describe the case of a patient who was diagnosed with testicular tumour on ultrasound. The patient then went on to have an inguinal orchidectomy and the histology revealed multiple adenomatoid tumours in epididymis and tunica vaginalis.

Case report

We report a case on a 65 year old male who presented with a one year history of right testicular swelling which had been getting increasingly painful. Past medical history included a previous deep vein thrombosis in the leg for which he was on warfarin. There was no history of cryptorchidism, trauma

or vasectomy. He also took allopurinol for gout but had no other co-morbidities or allergies. Clinical examination revealed a hard craggy mass in the upper pole of the right testis, and the contra-lateral testis felt normal.

Tumour markers including alpha-feto-protein, HCG and LDH were normal as well as his full blood count and renal function. The Ultrasound performed showed an echogenic mass measuring 32 × 24 × 29 mm situated at the upper pole of the right testis between the testis and the epididymal head consistent with a tumour. The left testis appeared normal. The patient underwent an uncomplicated right radical inguinal orchidectomy.

Pathology of the excised specimen showed an epididymal well circumscribed tumour measuring 30x22mm along with multiple nodules in the parietal tunica vaginalis up to two millimetres (**Figure 1**). Microscopic examination of the main lesion showed a tumour with dense areas of collagenous fibrosis admixed with bundles of smooth muscle in the centre, while at the periphery there are nests, cords and dilated tubular structures composed of epithelioid, flattened and vacuolated cells (**Figure 2A**). The same cells were noted lining the surface of the tumour and foci of squamous differentiation

Corresponding author: Ahmed Abroaf; Department of Urology Department, Freeman Hospital, Newcastle Upon Tyne, United Kingdom. Email: abroaf@gmail.com

Cite this article as:

Abroaf A, Veeratterapillay R, Vasdev N, Majo J, Sherif AE, Paez E. Multiple adenomatoid tumours in the Epididymis and Tunica vaginalis : Case Report. *Int J Cancer Ther Oncol* 2014; **2**(1):02021. DOI: [10.14319/ijcto.0202.1](https://doi.org/10.14319/ijcto.0202.1)

were noted in the inner part of the main tumour and in the smaller nodules (**Figure 2B**). No mitosis, cellular atypia or necrosis was noted. Immunohistochemistry demonstrated that these cells expressed pancytokeratin AE1/AE3 (**Figure 2C**), D2-40 (**Figure 2D**) and EMA, but they did not express calretinin, CEA, CD31, CD34, CD30, PLAP, Alfa-FP or HCG. The testicular parenchyma showed preserved architecture with unremarkable seminiferous tubules and there was no evidence of intra tubular germ cell neoplasia.

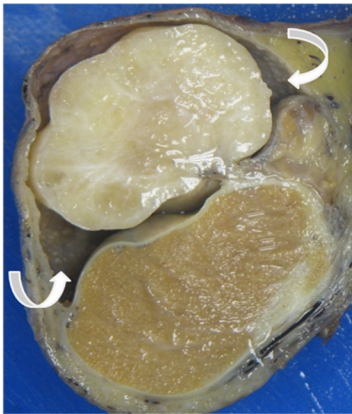


FIG.1: Cut surface of the specimen showing a 30 mm fibrous solid whitish tumour attached to the head the epididymis and multiple minute well defined nodules in the parietal tunica vaginalis (curved arrows).

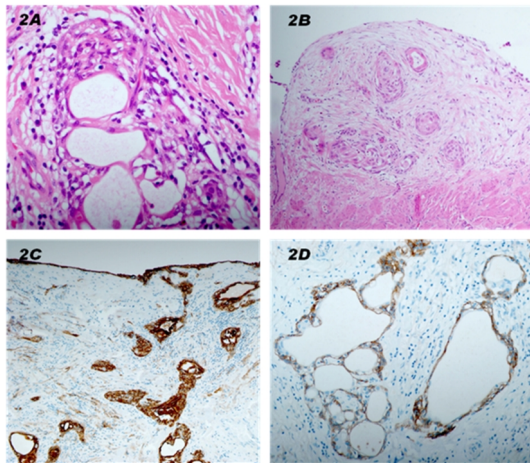


FIG. 2: Detail of the dilated tubular structures with epithelioid flattened and vacuolated cells, in a collagenous and inflamed stroma from the main tumour (H&E x200) (2A). Nodule from the parietal vaginalis lying on the muscle layer and showing focal squamous metaplasia in the epithelial nets (H&E x20) (2B) The cells lining the surface and the tubular structures expressing pancytokeratin AE1/AE3 (2C) and expression of D2-40 by the flattened lining cells of the tubules (2D).

Overall the appearances were those of multiple adenomatoid tumours in the epididymis and parietal tunica vaginalis. Local excision was considered complete. The patient made a good post-operative recovery and was well at the six months follow up.

Discussion

Adenomatoid tumours of the male genital tract are rare but most commonly involve the epididymis although involvement of the tunica albuginea, spermatic cord and ejaculatory ducts have been described.^{1,2} They often present as a hard painless mass and have been reported between the third and seventh decades.¹⁻³ Adenomatoid tumours are believed to be of mesothelial origin as supported by immunohistochemistry and ultrastructural studies.^{4,5}

Ultrasonography remains the imaging of choice for the initial investigation of testicular lesions. Whilst the presence of an intratesticular solid lesion is usually highly suspicious for malignancy, most extratesticular solid lesions including paratesticular lesions are benign. Nevertheless intraparenchymal and tunical tumours are difficult to differentiate from malignant tumours. Adenomatoid tumours are usually round and appear homogeneously echogenic.⁶

Adenomatoid tumours are usually small round/oval well circumscribed lesions less than 20mm, though according to the literature they range from 4mm to 50mm.⁷ Most of the cases are single tumours near or in the poles of the epididymis, though other locations include the body of epididymis, the tunica vaginalis, tunica albuginea, rete testis, parietal tunica and spermatic cord.⁸ The cut surface is usually firm and solid, though cystic spaces have been reported. Microscopically, the tumour is comprised of two major elements, epithelial-like cells and fibrous stroma. The epithelial-like cells are arranged in a network of tubules, cords, channels, and microcystic spaces. The fibrous stroma may be hyalinised and may contain smooth muscle. Mitotic figures are mostly absent.⁹

Adenomatoid tumour has a broad differential diagnosis that includes mesothelioma, hemangioma, vasitis nodosa, inflammatory pseudotumor, carcinoma of rete testis and metastatic carcinoma. Cytokeratins are expressed by carcinomas, vasitis nodosa and mesotheliomas in addition to the adenomatoid tumours, however only mesothelioma shares with adenomatoid tumour the expression of podoplanin (D2-40). D2-40 is as sensitive as calretinin for cells of mesothelial origin¹⁰, therefore very useful in the differential diagnosis with carcinomas. Adenomatoid tumour is differentiated from mesothelioma on morphological grounds, since the former does not exhibit cellular atypia, mitotic activity or bland focal tumor necrosis.

Conclusion

Multiple adenomatoid tumours as we describe have rarely been reported.¹¹ The current case shows a predominant lesion in the epididymis measuring 30mm in diameter, with multiple minute lesions up to 2mm in the parietal tunica vaginalis. Whether these minute lesions represent real tumours or a

rare form of adenomatoid hyperplasia, which has not yet been described, remains unclear.

Knowing that adenomatoid tumours are benign lesions some authors have suggested testis-preserving surgery. The difficulty is that it is often difficult to diagnose adenomatoid tumours confidently preoperatively and the majority of patients proceed to orchidectomy as in our case. The prognosis remains however excellent for this benign lesion.

Conflict of interest

The authors declare that they have no conflicts of interest. The authors alone are responsible for the content and writing of the paper.

References

1. Horstman WG, Sands JP, Hooper DG. Adenomatoid tumor of testicle. *Urology* 1992; **40**: 359-61.
2. Tammela TL, Karttunen TJ, Makarainen HF, Hellstrom PA, Mattila SI, Kontturi MJ. Intrascrotal adenomatoid tumors. *J Urol* 1991; **146**: 61-5.
3. Samad AA, Pereiro B, Badiola A, Gallego C, Zungri E. Adenomatoid tumor of intratesticular localization. *Eur Urol* 1996; **30**: 127-8.
4. Marcus JB, Lynn JA. Ultrastructural comparison of an adenomatoid tumor, lymphangioma, hemangioma, and mesothelioma. *Cancer* 1970; **25**:171-5.
5. Delahunt B, Eble JN, King D, Bethwaite PB, Nacey JN, Thornton A. Immunohistochemical evidence for mesothelial origin of paratesticular adenomatoid tumour. *Histopathology* 2000; **36**: 109-15.
6. Park SB, Lee WC, Kim JK *et al*. Imaging features of benign solid testicular and paratesticular lesions. *Eur Radiol* 2011; **21**: 2226-34.
7. Perez-Ordóñez B, Srigley JR. Mesothelial lesions of the paratesticular region. *Semin Diagn Pathol* 2000; **17**:294-306.
8. Mostofi FK, Price EB. Tumors of the Male Genital System. 2nd Edition. 1973; AFIP: Washington, DC
9. Manson AL. Adenomatoid tumor of testicular tunica albuginea mimicking testicular carcinoma. *J Urol* 1988; **139**:819-20.
10. Chu AY, Litzky LA, Pasha TL, Acs G, Zhang PJ. Utility of D2-40, a novel mesothelial marker, in the diagnosis of malignant mesothelioma. *Mod Pathol* 2005; **18**:105-10.
11. Di Pierro GB, Sciarra A, Innocenzi M, Cristini C. Rare case of multiple adenomatoid tumors arising from tunica vaginalis of testis and epididymis. *Actas Urol Esp* 2010; **34**:560-1.