



Long term survival after brain metastases from malignant melanoma

Carmen Salvador-Coloma¹, Joaquín Montalar¹, Óscar Mauricio Niño¹,
Alejandro Tormo², Jorge Aparicio¹

¹Medical Oncology Department, University Hospital La Fe, Valencia, Spain

²Radiotherapy Department, University Hospital La Fe, Valencia, Spain

Received August 25, 2016; Revised December 13, 2016; Accepted December 20, 2016; Published Online December 28, 2016

Case Report

Abstract

We present the case of a 32-year-old patient with malignant melanoma who relapsed with an unresectable brain metastases (BM). He was managed with whole brain radiotherapy (WBRT) and temozolomide chemotherapy. A metabolic positron emission tomography (PET-scan) complete response was achieved. He is living disease-free more than 6 years after the diagnosis of BM. He is now 51 years old and remains asymptomatic and free of disease since then. However, a pronounced residual image still appears on magnetic resonance imaging (MRI) and PET-scan.

Keywords: Malignant melanoma, Brain metastases, Long-term survival, Unresectable brain metastases

1. Introduction

Melanoma has a high propensity to metastasize the central nervous system (CNS). After breast and lung cancer, it is the third most common neoplasm causing brain metastases (BM).¹⁻² Some characteristics of melanoma are associated with an increased risk of systemic disease and therefore BM: origin in mucosal surfaces or skin of trunk, head and neck, male gender, ulcerated primary lesion, wide thickness invasion, acral lentiginous or nodular lesions, involvement of 3 or more regional lymph nodes, and visceral metastases at the time of diagnosis.¹

At 5 years, median survival for stage IV melanoma is 6-10 months, but for melanoma with BM is 2-9 months.² Long-term survival after BM is very unusual because of poor prognosis, regardless of cancer type. Nevertheless, survival is different depending on the primary neoplasm. Patients with ovarian tumors have the highest survival rate (7.8%), which is only 2.3% for patients with melanoma.³

We present the case of a patient with malignant melanoma who relapsed with an unresectable BM. He is living disease-free more than 6 years after the diagnosis of BM. He was managed with whole brain radiotherapy (WBRT) and temozolomide chemotherapy.

2. Case Presentation

A 32 year-old man, with medical history of hypertension, diabetes and dyslipidemia, was diagnosed with a cutaneous malignant melanoma (stage II-A), in his left shoulder in 1997. He underwent wide surgery and was rendered disease-free.

In 2001, a physical exam revealed axillary lymph node enlargement. He was treated with surgery, complementary radiotherapy (40 Gy) and adjuvant alpha 2b interferon therapy (20 MU/m²/day intravenously (i.v) 5 days a week for 4 weeks, then 10 MU/m² subcutaneously (s.c) three times per week for 48 weeks).

However, in 2002, in transit skin metastases were detected. He underwent salvage surgery plus adjuvant chemotherapy with 6 courses of dacarbazine (250 mg/m² × 5 days, every 4 weeks), that was well tolerated.

He was disease-free until 2010, when an unresectable BM relapse (5 cm in diameter, intraaxial with satellite lesions) was noticed in the right frontal lobe (Figure 1).

Corresponding author: Carmen Salvador-Coloma; Medical Oncology Department, University Hospital La Fe, Valencia, Spain.

Cite this article as: Salvador-Coloma C, Montalar J, Niño OM, Tormo A, Aparicio J. Long term survival after brain metastases from malignant melanoma. *Int J Cancer Ther Oncol.* 2016; 4(4):448. DOI: [10.14319/ijcto.44.8](https://doi.org/10.14319/ijcto.44.8)

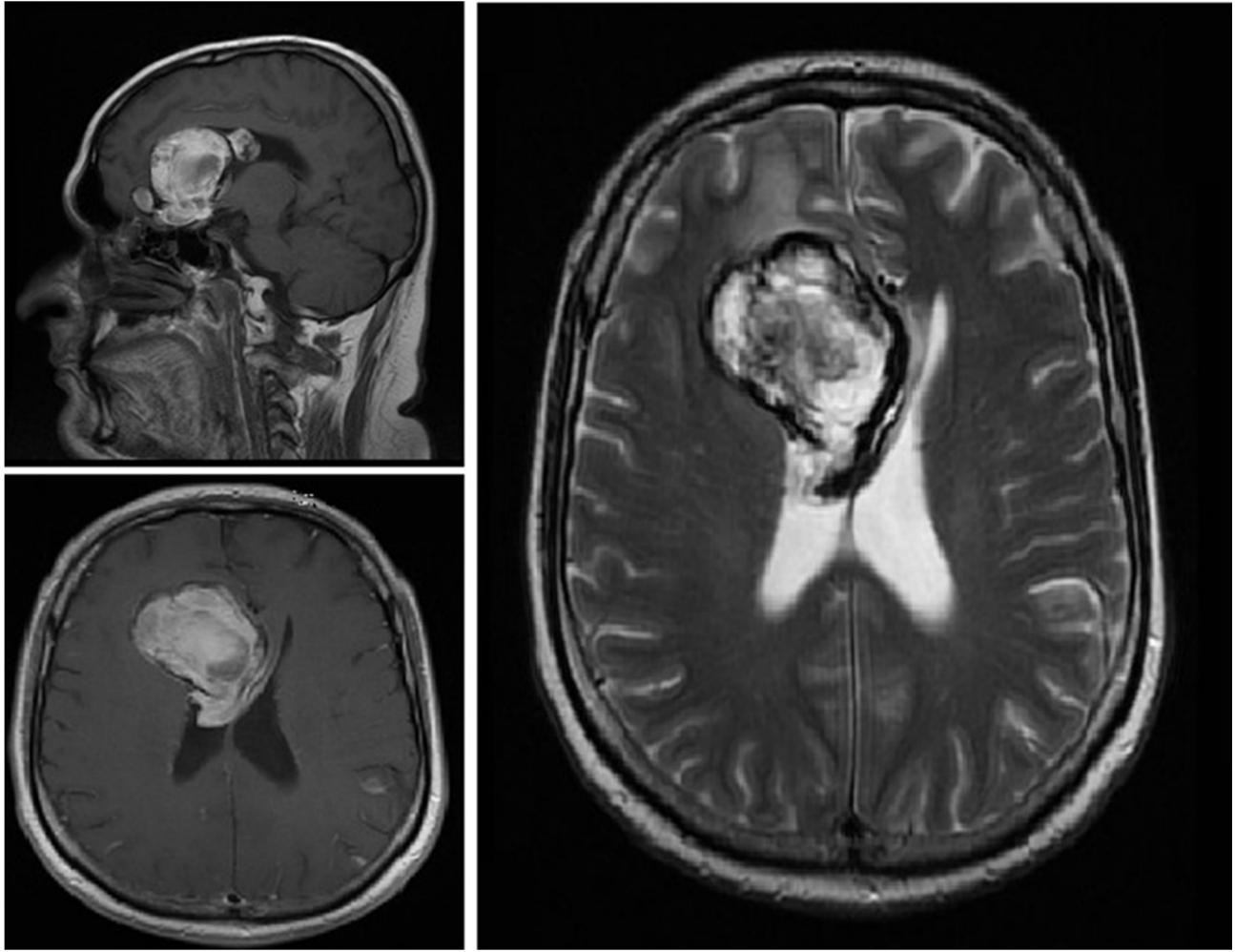


Figure 1: Magnetic resonance: Melanoma metastatic lesion at diagnosis (2010).

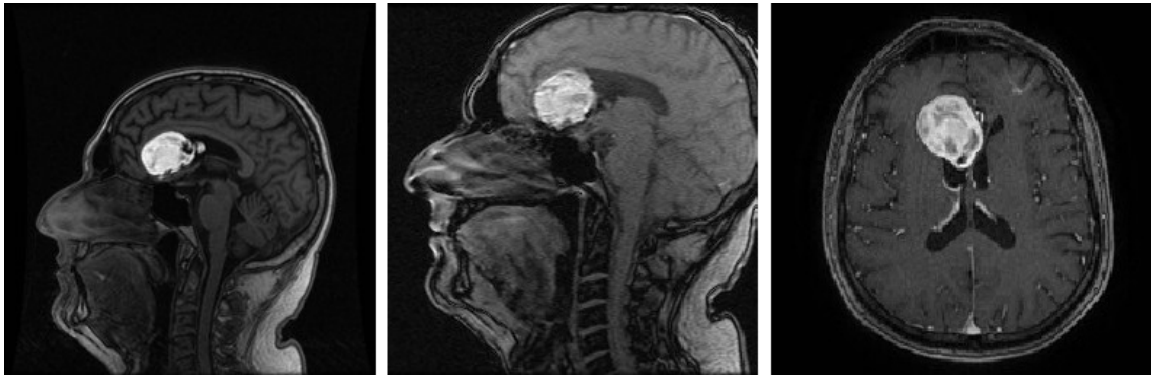

Figure 2: Magnetic resonance: Post-treatment residual hemorrhagic injury (2016).

The lesion was not studied by biopsy. He received concomitant chemo-radiotherapy (temozolamide 75 mg/m² continuous during WBRT to a total dose of 30 Gy). After concomitant treatment, he received eighteen cycles of temozolamide (200 mg/m² days 1-5 of 28 days). The clinical tolerance was acceptable, presenting only grade 2-3 emesis, which was controlled with standard antiemetic therapy.

A metabolic positron emission tomography (PET-scan) complete response was achieved. He is now 51 years old and remains asymptomatic and free of disease since then. However, a pronounced residual image still appears on magnetic resonance imaging (MRI) and PET-scan (Figures 2 and 3).

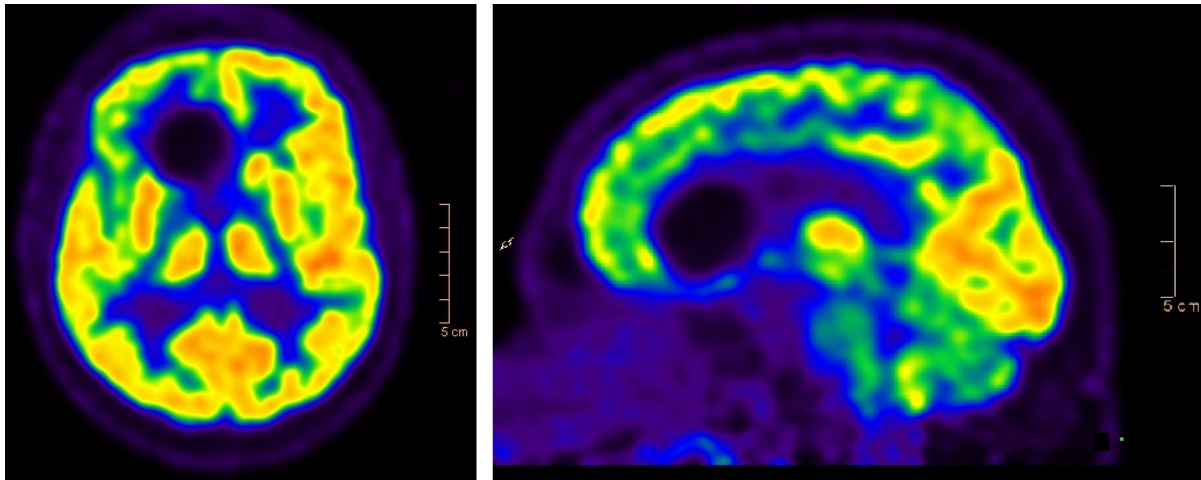


Figure 3: PET-scan: complete response.

3. Discussion

Malignant melanomas tend to metastasize into the CNS.⁴ This specific dissemination has a negative effect on overall survival and in most cases represents a terminal event.⁵ Patients with large (>4 cm), or numerous lesions are difficult to treat and usually receive palliative therapies. In contrast, smaller (<2 cm) and single lesions can be treated more effectively.⁶ For patients with BM, some studies have shown favorable prognostic variables for extended survival: younger age, the presence of a single lesion, surgical resection, chemotherapy and WBRT.³

The treatment of choice for oligometastatic CNS disease is surgical resection. It depends on the number of lesions, the size and locations of the tumor, the state of systemic disease and performance status.⁷ In this group of patients surgery has been shown to improve survival.⁸ In 60-70% of patients, WBRT has shown a survival improvement of 1-2 months and is effective in palliating symptoms of BM.⁹ A series from the Sydney Melanoma Unit report outcome of 646 melanoma patients treated for BM. Median survival was 8.7 months for surgery versus 8.9 months for surgery and postoperative WBRT and 3.4 months for patients treated solely with WBRT.¹⁰ Stereotactic radiosurgery can treat smaller metastatic lesions. The benefit is that it allows for treatment lesions that would otherwise be inoperable.¹¹⁻¹² A variety of cytotoxic drugs has been tested for the treatment of BM of melanoma, including temozolamide. Most of the studies have shown better results for combination therapies as compared to WBRT alone.¹³⁻¹⁴

For solitary BM, the recommended treatment is surgical removal of the lesion followed by WBRT or WBRT with stereotactic radiosurgery. The case reported here underwent concomitant chemotherapy and radiotherapy followed by adjuvant chemotherapy. Stereotactic radiosurgery or surgery was not administered due to

the lesion extension and its location. Historically, BM were treated with WBRT followed by stereotactic radiosurgery. In recent years, however, it is suggested that stereotactic radiosurgery of smaller lesions provides long-term control as exclusively treatment, and that many patients did not appear to require additional treatment.¹⁵ There are some clinical trials including patients with one to three BM from different kind of cancers that have shown local control with stereotactic radiosurgery is not improved by WBRT, but the development of new BM is decreased by the addition of WBRT.^{12,16,17}

4. Conclusion

Systemic treatment has not been shown to be effective in melanoma BM, therefore it has uncommonly been used as primary treatment.¹⁸ Nowadays, the development of new therapeutic agents point out an important improvement in management options for these patients.¹⁹ The present case suggests that treatment of melanoma BM remains an ongoing challenge, and advances in treatment are providing benefit for patients. Nevertheless, we must continue investigating ways to develop an optimal treatment for these patients.

Conflict of interest

The authors have no actual, potential, real or apparent interest to declare and have no involvement that might raise the question of bias in the work reported or in the conclusions, implications, or opinions stated.

References

1. Ballo MT, Ross MI, Cormier JN, *et al*. Combined-modality therapy for patients with regional nodal metastases from melanoma. *Int J Radiat Oncol Biol Phys*. 2006;64:106-13.

2. Mahmood H, Faheem M, Asghar Hussain Asghar AH, *et al.* Long-Term Survivor of Brain Metastases from Malignant Melanoma. *J Coll Physicians Surg Pak.* 2010;20(12):832-4.
3. Hall WA, Djalilian HR, Nussbaum ES, *et al.* Long-term survival with metastatic cancer to the brain. *Med Oncol.* 2000;17(4):279-86.
4. Kotb S, Detappe A, Lux F, *et al.* Gadolinium-Based Nanoparticles and Radiation Therapy for Multiple Brain Melanoma Metastases: Proof of Concept before Phase I Trial. *Theranostics.* 2016;6(3):418-27.
5. Shapiro DG and Samlowski W. Management of melanoma brain metastases in the era of targeted therapy. *J Skin Cancer.* 2011;2011:845863.
6. Schellinger PD, Meinck HM, Thron A. Diagnostic accuracy of MRI compared to CCT in patients with brain metastases. *J Neurooncol.* 1999;44(3):275-81.
7. Maher E, McKee A. Neoplasms of the central nervous system, in Atlas of Diagnostic Oncology. 3rd ed. Elsevier Science, London, UK, 2003.
8. Lee JY, Lunsford LD, Subach BR, *et al.* Brain surgery with image guidance: current recommendations based on a 20-year assessment. *Stereotact Funct Neurosurg.* 2000;75(1):35-48.
9. Solan MJ, Brady LW. Skin cancer. Principles and practice of radiation oncology. Philadelphia: Lippincott Williams & Wilkins; 2008.
10. Fife KM, Colman MH, Stevens GN, *et al.* Determinants of outcome in melanoma patients with cerebral metastases. *J Clin Oncol.* 2004;22:1293-300.
11. Bhatnagar A, Flickinger J, Kondziolka D, Lunsford L. Stereotactic radiosurgery for four or more intracranial metastases. *Int J Radiat Oncol Biol Phys.* 2006;64(3):898-903.
12. Manon R, O'Neill A, Knisely J, *et al.* Phase II trial of radiosurgery for one to three newly diagnosed brain metastases from renal cell carcinoma, melanoma, and sarcoma: an eastern cooperative oncology group study (E 6397). *J Clin Oncol.* 2005;23(34):8870-6.
13. Meier S, Baumert BG, Maier T, *et al.* Survival and prognostic factors in patients with brain metastases from malignant melanoma. *Onkologie* 2004;27:145-9.
14. Chiarion-Sileni V, Murr R, Pigozzo J, *et al.* Brain metastases from malignant melanoma. *Forum (Genova).* 2003;13(2):170-82.
15. Rao G, Klimo P, Thompson C, *et al.* Stereotactic radiosurgery as therapy for melanoma, renal carcinoma, and sarcoma brain metastases: impact of added surgical resection and whole-brain radiotherapy. *Int J Radiat Oncol Biol Phys.* 2006;66(4):S20-5.
16. Kocher M, Soffietti R, Abacioglu U, *et al.* Adjuvant wholebrain radiotherapy versus observation after radiosurgery or surgical resection of one to three cerebral metastases: results of the EORTC 22952-26001 study. *J Clin Oncol.* 2011;29(2):134-41.
17. Aoyama H, Shirato H, Tago M, *et al.* Stereotactic radiosurgery plus whole-brain radiation therapy vs stereotactic radiosurgery alone for treatment of brain metastases: a randomized controlled trial. *JAMA.* 2006; 295(21):2483-91.
18. Agarwala S, Kirkwood J, Gore M, *et al.* Temozolomide for the treatment of brain metastases associated with metastatic melanoma: a phase II study. *J Clin Oncol.* 2004;22(11):2101-7.
19. Goldinger SM, Panje C, Nathan P. Treatment of melanoma brain metastases. *Curr Opin Oncol.* 2016;28(2):159-65.