

1-19-2016

Clues from the kidneys: Case report on end-stage pulmonary fibrosis

Abrill Jones

West Kendall Baptist Hospital, abrillj@baptisthealth.net

Follow this and additional works at: <https://scholarlycommons.baptisthealth.net/se-all-publications>



Part of the [Medicine and Health Sciences Commons](#)

Citation

Jones, Abrill, "Clues from the kidneys: Case report on end-stage pulmonary fibrosis" (2016). *All Publications*. 2625.
<https://scholarlycommons.baptisthealth.net/se-all-publications/2625>

This Conference Poster -- Open Access is brought to you for free and open access by Scholarly Commons @ Baptist Health South Florida. It has been accepted for inclusion in All Publications by an authorized administrator of Scholarly Commons @ Baptist Health South Florida. For more information, please contact Carrief@baptisthealth.net.

Clues from the kidneys: Case report on end-stage pulmonary fibrosis

Abrill Jones, M.D.

Patient Information

A 49-year old Hispanic male with a 9-year history of pulmonary fibrosis of unknown etiology (now end-stage and referred for lung transplant) is advised to go to the emergency department (ED) by his primary care physician for an elevated Creatinine of 8.9 and blood urea nitrogen (BUN) of 89 on out-patient testing. Upon presenting to the ED, laboratory testing reveals the patient's Cr to be 9.6 and BUN is 96.

When the patient was examined he was found to be cachectic in appearance with temporal wasting and atrophied extremities (but able to ambulate). He was tachycardic with a heart rate of 110 at rest and had an oxygen saturation of 92-93% on room air.

Timeline

9 years ago: CT scan shows scattered interstitial areas of abnormality peripherally in both lower lobes, lateral aspect of both middle lobes and also in both upper lobes consistent with interstitial lung fibrosis.

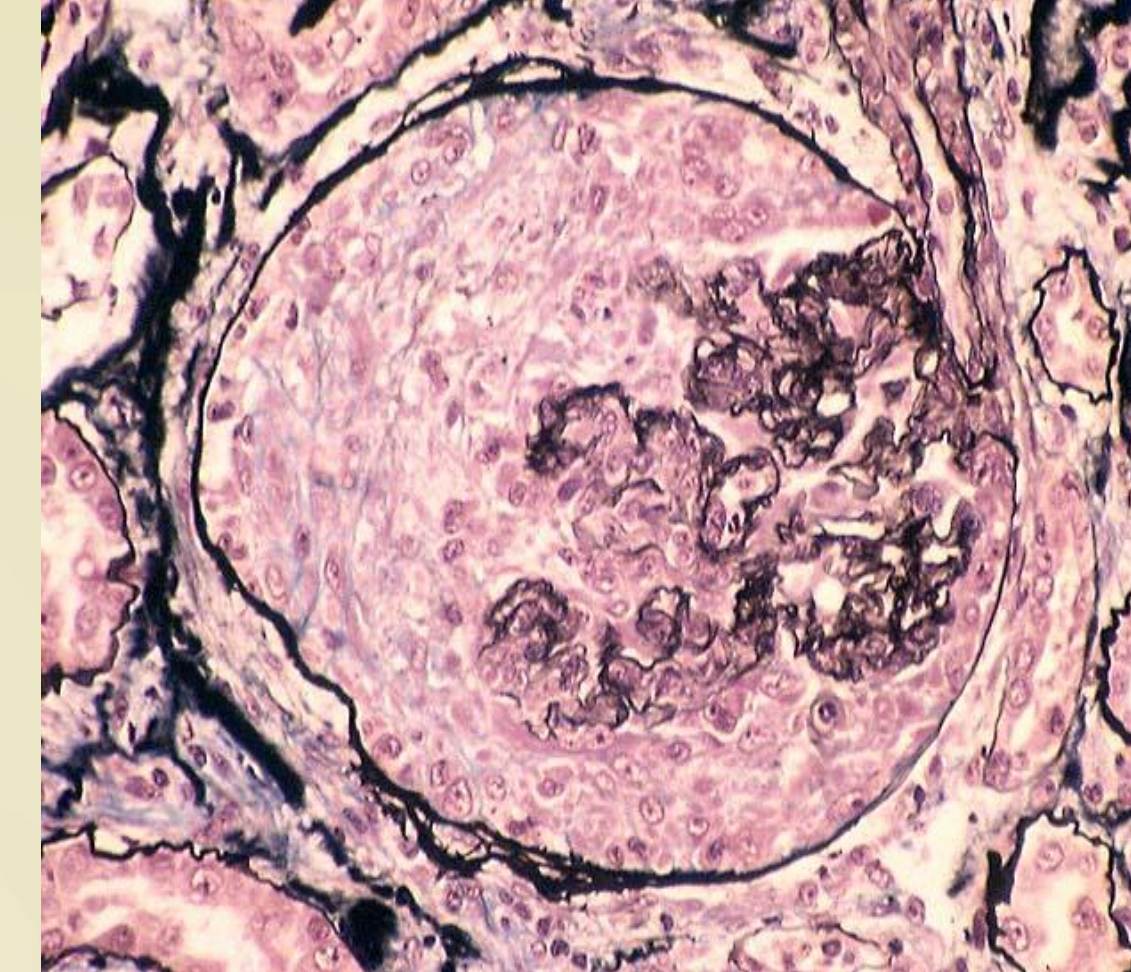
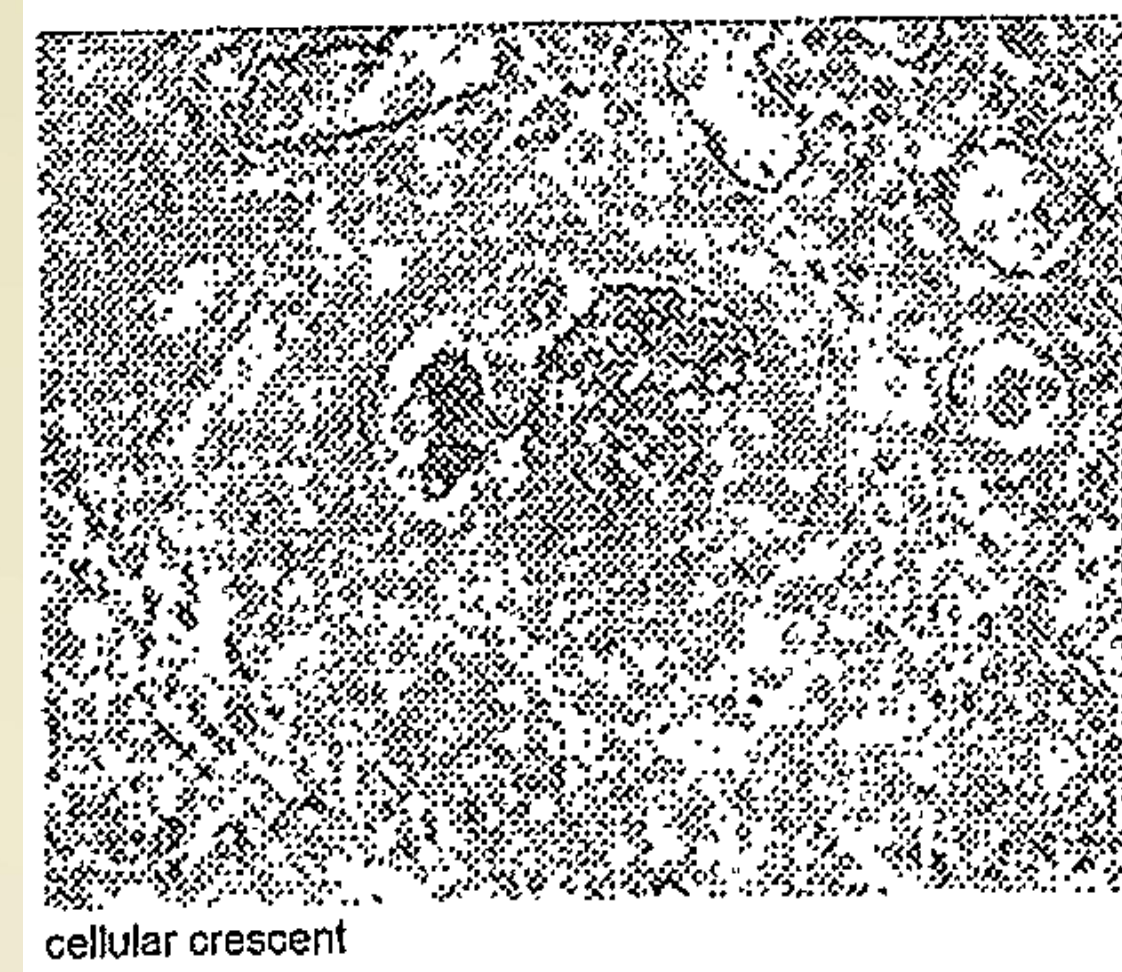
6 years ago: Patient visits his pulmonologist. His CT scan shows scattered peripheral subpleural reticular opacities and subpleural regions of honeycombing with mid-to-lung predominance with mild ground-glass attenuation at the bases. The patient decides to try a course of alternative medicine.

5 months prior to current admission: Pt is admitted with Acute on chronic hypoxic respiratory failure with worsening idiopathic pulmonary fibrosis (PaO₂ 55% on room air). No infectious cause found (Ziehl-Neelson stain negative for acid-fast organisms and QuantiFeron was within normal limits. Cultures are also negative). Patient is placed on home O₂ and referred for possible lung transplant.

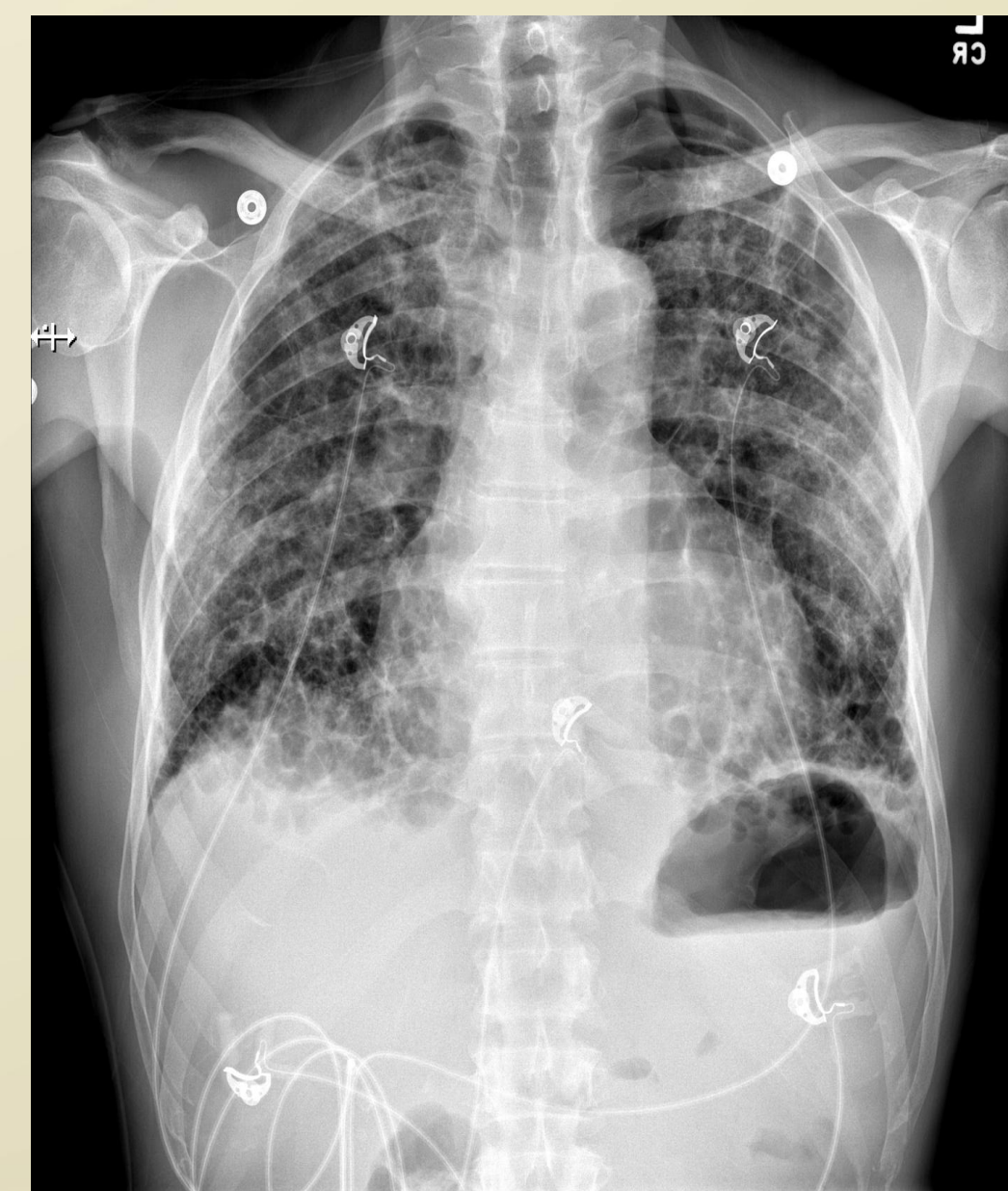
This admission: Pt admitted with Acute Renal Failure, anemia (likely secondary to renal failure, pulmonary fibrosis and weight loss).

Differential Diagnoses: Myeloma, Pulmonary fibrosis secondary to bird exposures, Alpha-1 antitrypsin deficiency, Hepatitis B & C, HIV

Diagnostic Assessment



Renal biopsy showing diffuse sclerosing, focal necrotizing, & crescentic glomerulonephritis, pauci-immune type, acute & chronic, severe (P-ANCA associated). Chronic & granulomatous interstitial inflammation, diffuse & severe. Tubular atrophy & interstitial fibrosis, moderate to severe. Arteriosclerosis, moderate.



Posterior Anterior chest x-ray: Diffuse interstitial opacity and fibrotic changes consistent with pulmonary fibrosis.

Therapeutic Intervention

Solu-Medrol → Plasmaphoresis → Cyclophosphamide

Follow Up Care

- 2 more doses of cyclophosphamide administered.
- Placement of arteriovenous fistula for dialysis performed.
- MPO and P-ANCA continued to be negative through repeat testing.

Follow-up and Outcomes

Lab	Result on First Lab Draw	Result on discharge or follow-up
Hemoglobin (13.0-17.2)	8.4	13.3
Creatinine	9.60	3.70
Estimated Glomerular Filtration Rate	6	18
MPO Antibodies (0.0-0.9)*	40.2	<9.0 (~1 month later)
ANCA-Perinuclear (P-ANCA) (Neg:<1:20) titer	1:160	<1:20 (~1 month later)
BMI	15.78	17.81 (~1 month later)

* Myeloperoxidase * Proteinase 3

Discussion

The patient's diagnosis upon biopsy is revealed to be Granulomatosis with polyangiitis (GPA), previously known as Wegener's granulomatosis. An antineutrophil cytoplasmic antibodies (ANCA)-associated small-vessel vasculitides (AAV) that typically presents between the ages of 35-55 years old. In the United States it has a prevalence of 3 out of every 100,000 people. It is more common in those of northern European descent (around 90%), particularly males (male-to-female ratio of 1:1.5). The decision to perform a renal biopsy on this patient was secondary to the presentation of acute renal failure in the background of end-stage pulmonary fibrosis. The biopsy and diagnosis did not occur in time to save this patient from end-organ damage. The presentation of the pulmonary fibrosis so far in advance of the renal failure and without other features, such as sinus and/or oral cavity involvement. In future patients with interstitial lung disease without an identified potential cause, one could consider performing serology for specific connective tissue diseases and/or biopsy of skin, sinus/nasal septum, muscle or kidney.